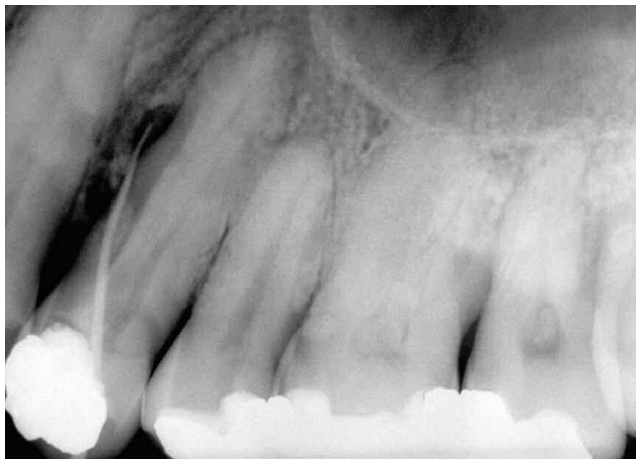

# RADIOGRAPHIC LESIONS OF ENDODONTIC ORIGIN: SIGNIFICANCE OF LOCATION

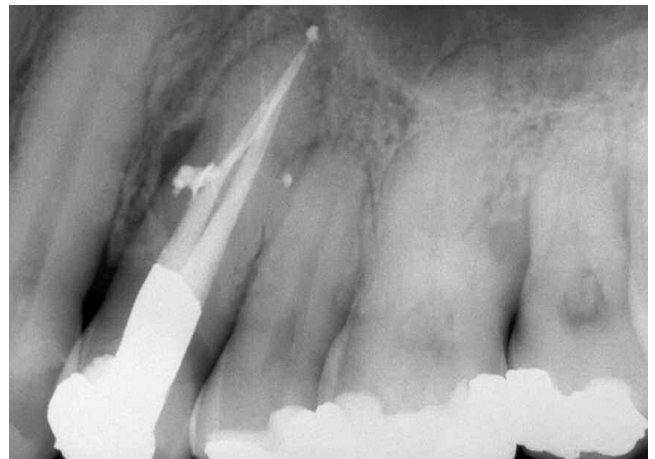by Clifford J. Ruddle, D.D.S.

Dental radiographic examination frequently depicts radiolucencies approximating root surfaces (*Figure 1*). Apical radiolucencies in particular tend to cast suspicion on pulpal health and are often associated with endodontically involved teeth. Certainly, thorough pulp testing schemes should be conducted to corroborate this radiographic suspicion, allowing the clinician to differentially diagnose the presence or absence of a *lesion of endodontic origin*.

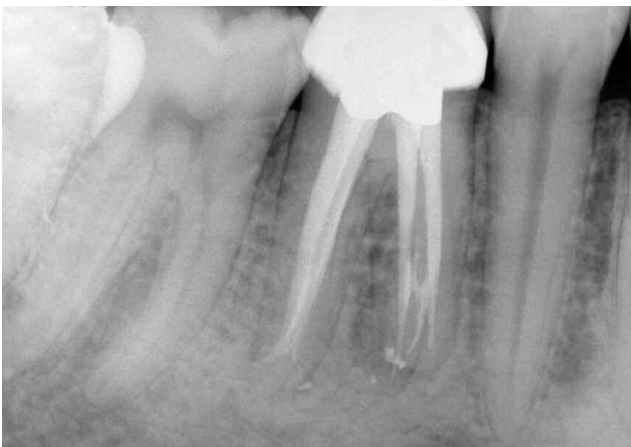

*Figure 1a.* Pre-op film of a maxillary first bicuspid. Note the large lateral root lesion and the presence of a traced fistula. Pulp testing confirms a lesion of endodontic origin.

Historically, our eagerness to look for only *apical* endodontic lesions is attributable to the conception of pulpal disease flow occurring within roots containing simple, uncomplicated canals exhibiting generally one apical portal of exit. This oversimplified anatomical model must **not** be perceived as correct (*Figure 2*).



*Figure 1b.* Three-year recall demonstrates excellent apical and lateral ossification. Note the shape and apical flow of the merging buccal and lingual systems containing several lateral canals and that surplus material has not impeded healing.



*Figure 2.* Post-op film of a mandibular first molar depicting a three-dimensionally packed root canal system. Note the anastomosing system in the mesial root and the multiple apical portals of exit. As is very often the case, the distal root contains two canal systems.

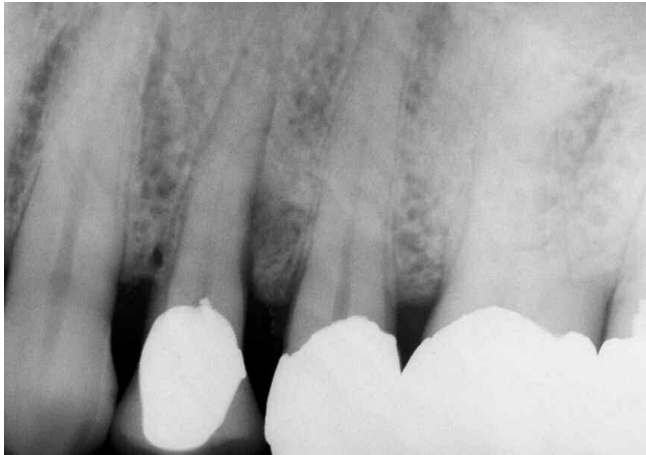To better understand the etiology of radiographic lesions of endodontic origin, it is fundamental to associate that these lesions arise secondarily to various pulpal degenerative states. Clinicians should be familiar with the clinical range of reversible and irreversible conditions exhibited by the dental pulp. These conditions can be determined by vital pulp testing methods, which will help identify the various progressive pathological states resulting from irreversible injury.

Diagnosticians should think of the pulp as dynamic tissue whose status at any given point in time can be assigned a position on a continuum that ranges from pulpal health to pulpal death. Following pulpal injury, a sequence chain of pathophysiological events occurs, starting with pulpal inflammation, but potentially proceeding to ischemia, infarction, necrosis and pulp death. This phenomenon originates in a root canal system whose anatomical complexities and high incidence of accessory ramifications is well-documented

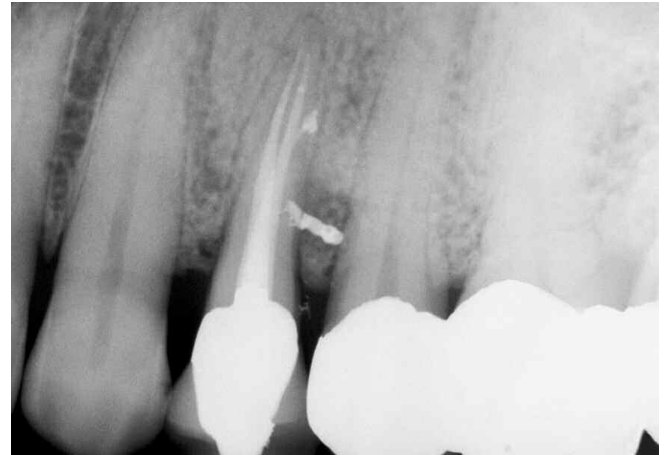
(*Figure 3*). Quite clearly, the destiny and ultimate fate of the dental pulp will be dependent upon the duration and extent of cellular injury caused by a number of etiologic agents.

The literature accurately describes the root canal system as a space whose internal anatomy varies infinitely from root to root. Along their coronal-to-apical length, root canal systems contain what investigators and clinicians have described as arborizations, anastomoses, cul-de-sacs, off-shoots, fins, loops, extra canals, accessory canals, lateral canals and auxiliary canals.

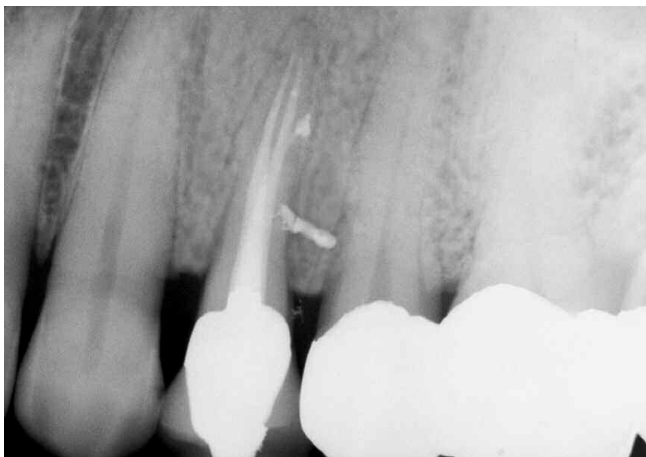Regardless of terminology, these various configurations commonly communicate with the attachment apparatus periradicularly. Consequently, any opening from the root canal system to the periodontal ligament space should be thought of as a portal of exit that potential endodontic breakdown products may pass through.



*Figure 3a. Pre-op film of a maxillary first bicuspid demonstrating a significant distal crestal lesion threatening the sulcus.*

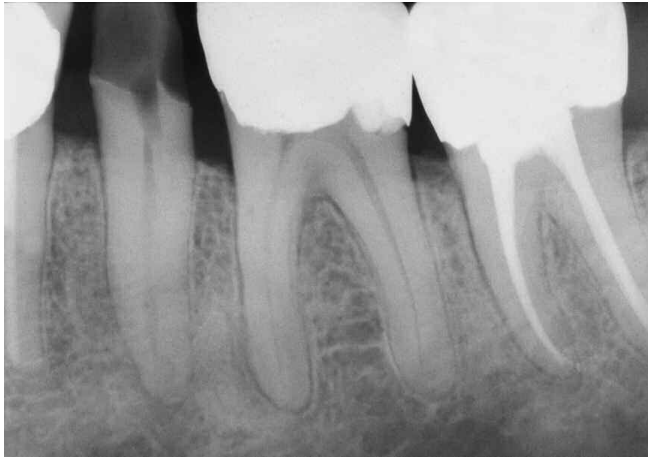

*Figure 3b. Post-op film revealing the dense compaction obtained by the Schilder Warm Gutta Percha technique. Note the five treated apical and lateral portals of exit.*

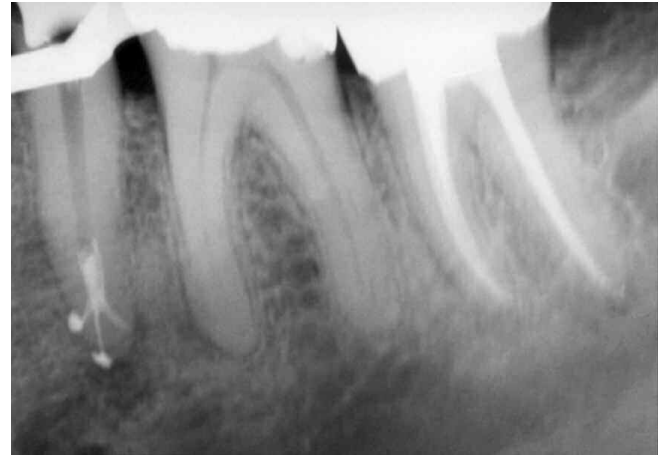

*Figure 3c. Six-month review demonstrates good progressive apical and lateral bone fill.*

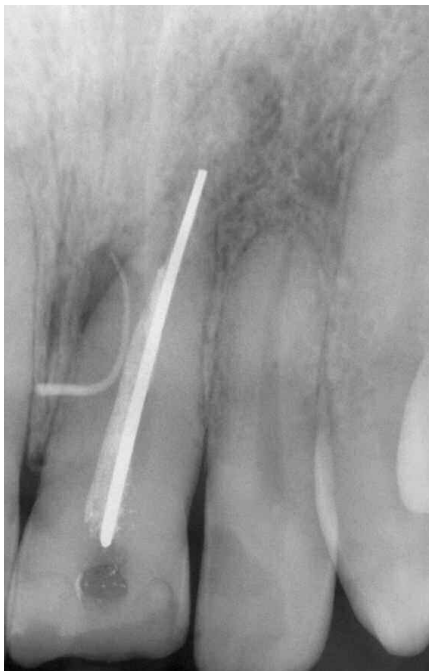Most lateral root and furcal portals of exit are not visible radiographically. However, well-angulated radiographs will frequently depict lesions of endodontic origin not only apically (*Figure 4*), but laterally (*Figure 5*), coronally (*Figure 6*), and in the bi- and tri-furcations of multi-rooted teeth (*Figures 7 and 8*). Many periodontal sulcular defects may be attributable to significant lateral canals disseminating irritants. The endodontic/periodontic differential diagnosis and proper sequence of treatment are paramount in resolving periodontal lesions of endodontic origin (*Figure 9*).



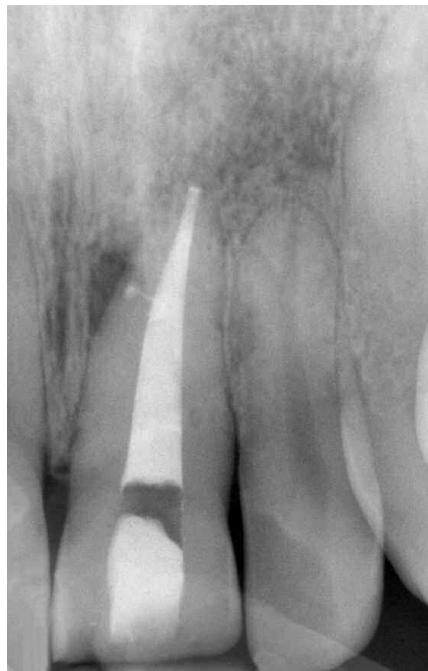*Figure 4a. Pre-op film of mandibular second bicuspid opened previously on an emergency basis to afford drainage. Note that the primary canal is hard to interpret apically but the position of the lesions gives insight into apical canal morphology.*



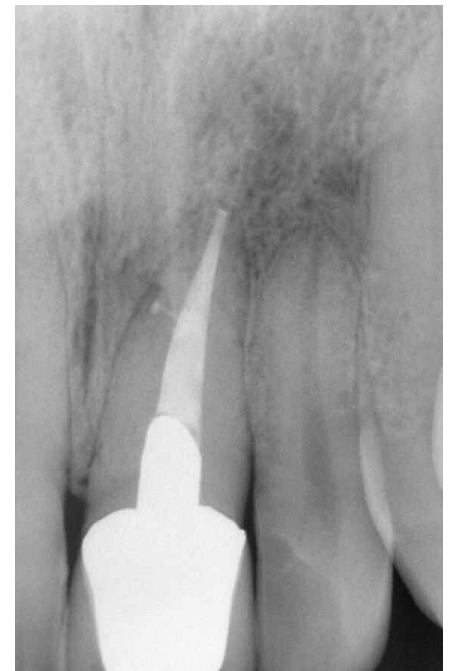*Figure 4b. Post-op film reveals "the pack" and depicts completed treatment of the primary system containing three apical portals of exit.*



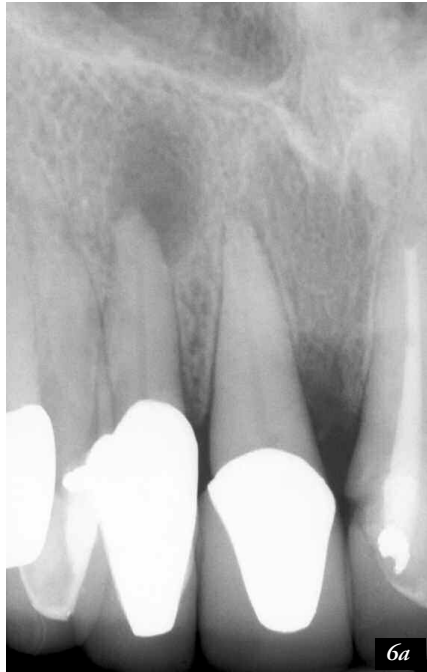*Figure 5a. Pre-op film of a maxillary central incisor previously treated endodontically with a combination gutta percha/silver point obturation technique. The traced fistulous tract points to a large lateral root lesion.*



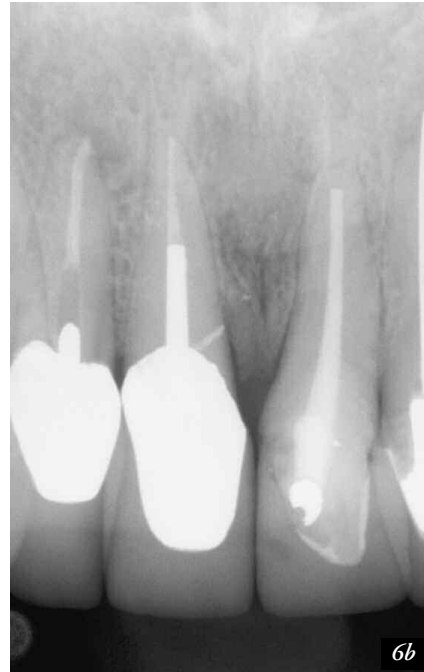*Figure 5b. Post-op film demonstrates dense three-dimensional obturation with the Schilder Warm Gutta Percha technique. Note treated lateral canal implicated in pre-op pathology.*



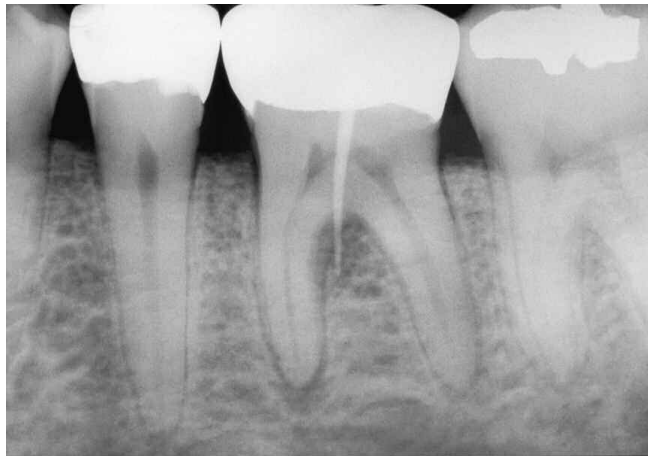*Figure 5c. Three-year review demonstrating the inevitable osseous repair following complete treatment.*



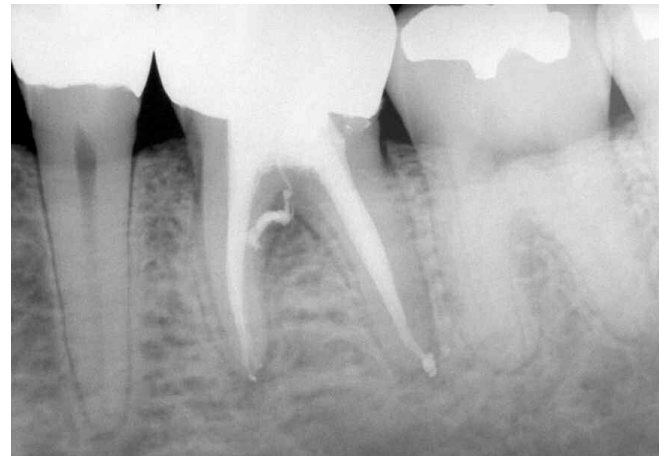*Figure 6a.* Pre-op film of a maxillary central and lateral incisor. A revelation in endodontic diagnosis occurs when the clinician observes not only the apical lesion of the lateral incisor, but also the midline crestal lesion of the central incisor. Both teeth tested pulpless with intact sulcuses.



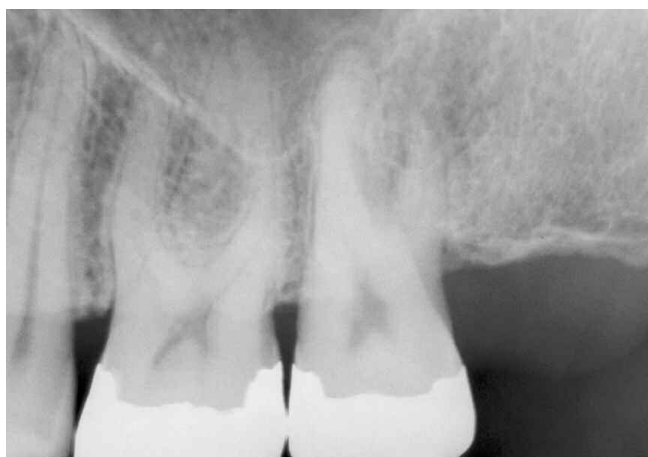*Figure 6b.* Six-month review demonstrating excellent progressive healing. As expected, three-dimensional cleaning, shaping and obturation of the root canal system allows for both apical and crestal ossification. (Note the failure to utilize the entire post-space).



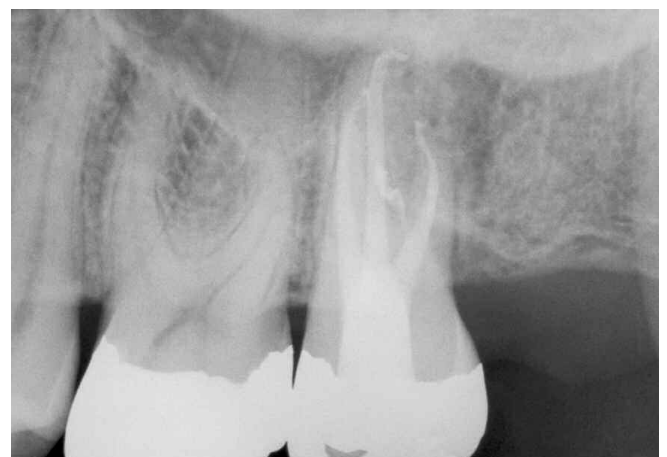*Figure 7a.* Pre-op film of mandibular first molar exhibiting a lesion of endodontic origin apically and furcally. An intersulcular fistula is traced with a gutta percha point.



*Figure 7b.* Post-op film demonstrates the periodontal importance of treating lesions of endodontic origin with appropriate therapy. The pulpal floor was packed with gutta percha/sealer, establishing a furcal environment conducive to tissue re-attachment and pocket elimination.



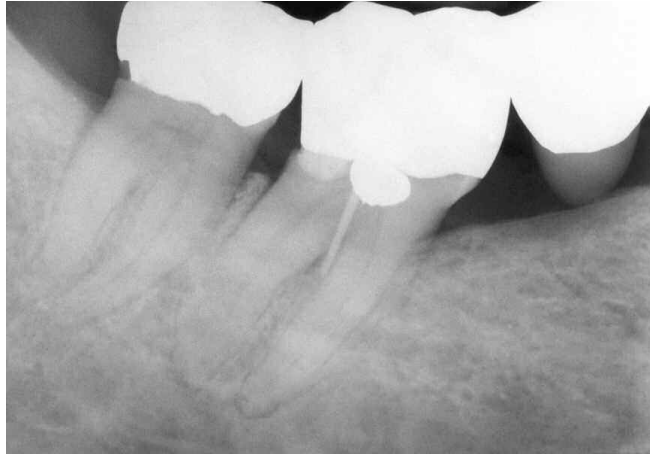*Figure 8a.* Pre-op film of a maxillary second molar depicting a lesion of endodontic origin furcally and apically associated with the distal-buccal root.



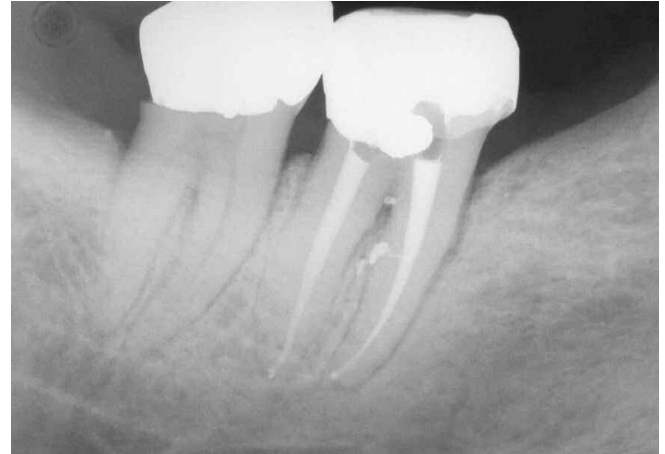*Figure 8b.* Post-op film demonstrates the shape and flow of the packed root canal system. Note treated furcal canal and apical recurvature of the distal-buccal system.

Improvement in the diagnosis and treatment of lesions of endodontic origin occurs with the recognition of the interrelationships that exist between pulpal disease flow and the subsequent egress of irritants along the root canal system's anatomical pathways (*Figure 10*). The elimination of endodontic lesions, regardless of location, would be accomplished through tooth removal because an extraction serves not only to remove the tooth but, most importantly, the complete contents of the root canal system. However, it is possible to accomplish this same goal by conventional root canal therapy.

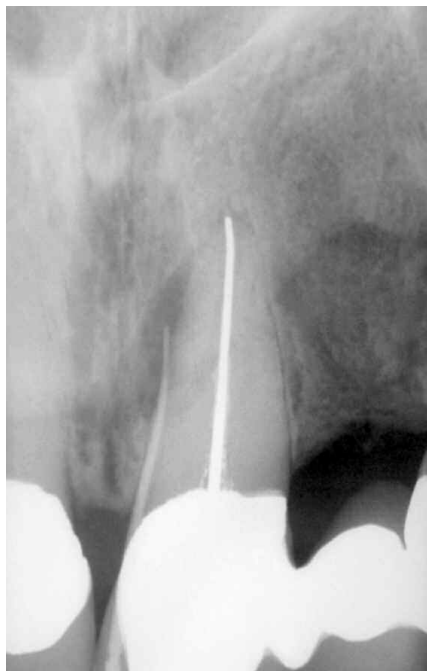Clearly, the predictable resolution of endodontic lesions will be dependent on many treatment variables, including diagnosis, complete access to the root canal system, skill, diligence, determination, and anatomical familiarity in utilizing treatment techniques carefully directed towards three-dimensional cleaning, shaping and obturation of the root canal system. ▲



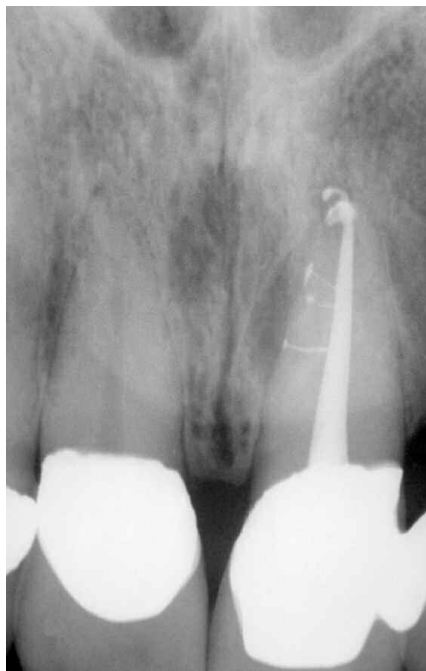*Figure 9a. Pre-op film depicting posterior bridge abutment with a history of recurrent submarginal distal decay/temporization. Buccal intersulcular pocketing and drainage was verified with a gutta percha point tracing into furcal lesion.*



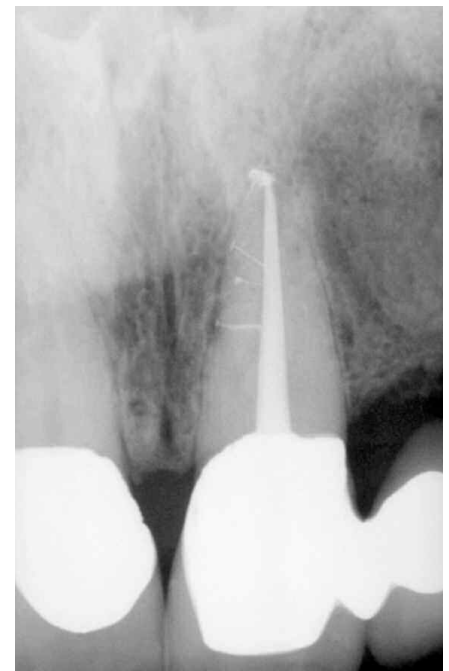*Figure 9b. Post-op film with bridge removed and tooth banded to facilitate root canal therapy and prevent fracture. Note two treated lateral canals positioned furcally. Re-attachment was noted one week after cleaning and shaping.*



*Figure 10a. Pre-op film depicting a maxillary central incisor bridge abutment. A gutta percha point traces a fistulous tract to a large lateral root lesion. The canal is considerably under-filled and slightly overextended.*



*Figure 10b. Post-op film after three-dimensional cleaning, shaping and obturation. Note the three treated lateral canals.*



*Figure 10c. Five-year review demonstrates the importance of three-dimensional endodontic treatment and excellent progressive healing.*