

# ENDODONTIC OVERFILLS: GOOD? BAD? UGLY?

by Clifford J. Ruddle, D.D.S.

Many dentists practice with the misconception overfills cause biological harm.<sup>1</sup> Many receive misinformation that overfills cause clinical failure.<sup>2</sup> Others have embraced preparation schemes that intentionally work short of the canal terminus due to the overfill myth.<sup>3</sup> Certainly, this has led to a variety of cleaning and shaping misadventures. How we use language to communicate to ourselves and others generates a belief system to impact our actions and results. The endodontic word "overfill" needs to be addressed and clarified as it is commonly misused.

Mismanagement of the apical one-third during canal preparation contributes to obturation overextensions or ghost packs that are scarcely visible or nonexistent. Additionally, improper canal preparation compromises three-dimensional obturation and at times provokes emotions ranging from uncertainty before, fear during, and loathing after viewing the packed case. This article will analyze the *overfill* issue as it relates to endodontic success and failure and answer the lingering question: Are overfills good, bad, or ugly?

## THE OVERFILL PARADIGM

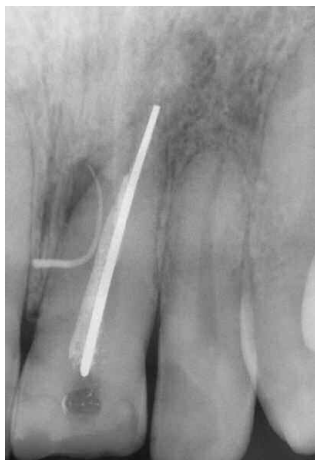Traditional endodontic education defines overfills as extending the endodontic filling material either laterally or vertically into

the attachment apparatus. It was and still is common to blame the overfill as the cause of endodontic failure. That is if a patient exhibits clinical symptoms, has clinical pathology associated with an endodontically treated tooth, or has developed a lesion of endodontic origin.

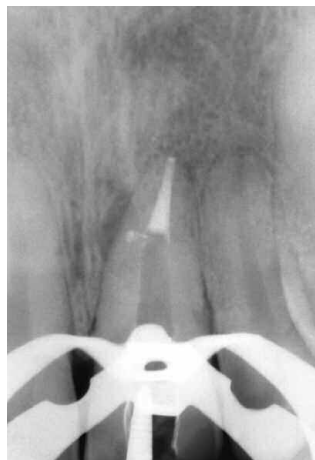It is not mysterious that countless overfilled cases do not fail and are successful over time (*Figures 1-4*). Researchers and clinicians who reconsidered the overfill issue and examined cases clinically, surgically, microscopically, and looked at postmortems histologically identified those factors as contributing to endodontic failure.<sup>4,7</sup> It is now well understood that endodontic cases that have been three-dimensionally cleaned, shaped, and packed do not fail because there are minute amounts of sealer and/or gutta percha in the attachment apparatus.<sup>8,9</sup> It is critical to define and make the distinction between the *overfill which is an obturation overextension with internal underfilling vs the three-dimensionally cleaned, shaped, and packed root canal that exhibits surplus after filling*.

## FACTORS CONTRIBUTING TO PACKING PROBLEMS

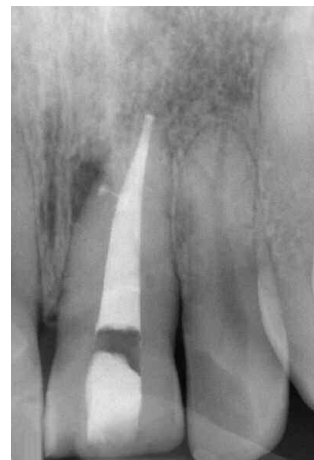The vast majority of so-called packing problems are due to inadequate canal preparation followed by, to a lesser extent,



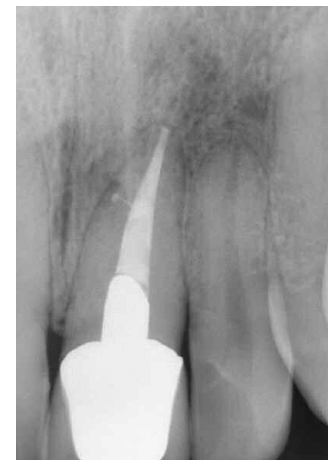*Figure 1a. Diagnostically, a gutta percha point traces a fistula to a lesion of endodontic origin. The etiology of failure is overextension with underfilling.*



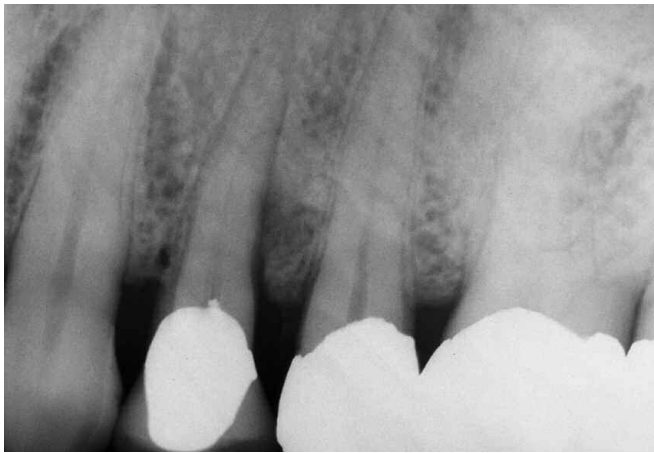*Figure 1b. Following retreatment the downpack film demonstrates three-dimensional endodontics and slight surplus after filling.*



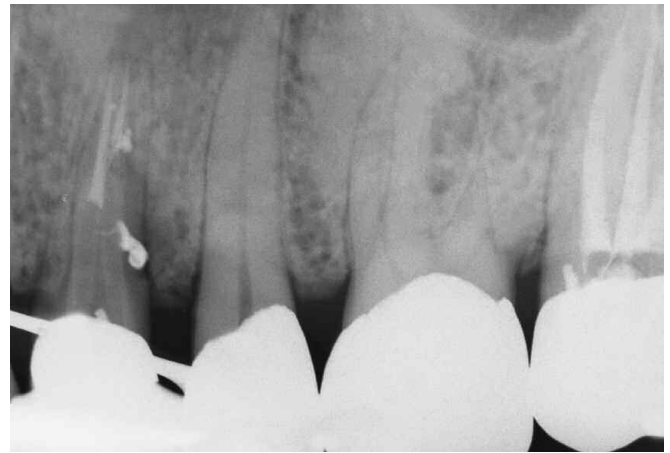*Figure 1c. Visual endodontics allows an inside look at root canal system anatomy.*



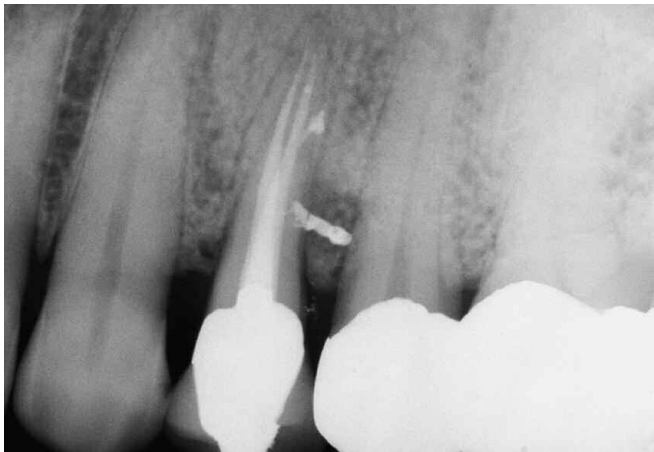*Figure 1d. A 10-year recall radiograph shows healing.*



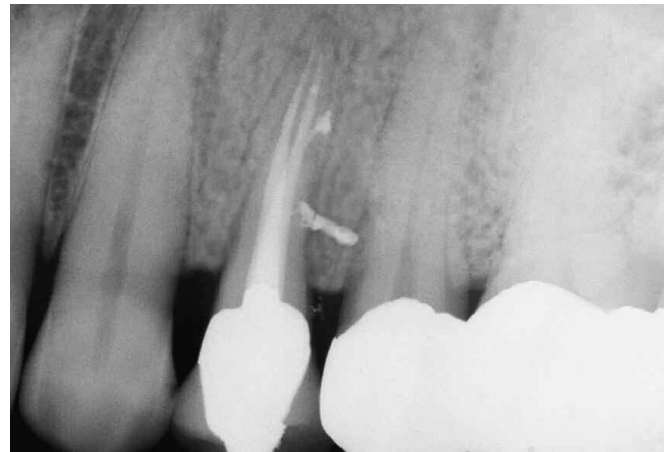*Figure 2a. A maxillary first bicuspid with a large distocrystal lesion of endodontic origin.*



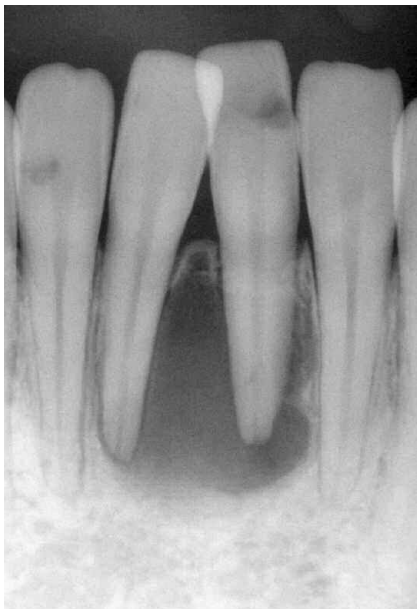*Figure 2b. A radiograph at the conclusion of the downpack demonstrates multiple portals of exit and surplus after filling.*



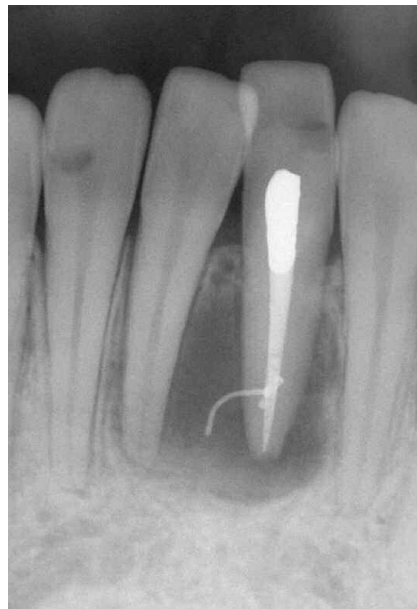*Figure 2c. Endodontic post-operative radiograph.*



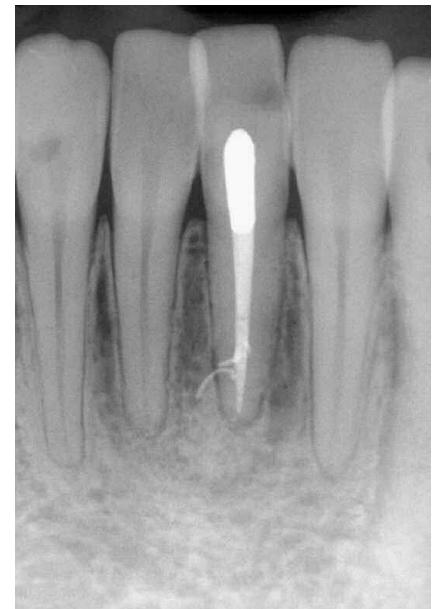*Figure 2d. A 5-year recall film shows excellent healing laterally and apically.*



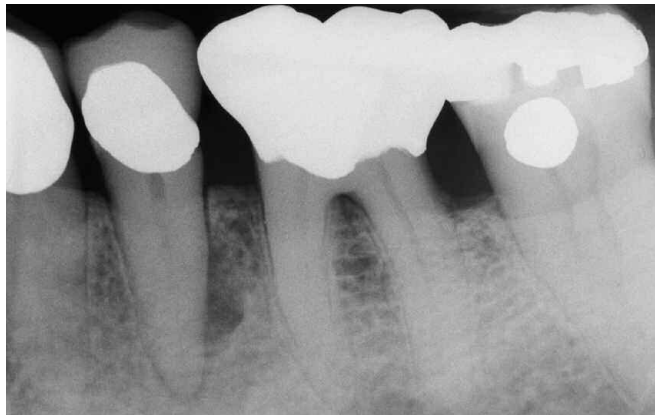*Figure 3a. A pre-operative radiograph of the mandibular central incisors reveals a large lesion of endodontic origin encompassing the diverging roots.*



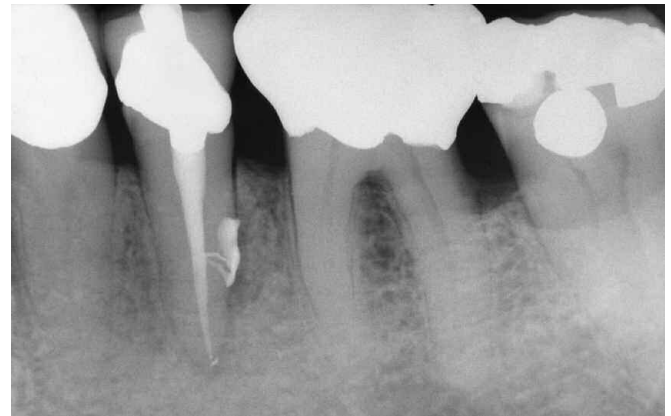*Figure 3b. A post-operative film demonstrates a dense three-dimensionally packed root canal system with several lateral canals, including a rope of gutta percha exiting laterally.*



*Figure 3c. A 15-year recall film shows root realignment and excellent osseous repair. Note that surplus material after filling does not prejudice the endodontic outcome.*



*Figure 4a. A pre-operative radiograph of a mandibular second bicuspid reveals a large lateral lesion of endodontic origin.*



*Figure 4b. A 10-year recall demonstrates excellent osseous repair. Surplus after filling has not prevented repair.*

improper cone fit or obturation technique. Most dentists were trained to negotiate and prepare the apical one-third of the root canal first using stainless steel files with a .02 taper followed by a coronal flaring technique to facilitate obturation. During the initial stages of cleaning and shaping procedures, instrument-dentin binding commonly occurs on the file's more coronal cutting blades as the rate of taper of the instrument often exceeds the rate of taper of the canal.

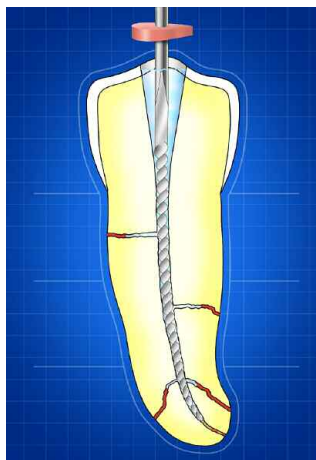
When an instrument is binding in the canal in its coronal aspect, the clinician has lost apical file control. This sets the stage for the following events to impact obturation outcomes.<sup>10</sup>

1. Loss of apical file control is generally related to technique and failure to first remove restrictive dentin in the coronal two-thirds of the canal. Increased pressure on the more coronal cutting flutes of any file type will seriously limit the clinician's tactile control when directing the file apically.

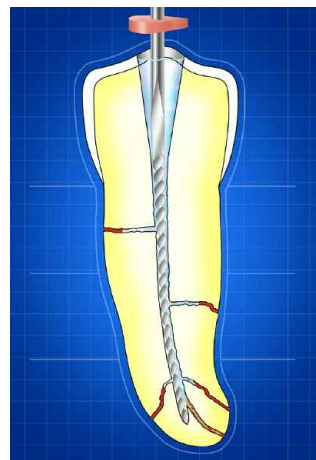
Failure to perform early coronal enlargement procedures allows the pre-curved file to straighten, and it arrives

dangerously straighter in the typically curved apical one-third anatomy. This loss of apical file control predisposes to blocks, ledges, perforations, or foraminal transportations (*Figures 5-8*).

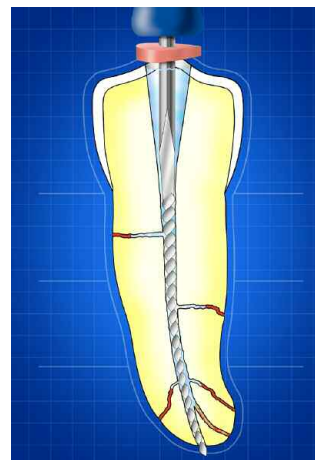
2. Narrow, more parallel canals do not accommodate a sufficient reservoir of irrigant, which limits its penetration into all aspects of the root canal system and the deep anatomy in particular. Insufficient irrigation discourages cleaning, leaving pulp, bacteria, and related irritants within the root canal system.
3. Generations of dentists have been trained to negotiate and prepare the apical one-third of the canal first. Clinicians are beginning to appreciate that narrow, more parallel, nonflared canals hold a small or nonexistent volume of irrigant encouraging dentinal mud to accumulate, sludge and potentially block portions of the root canal system.
4. Initially, forcing files through coronally restrictive canals encourages the inoculation of irritants periapically resulting in more post-operative pain.



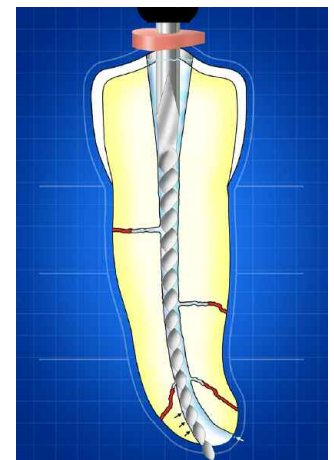
*Figure 5. Working short of the canal terminus predisposes to a block and a resultant loss of working length. Coronally restrictive canals limit effective irrigation procedures.*



*Figure 6. Failure to use precurved patency files contributes to blocks, and apically directed file grinding results in a ledge. Note the file binding over length.*



*Figure 7. The summation of no preflaring, working short, ineffective irrigation, failure to precurve files, and apical file grinding equates to a perforation outcome.*



*Figure 8. Larger files fail to follow the apical pathway of curvature transporting the foramen, resulting in a preparation that exhibits reverse apical architecture.*

5. Negotiating and preparing the apical one-third first, followed by traditional coronal flaring techniques, produces a more direct path to the radiographic terminus decreasing the earlier-recorded working length. Failure to recognize a decrease in working length leads to needless overenlargement of the foramen and, worse yet, bigger, stiffer, and less flexible files carried to length contribute to foraminal rips, tears, and transportations (*Figure 8*).
6. Finally, negotiating the apical one-third first with smallest files equates to more difficulty in accurately interpreting working length radiographically or with apex locators. Failure to accurately determine working length potentiates the iatrogenic events previously discussed.

These examples illustrate how canal preparation plays a central role in endodontic success and failure, and will influence cleaning and shaping procedures, post-operative symptoms, the ability to dry canals, controlled three-dimensional obturation, and ultimately, the endodontic outcome.

### CANAL PREPARATION OBJECTIVES

The biological objective of canal preparation is the complete elimination of the pulp, bacteria, and related irritants from

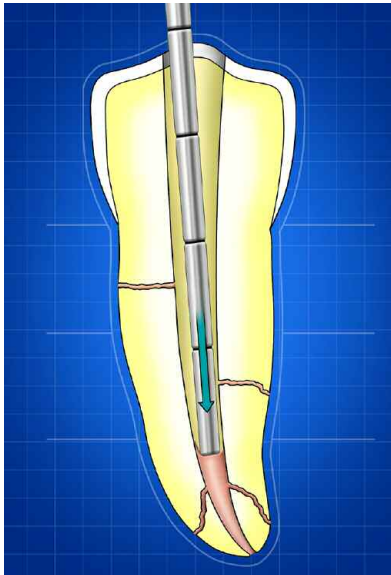
the root canal system. Mechanical efforts are directed toward accomplishing the biological objective by creating a predefined shape that can be easily packed in three dimensions (*Figures 9 and 10*).

To meet this biological requirement, the following mechanical objectives must be designed into each cleaning and shaping procedure<sup>10</sup>:

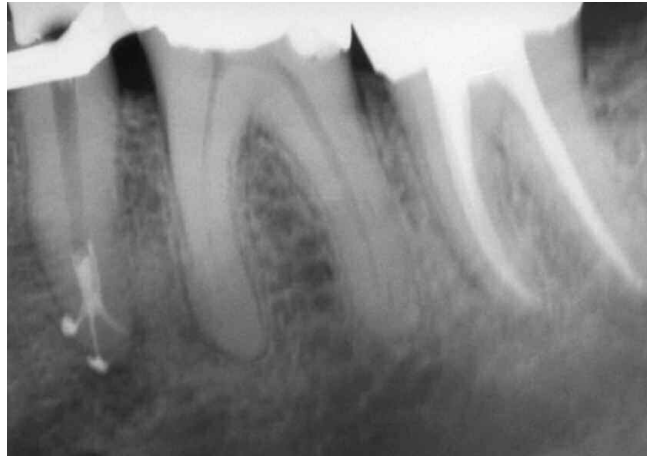1. A continuous tapering canal preparation
2. The original anatomy is maintained
3. The position of the foramen is maintained
4. The foramen is as small as practical

### IS IT REALLY OVERFILLED?

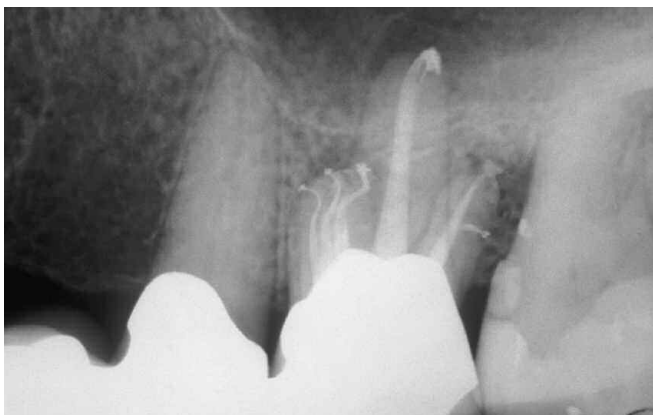Clinicians want to pack the prepared root canals progressively tapering toward the radiographic terminus (mechanical objective #1). Moving apically, canal preparations designed to have narrowing cross-sectional diameters exhibit tremendous resistant form for controlled, hydraulic, and predictable three-dimensional obturation (*Figures 11 and 12*).



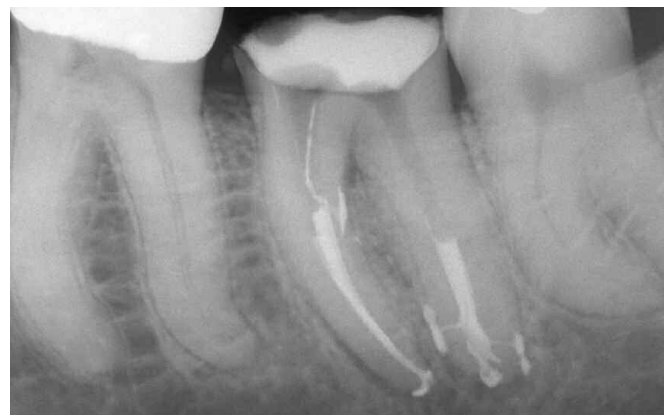*Figure 9. Shaping strategies should be directed toward creating canal preparations that are three-dimensionally cleaned and easy to pack.*



*Figure 10. Carrying a vertical wave of warm gutta percha into the apical one-third results in corkage. Shaping facilitates three-dimensional cleaning and packing.*



*Figure 11. A post-operative radiograph of a maxillary first molar abutment demonstrates complex root canal system anatomy.*



*Figure 12. A post-operative film of a mandibular second molar. The treated furcal canal traces to the furcal lesion, and the distal system terminates into four apical portals of exit.*

Unfortunately, many obturation overextensions occur because of a lack of deep shape or canal preparations that exhibit reverse apical one-third architecture. This violates all four mechanical objectives of canal preparation and results in obturation overextension with internal canal underfilling. Canals exhibiting reverse apical architecture increase the likelihood that gutta percha/sealer will lose apical one-third hydraulics, move periapically, and, importantly, fail to seal the preparation wall-to-wall in all dimensions. Endodontic cases do not fail because of surplus after filling. Biologically, these materials have been consistently well tolerated, are encapsulated in the periradicular tissues, and are irrelevant to the endodontic prognosis. Of course, I am not talking about filling the sinus in three dimensions or obturating the length of the mandibular canal. Clinicians should stop fretting about splashes or puffs of cement and minor overextensions of gutta percha when a case is cleaned, shaped, and packed three-dimensionally. The focus should be on strategies and techniques to improve canal preparation. It's axiomatic that well-shaped canals are easy to fill and obturation is quick, controlled, and three-dimensional.

## CONCLUSION

Are overfills good or bad? Change the conversation to, "Is it surplus after three-dimensional obturation or overextension and canal underfilling?" Certainly surplus material is not the endodontic goal, but rather a result of the hydraulics safely generated to achieve three-dimensionally packed root canal systems. Countless cases have been successfully performed as evidenced by clinical and radiographic long-term healing, which should assure patients, doctors, and any prosecuting attorneys.

Are overfills ugly? There is an old expression: "Who you are is where you were when!" Design, sculpt, and build root canal systems that are cleaned, shaped, and packed in three dimensions and you will begin to appreciate that surplus after filling is irrelevant to the ultimate success and failure of the case. In endodontics, we should embrace the expression, "**Just Win!**" ▲

## REFERENCES

1. Seltzer S. Ch. 11, Root canal failures. In: *Endodontology: Biological Considerations in Endodontic Procedures*. New York, NY: McGraw-Hill, 1971.
2. Ingle JI; Taintor JF. Ch.1, Modern endodontic therapy. In: *Endodontics*. 3rd ed. Philadelphia, PA: Lea & Febiger, 1985.
3. Weine FS. Ch. 7, Intracanal treatment procedures. In: *Endodontic Therapy*. St. Louis, MO: C.V. Mosby Co, 1972. Chap 7.
4. West JD. Endodontic failures marked by lack of three-dimensional seal. *The Endodontic Report* Fall/Winter: 9,1987.
5. Scianamblo MJ. Endodontic failures: the retreatment of previously endodontically treated teeth. *Revue D'Odonto Stomatologie* 17(5): 409-423, 1988.
6. Ruddle CJ. Endodontic failures: the rationale and application of surgical retreatment. *Revue D'Odonto Stomatologie* 17(6): 511-569, 1988.
7. Ruddle CJ. Surgical endodontic retreatment. *J Calif Dent Assoc* 19(5): 61-67, 1991.
8. Schilder H. Filling root canals in three dimensions. *Dent Clin North Am* 11: 723, 1967.
9. Ruddle CJ. Ch. 9, Three-dimensional obturation: the rationale and application of warm gutta percha with vertical condensation. In Cohen S, Burns RC, editors: *Pathways of the Pulp*. 6th ed. St. Louis, MO: Mosby Yearbook Co, 1994.
10. Ruddle CJ. Endodontic canal preparation: breakthrough cleaning and shaping strategies. *Dentistry Today* 13(2): 44-49, 1994.