

# CURRENT CONCEPTS FOR PREPARING THE ROOT CANAL SYSTEM

by Clifford J. Ruddle, D.D.S.

Successful endodontic treatment requires that the clinician predictably shape root canals for three-dimensional obturation. In this article, the guidelines for successful access and the concepts and strategies for canal preparation will be discussed. Additionally, the advantages of scouting and then pre-enlarging the coronal two-thirds of the canal before scouting and finishing the apical one-third will be emphasized. Although endodontic instruments can shape a root canal, this article will also review the importance of irrigants and their role in cleaning the root canal system.

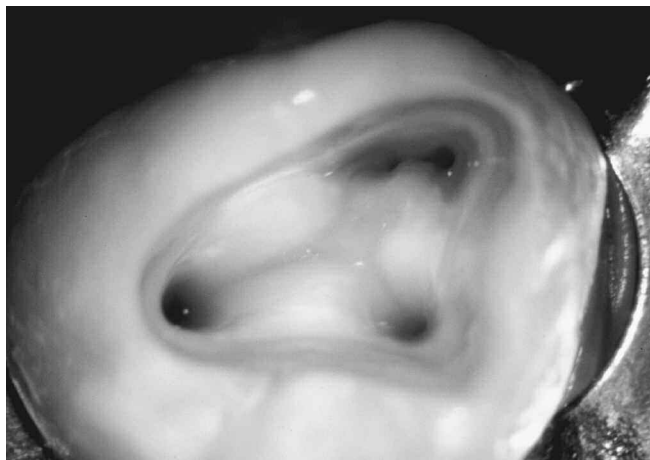## CORONAL ACCESS

The access preparation is an essential element for successful endodontics.<sup>1</sup> Preparing the endodontic access cavity is a critical step in a series of procedures that potentially leads to the three-dimensional obturation of the root canal system. Access cavities should be cut so the pulpal roof, including all overlying dentin, is removed. The size of the access cavity is dictated by the position of the orifice(s). The axial walls are extended laterally such that the orifice(s) is just within this outline form (*Figure 1*). The internal walls are flared and smoothed to provide straightline access into the orifice and

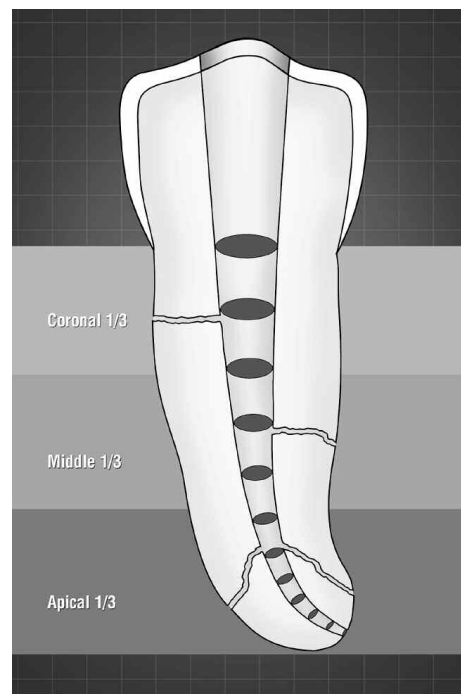
the root canal system. Additionally, access preparations are expanded to eliminate any coronal interference during subsequent instrumentation. Access objectives are confirmed when all the orifices can be visualized without moving the mouth mirror. Ideally, endodontic access cavities should parallel the principle of restorative dentistry where the axial walls of a "finished" preparation taper and provide draw for a wax pattern. Cleaning and shaping potentials are dramatically improved when instruments conveniently pass through the occlusal opening, effortlessly slide down smooth axial walls and are easily inserted into the orifice. Spacious access cavities are an opening for canal preparation.<sup>2</sup>

## CONCEPTS FOR CANAL PREPARATION

Endodontic treatment can be simplified by dividing the entire procedure into a series of smaller steps. With exceptions, the vast majority of teeth range from 19-25 mm in length. Most clinical crowns are about 10 mm and most roots range from 9-15 mm in length. If we divide the root into coronal, middle, and apical one-thirds, then each third is between 3 and 5 mm in length (*Figure 2*). The power of this strategy is best appreciated in longer roots that hold more complicated canals which



*Figure 1. A photograph at 15x demonstrates straightline access, divergent axial walls and that the orifices are just within this outline form.*

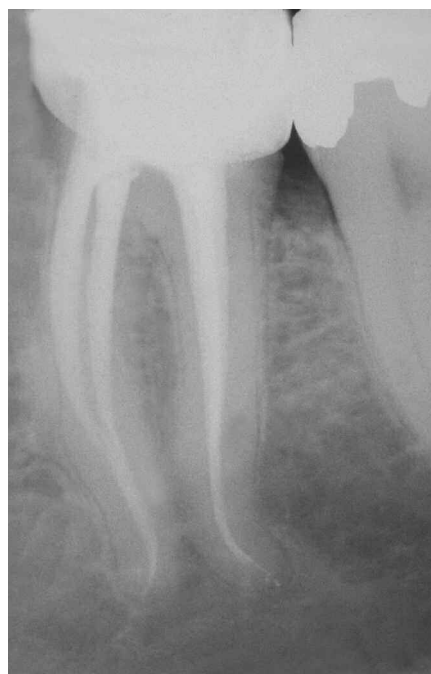


*Figure 2. A graphic illustrates the concept of dividing the roots into thirds and that each cross-sectional diameter of the canal narrows towards the foramen.*

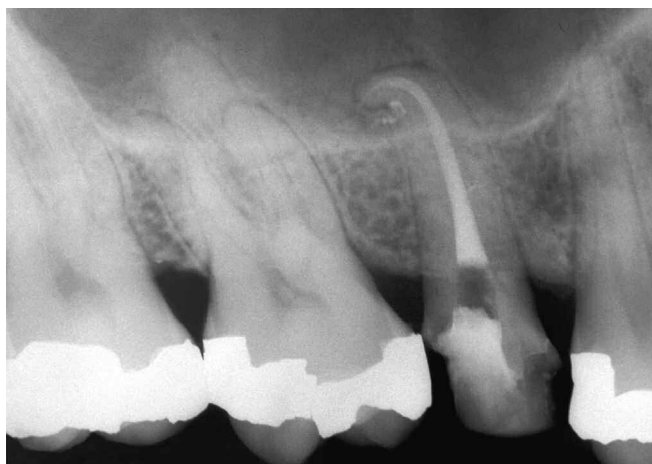exhibit significant calcification, challenging curvatures or deep divisions (*Figure 3*). In general, clinicians should appreciate that more calcification is encountered within the pulp chamber. Calcification may also extend into the coronal and, to a lesser extent, the middle one-thirds of canals. Fortunately, the apical one-thirds of canals, although more narrow, are typically open and free of calcification. Pre-enlarged canals increase the volume of irrigant, encourage the elimination of debris, and afford better access and control when preparing the apical one-third microanatomy.<sup>3</sup>

## STRATEGIES FOR CANAL PREPARATION

When straightline access has been completed and all the orifices have been identified, attention is directed towards preparing the root canal. As will be discussed later in this



*Figure 3a. A post-treatment film demonstrates long roots, canal recurvatures, and fulfilling the mechanical objectives for canal preparation.*

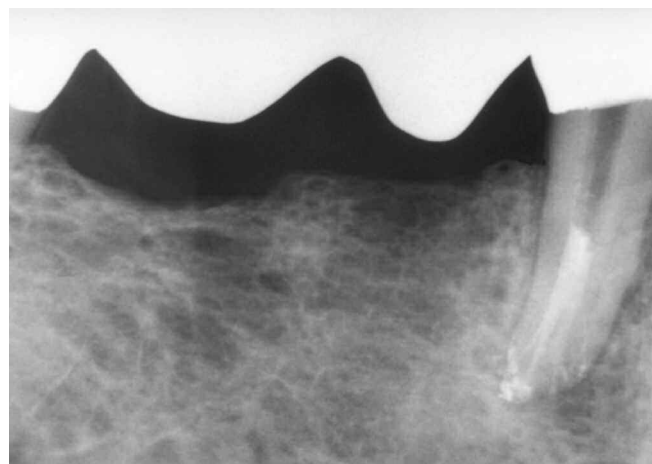


*Figure 3b. A post-treatment film emphasizes the importance of maintaining the shape and packing a highly curved system.*

paper in the section on irrigants, if the pulp is vital and bleeding, the chamber is filled brimful with a viscous chelator. In the instance where the pulp is necrotic, the chamber is irrigated and completely filled with a 5.25% solution of warm NaOCl. Based on the pre-operative radiographs, the smaller stainless steel files are measured and precurved to conform to the anticipated full length and curvature of the root canal. Stainless steel 0.02 tapered 10 and 15 hand files are then utilized to explore the coronal two-thirds of the root canal system (*Figure 4*).

After negotiating the coronal two-thirds, the canal is flushed with NaOCl and, depending on the operator and available space, may be pre-enlarged using hand instruments, gates glidden drills utilized like brushes, or rotary NiTi shaping files (*Figure 5*). With the coronal two-thirds optimally prepared and filled with irrigant, the apical one-third is then scouted and reconnaissance information gathered. Small hand files are used to negotiate the rest of the canal, confirm a smooth glide path to the terminus, and establish patency (*Figure 6*).

Typically, working length is confirmed with a 15F in situ utilizing an electronic apex locator, computer digital radiography, or conventional films. Even with the advantages of electronic apex locators, occasionally it is valuable to radiographically



*Figure 3c. A post-treatment film of an endodontically treated anterior bridge abutment reveals multiple apical portals of exit.*

observe the position of a file within a root canal. With the root canal negotiated and the anatomy fully appreciated, a decision can be made whether to finish the apical one-third with hand or rotary instruments. The concept of first pre-enlarging a canal followed by finishing its apical one-third is analogous to a crown preparation procedure in which the tooth is first reduced prior to finishing the margins.

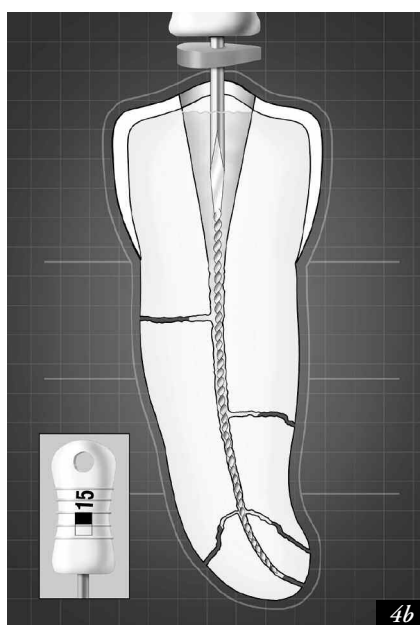
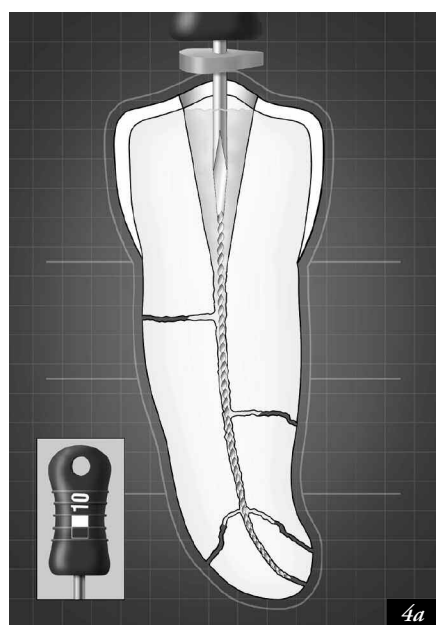
### SCOUTING THE CORONAL 2/3 OF THE CANAL

Cleaning and shaping outcomes are significantly improved when the coronal two-thirds of a canal is first scouted and then pre-enlarged (Figure 5).<sup>4</sup> As has been mentioned, stainless steel ISO 0.02 tapered sizes 10 and 15 hand files are utilized to scout the coronal two-thirds of the canal and confirm or create a glide path or pilot hole before any rotary NiTi instruments

are introduced.<sup>5</sup> With the onset of NiTi rotary instrumentation, the role of “hand” instruments has diminished and been redefined. For many rotary file users, hand instruments are now primarily used to gather intracanal reconnaissance information and when necessary to create sufficient space prior to using more efficient NiTi instruments. Before discussing the small hand files, it would be beneficial to briefly review their geometries.

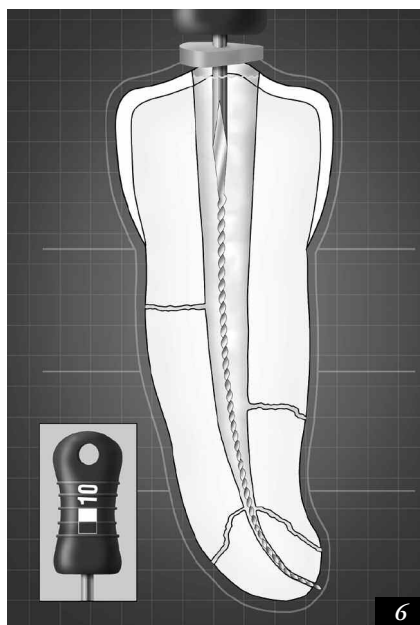
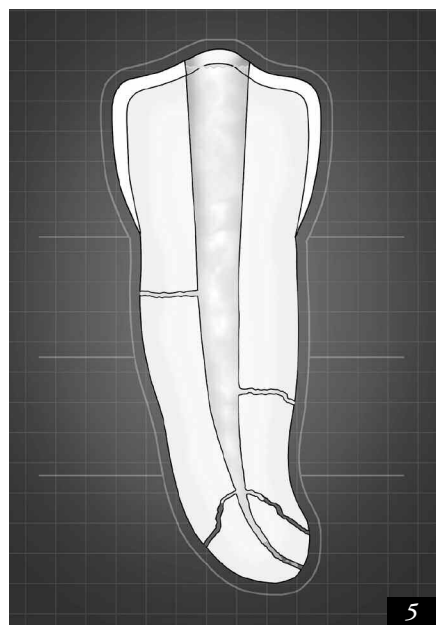
### ISO FILE GEOMETRIES

The task of preparing a root canal can be improved by better understanding the instruments, their geometries, and designated nomenclature.<sup>6</sup> ISO sized instruments are available in different lengths, but in common they have 16 mm of cutting flutes. The cross-sectional diameter at the first rake angle of



*Figure 4a.* A scouter file may be used to confirm straightline access, verify the diameter of a canal and reveal root canal system anatomy.

*Figure 4b.* The 15 file follows the path of the 10 file, improves the glide path and dictates the next clinical move.



*Figure 5.* A graphic demonstrates that once the coronal two-thirds of a canal has been pre-enlarged then there is improved access to the apical one-third.


*Figure 6.* A graphic illustrates that the apical one-third has been negotiated and patency established.

any file is termed  $D_0$ . One millimeter coronal to  $D_0$  is termed  $D_1$ , while two millimeters coronal to  $D_0$  is called  $D_2$ , and so forth. The most shank-side cutting flute is 16 mm coronal to  $D_0$ , represents the largest diameter and most active aspect of the instrument, and is termed  $D_{16}$ . Each instrument receives its numerical designation, or file name, from its diameter at  $D_0$ . This universal nomenclature is useful and allows clinicians, inventors, and machinists to discuss various aspects of a file at specific locations. Since ISO files have a standard taper of 0.32 mm over 16 mm of cutting blades, then the taper of any specific instrument is 0.02 mm per millimeter (*Figure 7*). Although the file name represents the size at its  $D_0$  diameter, any given instrument has multiple cross-sectional diameters over its active blades. The 10 file is 0.10 mm in diameter at  $D_0$ , tapers 0.32 mm over 16 mm, and has a diameter of 0.42 mm at  $D_{16}$ . Similarly, the 15 file is 0.15 mm in diameter at  $D_0$ , tapers 0.32 mm over 16 mm, and has a diameter of 0.47 mm at  $D_{16}$ . The importance of appreciating these dimensions will become apparent as we further examine the functions of the small hand files especially during their use in the apical one-third of a canal.

## PURPOSE OF THE SCOUTING FILES

With a better appreciation of the nomenclature and geometries of ISO files, then we can better use these instruments to scout any portion of a canal and gather important reconnaissance information. Small “scouter files” should not be thought of as just measuring wires, rather they can additionally provide feedback regarding:<sup>7</sup>

1. Scouter files immediately reveal the cross-sectional diameter of a canal and provide information as to whether the canal is open, restricted, or seriously calcified. Before any rotary instrument can be safely introduced into the canal, sufficient space must exist to accommodate and guide their non-cutting tips. In other words, there must be a pilot hole and a smooth glide path for NiTi rotary instruments to follow. As an example, if a canal has been scouted to within 2-3 mm of anticipated working length with 10 and 15, 0.02 tapered files, then more space exists coronal to their tips



*Figure 7. A photograph showing ISO 0.02 tapered 10, 15 and 20 files. Each instrument tapers 0.32 mm over its 16 mm of cutting blades.*

than the files' numerical names suggest. Recall a 10 file and 15 file have 16 mm of cutting flutes and their  $D_{16}$  diameters are 0.42 and 0.47 mm, respectively. These small instruments provide an opening for the implementation of rotary instruments.

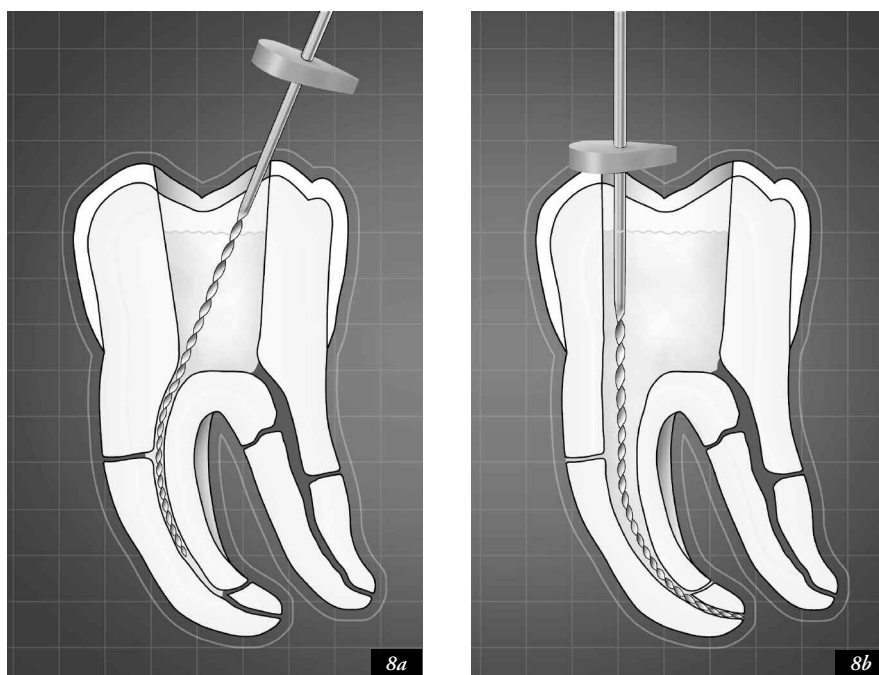
2. Scouter files confirm the presence or absence of straight-line access. Clinicians can observe the handle position of an instrument to see if it is upright and paralleling the long axis of the tooth or skewed off-axis. In the instance where the roots are under the circumferential dimensions of the clinical crown and the file handle is upright, then the clinician is able to confirm both coronal and radicular straightline access. In instances where the handle of the initial scouting instrument is off the long axis of the tooth, then pre-enlargement procedures should be directed towards uprighting the file handle (*Figure 8a*). To upright the handle of the small scouter files oftentimes requires refining and expanding the access preparation and selectively removing restrictive dentin from the coronal one-third of the canal (*Figure 8b*). This procedural nuance is critical and simplifies all subsequent instrumentation procedures while virtually eliminating many cleaning and shaping frustrations.
3. Scouter files can provide information regarding root canal system anatomy. Clinicians need to appreciate the five commonly encountered anatomical forms which include canals that merge, curve, recurve, dilacerate or divide. Scouter files provide critical information regarding the anatomy and give important feedback regarding the canal's degree of *curvature*, *recurvature*, or if there is a *dilaceration*. Further, before introducing rotary instruments, clinicians need to know if a single canal coronally subsequently *divides* or if two or more systems within a root *merge* along their length. It must be recognized that certain root canals exhibit anatomical configurations which preclude the safe use of NiTi rotary files.

## THE IRRIGANTS

No instrument should be introduced into the root canal space until the appropriate irrigant is introduced into the pulp chamber. As mentioned previously, when straightline access has been completed and all the orifices have been identified, the choice of irrigant may be determined as follows: If the pulp is vital and bleeding, it is desirable to fill the chamber brimful with a viscous chelator. In the instance where the pulp is necrotic, the chamber is irrigated and may be completely filled with a 5.25% solution of warm NaOCl. A few words on irrigants are in order due to their extreme importance.

### SODIUM HYPOCHLORITE

In the United States, Clorox is the source for obtaining NaOCl with a full-strength concentration of 5.25%. NaOCl is a powerful and inexpensive irrigant that has been shown to readily digest pulpal tissue.<sup>8</sup> NaOCl should be used clinically in concentrations of approximately 3-5% to take advantage of its ability to destroy spores, viruses and bacteria and importantly, its unique ability to digest vital and necrotic pulp tissue from all aspects of the root canal system.<sup>9</sup>



*Figure 8a.* When the handle of the file is off-axis it oftentimes confirms inadequate coronal and radicular access which predisposes to iatrogenic events.

*Figure 8b.* Expanding the access cavity in conjunction with coronal pre-enlargement uprights the file and encourages it to slide to length.

Studies have shown that in pre-flared canals where the coronal two-thirds is first pre-enlarged, warming NaOCl to approximately 60°C (140°F) significantly increases the rate and effectiveness of tissue digestion.<sup>10, 11</sup> To maximize tissue digestion, access cavities must be filled brimful with NaOCl (*Figure 9*). In fact, one of the important advantages of pre-treatment is to build teeth up so they have pulp chambers that can retain irrigants. The potential for an irrigant is maximized when it is *heated*, flooded into *shaped canals*, and given ample *time* to work.

The frequency of irrigation is dictated by the amount of work that a particular instrument performs. It is axiomatic to always irrigate, recapitulate and re-irrigate just before the canal becomes blocked. Practically, the clinician never knows this exact moment; therefore, it is best to err on the side of caution by going through the cycle of replenishing irrigant, recapitulating and re-irrigating at least after every two to three instruments. In general, this cycle should be repeated more frequently in tighter, longer and more curved canals, and especially if the system exhibits unusual anatomy. Files potentially carry irrigant progressively deeper into the canal by surface tension. However, when an instrument is placed into a relatively small canal, the file tends to displace the irrigant. When the instrument is withdrawn, irrigation flows back into the space the file occupied. This phenomenon must be appreciated and recognized so as to clinically integrate the most efficacious irrigation method.

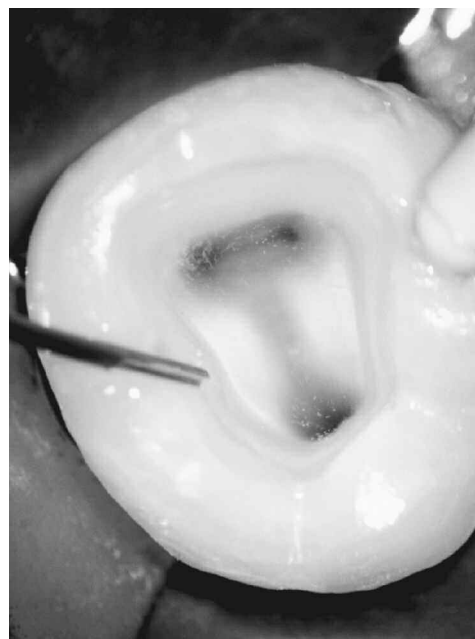#### CHELATING AGENTS

Chelating agents containing ethylenediaminetetraacetic acid (EDTA) may be used clinically to eliminate many cleaning and shaping frustrations. The purpose of a chelator is for lubrication, emulsification, and holding debris in suspension. Chelators are formulated for clinical use and can be selected in either a viscous suspension or an aqueous solution. Viscous

suspensions have a “cocktail” of ingredients typically suspended in a water soluble vehicle.

#### Viscous Chelators

Glyde (*Dentsply Maillefer*) or RC Prep (*Premier Dental Products*) are *viscous* chelators whose principle ingredients are EDTA, urea peroxide and propylene glycol. A *viscous* suspension of a chelator advantageously promotes the “emulsification” of vital tissue and facilitates the negotiation of the canal. Collagen is a major constituent of vital pulp tissue and can be inadvertently packed into a glue-like mass that contributes to iatrogenic blocks. In vital cases, attempting to negotiate any portion of a canal with a 10 file without the aid



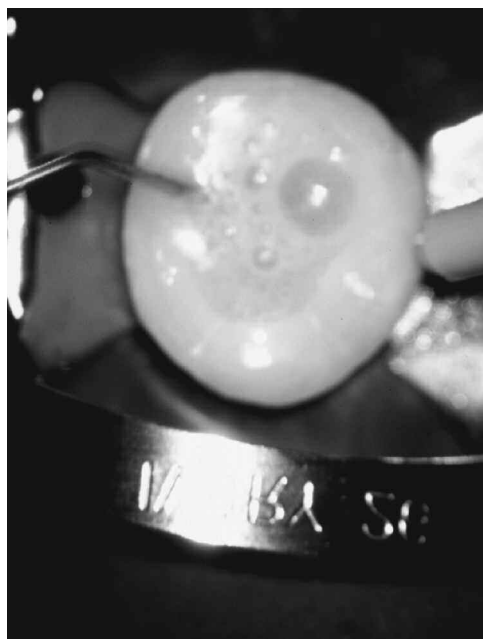
*Figure 9.* A photograph of a mandibular molar demonstrates that the access cavity is filled brimful with heated full-strength NaOCl.

of a chelator can be dangerous. Clinicians should recognize that when the instrument is withdrawn the vital tissue tends to collapse and readhere to itself. A chelator discourages tissue readherence and accelerates emulsification by leaving a favorable pilot hole which facilitates the introduction of the next sequentially larger instrument. Chelators should be used for short periods of time as their protracted use can soften dentin and predispose to iatrogenic events.<sup>12</sup>

A viscous chelator is best used for holding debris in “suspension”. As an example, RC Prep encourages the flotation of pulpal remnants and dentinal mud which reduces the probability of blocking the canal. Sodium hypochlorite follows the use of RC Prep and is irrigated passively, frequently, and voluminously. Using RC Prep in concert with NaOCl releases oxygen which kills anaerobic bacteria. In combination, RC Prep and NaOCl produce significant effervescence, creating an elevator action that lifts and liberates debris from the root canal system (*Figure 10*).<sup>2,13</sup>

#### *Aqueous Chelators*

An *aqueous* solution of chelator is best reserved for “finishing” the preparation as it removes the smear layer that is formed by the cutting action of instruments.<sup>14,15</sup> Although rotary nickel-titanium instruments are known to effectively auger debris out of a canal, they are also well-known to burnish dentinal mud and organic debris into the anatomical eccentricities off the rounder aspects of the canal and the dentinal tubules.<sup>16</sup> From a clinical point of view it might be wise to irrigate with EDTA (*Roth International*) after every few NaOCl irrigations. This alternating sequence would remove accumulating debris which would potentially enhance the penetration of NaOCl into the anatomy. In any event, following optimal canal preparation, a 17% solution of aqueous EDTA is irrigated into the canal. As we will see in the next section, an aqueous solution of a chelator can be activated to enhance cleaning.<sup>17</sup> Research has shown that a one minute rinse with EDTA eliminates the smear layer, opens up the dentinal tubules and provides a cleaner surface against which obturation materials adapt.<sup>14,18</sup>



**Figure 10.**  
*A photograph demonstrates vigorous effervescence which results when NaOCl is irrigated into a chamber filled with RC Prep.*

## PRE-ENLARGING THE CORONAL 2/3 OF THE CANAL

Once a zone of the canal has been scouted, the pre-enlargement of that portion of the canal can be accomplished with a variety of hand or rotary shaping instruments. The more important pre-enlargement breakthroughs are:

1. Pre-enlargement gives the clinician better *tactile control* when directing small precurved negotiating files into the delicate apical one-third microanatomy. Early coronal two-thirds enlargement removes restrictive dentin and reduces significant pressure from the more coronal cutting flutes of any file type.
2. Pre-enlarged canals hold a greater and more effective volume of irrigant which serves to *enhance cleaning*. Narrow, more restrictive preparations are dangerous as files work in virtually dry canals. A pre-flared canal exhibits shape and holds a greater volume of warm irrigant which accelerates the apical and lateral digestion of pulp.
3. Pre-enlarged and tapered canals dramatically promote the *removal of dentine mud*. In fact, the canal is always most dangerous when its walls are nearly parallel. A pre-flared canal increases the volume of irrigant and provides an improved pathway for the liberation of dentine mud.
4. Pre-enlargement procedures *decrease post-treatment problems* as the bulk of the pulp and, if present, bacteria and related irritants have been removed. Passing files through a cleaned pre-enlarged preparation equates to less debris inadvertently inoculated periapically. Passing files through underprepared canals coronally pushes more irritants periapically and generates more post-operative exacerbations.<sup>19</sup>
5. Pre-enlargement procedures generally *improve diagnostics*. A pre-enlarged canal passively accepts a larger file into the apical one-third where its terminal extent is easier to visualize radiographically. Electronic apex locators are more accurate when utilized in pre-enlarged canals as instruments are more likely to snug into dentin towards their terminal extents.<sup>20</sup> When the clinician does establish a working length, it will be more accurate as it occurs after a more direct path to the terminus has been established. Files, gates gliddens and rotary shaping files confined to the coronal two-thirds generally require no working films because there is little or no advantage to verify their short position.

## APICAL 1/3 SCOUTING AND FINISHING

Once the coronal two-thirds of a canal has been optimally pre-enlarged, the clinician has significantly improved access to the apical one-third of the root canal system for scouting and finishing procedures. As the canal oftentimes exhibits its most dramatic curvature and divisions in this zone, small flexible stainless steel hand files are used to scout and gather important “reconnaissance” information. When initiating apical one-third finishing procedures, the clinician should adhere to the following steps:

### 1. SCOUT TO TERMINUS

Small scouting files provide information regarding the apical one-third of root canals. Pre-enlarged canals generally accommodate small pre-curved hand files which can be

utilized to gather specific information regarding the canal's apical one-third cross-sectional diameter and anatomy. The commonly encountered anatomical forms are canals that merge, curve, recurve, dilacerate or divide.<sup>21</sup> Even within each category, a considerable range of variation is normal.

## 2. ESTABLISH PATENCY

The breakthrough to apical one-third finishing procedures is canal "patency" and is performed by gently pushing a small, highly flexible 10F to the radiographic terminus (RT).<sup>2</sup> To ensure patency, the file tip is intentionally inserted 1 mm through the foramen to discourage the accumulation of debris (*Figure 6*). Recall the 10F at D<sub>1</sub> is equivalent to 0.12 mm. Gently moving the 0.02 tapered 10F one mm long will reduce the percentage change at D<sub>0</sub> between the 10 and 15 files from 50% to 25%. Importantly, working a small, flexible file to the radiographic terminus will encourage the elimination of all the pulp, related irritants, and dentinal mud. Keeping the canal terminus patent discourages blocks, ledges and perforations. It is illogical to assume that passing a small file passively and minutely through the apical foramen is going to prejudice the result or predispose to any irreversible conditions when one reflects on the rich collateral circulation and healing capacity available in the attachment apparatus.

## 3. WORKING LENGTH

Clinicians who perform many endodontic procedures can generally judge the working length with uncanny accuracy. With experience, certain electronic apex locators can also provide valuable, accurate and reliable information as to working length. Improved electronics in specific apex locators provide greater accuracy in length determination even in canals that contain exudates or electrolytes (*Figure 11*).<sup>22</sup> It should be understood that apex locators do not replace films but are used intelligently and in conjunction with radiographs.<sup>23</sup> When a predictable and smooth glide path is established to the RT and working length is confirmed, then the apical one-third of the canal can be finished in a variety of ways.



*Figure 11a.* The Endo Analyzer provides the clinician a state-of-the-art unit that can be utilized to perform vital pulp testing or determine working length.

## 4. FINISHING

Creating a canal preparation whose cross-sectional diameter progressively narrows and is smallest apically allows for controlled three-dimensional obturation to the consistent drying point.<sup>24</sup> Clinicians must stop fretting about whether their gutta percha apically has circumferential dentin or cementum and become more concerned with eliminating the root canal system as a source of irritation, packing the root canal system in three dimensions, and promoting the health of the attachment apparatus. Consistently "finishing" the root canal preparation is the *sine qua non* of excellence and is confirmed by gauging and tuning procedures.

## GAUGING AND TUNING

The clinician will have supreme confidence the apical one-third has been optimally finished, regardless of the technique employed, when the canal is gauged and tuned with 0.02 tapered hand files. The classic apical one-third preparation that can be both "cleaned" and "packed" is a 10% tapered shape that has been enlarged to at least a 20 file at the terminus and where each successively larger instrument uniformly moves away from the foramen by 1/2 mm increments.

*Gauging and tuning* with ISO 0.02 tapered instruments is a technique directed towards confirming a uniform taper in the apical one-third of the root canal preparation (*Figure 12*). The ideal finished preparation will always exhibit deep shape where the canal progressively tapers between 8 to 10 percent in its apical one-third.<sup>16</sup> The clinician begins to *gauge* the most apical cross-sectional diameter of the canal when a hand or rotary instrument just snugs into the terminus and resists further apical travel. In order to prove with certainty that the diameter of this file at length represents the true size of the foramen, the clinician must then *tune*. Tuning is the clinical activity of recapitulating through a series of successively larger instruments and working them until they are observed to uniformly back out of the canal. The interval of back-out between successively larger files should not be

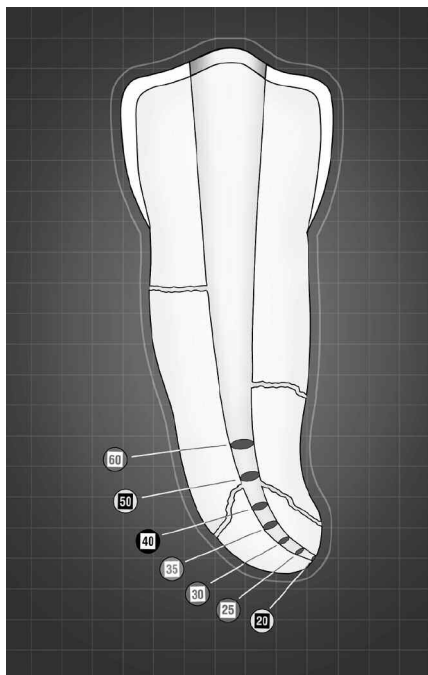


*Figure 11b.* The Root ZX has a large backlit screen, an easy to read digital read-out, and provides an accurate method for determining working length.

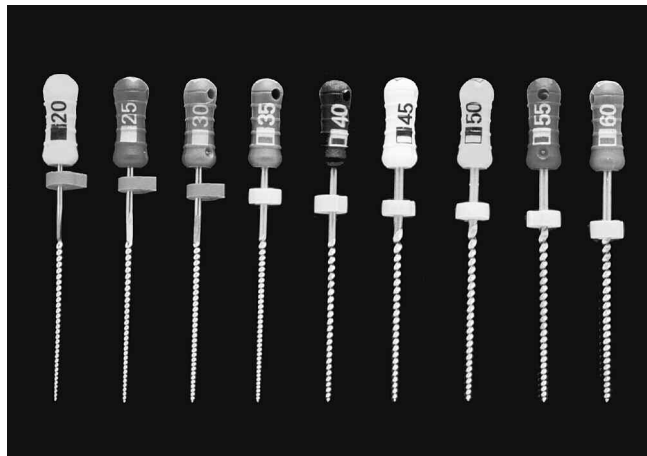
greater than 1/2 mm (*Figure 13*).<sup>2</sup> The file that snugs in at length only represents the true most apical cross-sectional diameter of the canal if each progressively larger instrument uniformly backs out of the canal in 1/2 mm intervals. Gauging and tuning *verify* “deep shape” and are an opening for cone-fit and packing in three dimensions (*Figure 14*).<sup>24</sup>

## CONCLUSION

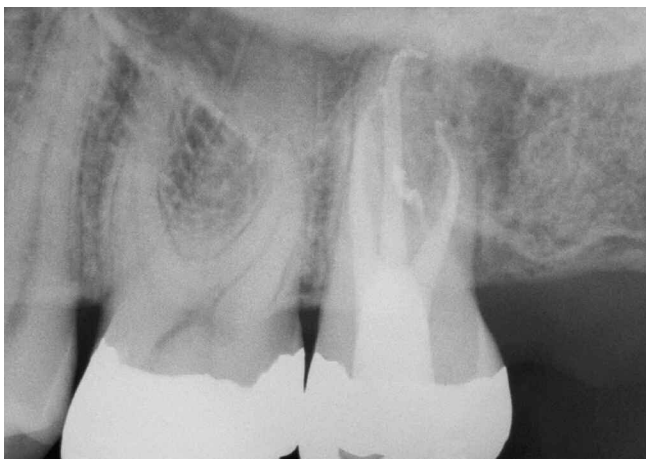
This article has described the rationale of scouting and then pre-enlarging the coronal two-thirds of the canal before scouting and finishing the apical one-third. Additionally, this article reviewed relevant information on coronal access, ISO file geometries, the use of intracanal irrigation, and the advantages of pre-enlargement. Despite all the promises of greater clinical satisfaction, predictability, and efficiency that modern endodontic systems have to offer, clinicians must still focus on the fundamentals that promote success. ▲



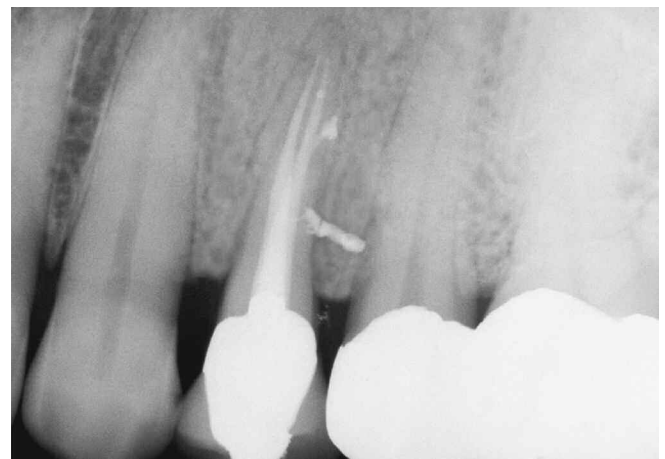*Figure 12. A graphic illustrates that gauging and tuning procedures verify deep shape and confirm a “finished” preparation.*



*Figure 13. A photograph illustrates that if the 20 file is at length, then each consecutively larger instrument uniformly steps out of the canal.*



*Figure 14a. A post-treatment film of a maxillary second molar demonstrates a furcal canal and the apical recurvature of the DB system.*



*Figure 14b. A 10-year post-treatment radiograph reveals excellent healing and confirms the importance of treating the root canal system.*

## REFERENCES

1. Levin H: Access cavities, *Dent Clin North Am* p. 701, November, 1967.
2. Schilder H: Cleaning and shaping the root canal system, *Dent Clin North Am*, 18:2, pp.269-296, 1974.
3. Brown DC, Moore BK, Brown Jr CE, Newton CW: An in vitro study of apical extrusion of sodium hypochlorite during endodontic canal preparation, *J Endod* 21:12, pp. 587-591, 1995.
4. Swindle RB, Neaverth EJ, Pantera EA, Ringle RD: Effect of coronal-radicular flaring on apical transportation, *J Endod* 17:4, pp. 147-149, 1991.
5. Serota KS, Glassman GD: Root canal preparation using engine-driven nickel-titanium rotary instruments, *Pract Periodont Aesthet Dent* 11:9, pp.1117-1122, 1999.
6. Weine FS: The use of non-ISO tapered instruments for canal flaring, *Compend Contin Educ Dent* 17:651-663, 1996.
7. Ruddle CJ: Erfolgreiche strategien bei der preparation des wurzelkanals, *Endodontie* 3:217-232. Quintessenz, Berlin, Germany, 1994.
8. Grey GC: The capabilities of sodium hypochlorite to digest organic debris from root canals with emphasis on accessory canals, *Masters Thesis*, Boston University, 1970.
9. Siqueira Jr JF, Batista M, Fraga RC, de Uzeda M: Antibacterial effects of endodontic irrigants on black-pigmented gram-negative anaerobes and facultative bacteria, *J Endod* 24:6, pp. 414-416, 1998.
10. Berutti E, Marini R: A scanning electron microscopic evaluation of the debridement capability of sodium hypochlorite at different temperatures, *J Endod* 22:9, pp. 467-470, 1996.
11. Cunningham W, Balekjian A: Effect of temperature on collagen-dissolving ability of sodium hypochlorite irrigating solution, *Oral Surg* 49:175, 1980.
12. Goldberg F, Speilberg C: The effect of EDTAC and the variations of its working time analyzed with scanning electron microscopy, *Oral Surg* 53:74, 1982.
13. Stewart GG: A scanning electron microscopic study of the cleansing effectiveness of three irrigating modalities on the tubular structure of dentin, *J Endod* 24:7, pp. 485-486, 1998.
14. Baumgartner JC, Mader CL: A scanning electron microscopic evaluation of four root canal irrigation regimens, *J Endod* 13:147, 1987.
15. Mandel E, Machtou P, Friedman S: Scanning electron microscope observation of canal cleanliness, *J Endod* 16(6):279-283, 1990.
16. McGreevey, E: Investigation of profile series 29 .04 taper rotary instruments, *Master Thesis*, Boston University, 1995.
17. Cameron JA: The synergistic relationship between ultra-sound and sodium hypochlorite: A scanning electron microscope evaluation, *J Endod* 13:541, 1987.
18. Wade AK, Walker WA, Gough RW: Smear layer removal effects on apical leakage, *J Endod* 12:21, 1986.
19. Reddy SA, Hicks ML: Apical extrusion of debris using two hand and two rotary instrumentation techniques, *J Endod* 24: 180-183, 1998.
20. Shabahang S, Goon WWY, Gluskin AH: An in vitro evaluation of Root ZX electronic apex locator, *J Endod* 22:11, pp. 616-618, 1996.
21. Burns RC, Herbranson EJ: Ch. 7, Tooth morphology and cavity preparation. In Cohen S, Burns RC, editors: *Pathways of the Pulp*, 7th ed., Mosby, St. Louis, 1998.
22. Pagavino G, Pace R, Baccetti T: A SEM study of in vivo accuracy of the Root ZX electronic apex locator, *J Endod* 24:6, pp. 438-441, 1998.
23. Ellingsen MA, Harrington GW, Hollender LG: Radiovisiography versus conventional radiography for detection of small instruments in endodontic length determination. I. In vitro evaluation, *J Endod* 21:6, pp. 326-331, 1995.
24. Ruddle CJ: Ch. 9, Obturation of the root canal system; Three-dimensional obturation: The rationale and application of warm gutta percha with vertical condensation. In Cohen S, Burns RC, editors: *Pathways of the Pulp*, pp. 243-247, 6th ed., Mosby Co., St. Louis, 1994.