

# ENDODONTIC ACCESS PREPARATION

## AN OPENING FOR SUCCESS

by Clifford J. Ruddle, DDS

Endodontic performance is enhanced when clinicians thoughtfully view different horizontally- angulated, pre-operative radiographic images, visualize minimally invasive, yet complete, treatment, then use this mental picture to guide each procedural step.<sup>1</sup> There is an old expression... "Start with the end in mind". Before initiating the access preparation, think, visualize, and plan to more effectively execute a predictably successful result.

### PRE-TREATMENT

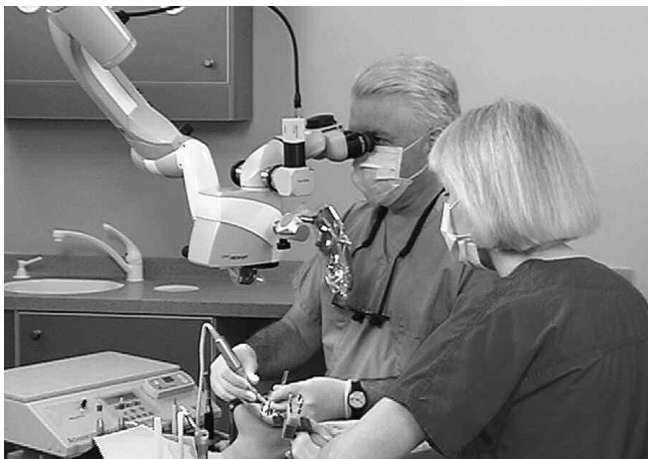Prior to endodontic treatment, an inter-disciplinary evaluation of pulpally involved teeth should be performed to ensure that optimal health is both possible and attainable. At times, it is advantageous to band and build up a tooth to facilitate subsequent endodontic procedures. Seriously broken-down teeth should be evaluated for periodontal crown lengthening procedures.<sup>2</sup> Crown lengthening facilitates endodontic isolation and enables the restorative dentist to create the ferrule effect and achieve a healthy biological width.<sup>3</sup> When indicated, crown lengthening serves to improve all phases of inter-disciplinary treatment.<sup>4</sup> Endodontically, pre-treatment procedures elevate the potential for success by improving the predictability of each ensuing step.

Another endodontic pretreatment consideration is whether to access through or remove an existing prosthetic restoration. Clinicians typically access the pulp chamber through a

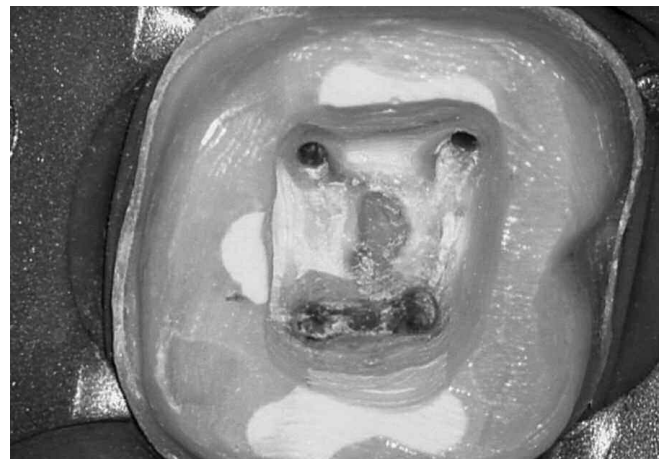restoration if it is judged to be well fitting, functionally designed, and esthetically pleasing. If the restoration fails to meet this criteria, then it is typically sacrificed. However, for a variety of reasons, it may be desirable to remove an existing restoration and preserve it in tact. The safe and successful dislodgment of any given restorative requires knowledge in all aspects of prosthetic reconstructive dentistry and the selection and use of a few removal devices.<sup>5</sup> Importantly, the clinician must consult with their patient and clearly communicate the risk versus benefit before commencing with disassembly and removal procedures.

### ISOLATION

Excellent vision in conjunction with complete isolation promotes predictably safe and successful endodontic treatment (*Figure 1*). Isolation accomplishes soft tissue retraction, protects the oral pharynx and prevents salivary leakage. Fortunately, the vast majority of all teeth can be easily and quickly isolated for endodontic treatment in a one-step procedure. To accomplish this, an appropriately sized hole is punched at a pre-determined position through a rubber dam. The rubber dam may be stretched onto a non-metallic, polymer frame and then a pre-selected clamp is mounted onto the rubber dam. A non-metallic frame allows working films to be taken without concern for inadvertent metal superimposition over the region to be viewed. The rubber dam forceps guide the jaws of the clamp over the



*Figure 1a.* The microscope (Carl Zeiss; Thornwood, New York) provides magnification, coaxial lighting, and the opportunity to perform complete treatment.



*Figure 1b.* A photo demonstrates isolation and straightline access to the orifices. Note the outline pattern, smooth axial walls, and five orifices.

crown and are released so they securely engage the tooth and do not impinge on soft tissue. An explorer may be used to lift the rubber dam off the facial and lingual wings of the clamp.

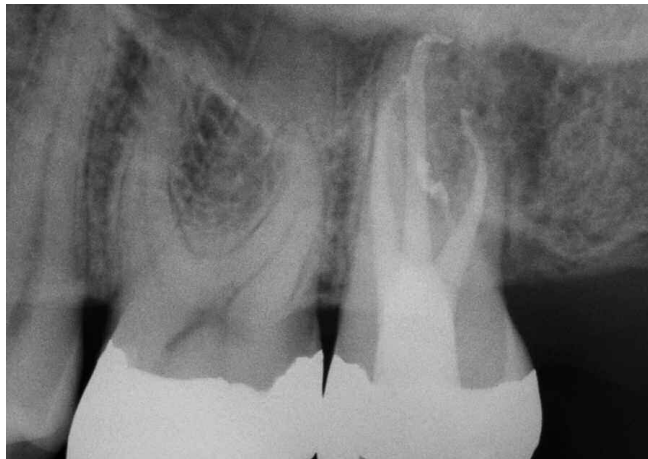
Dental floss may be used to work the rubber dam between the contact points and carry it gingivally so as to establish a dry working field. On occasion, even when the dam has been well placed, there may be a nuisance contamination leak. As such, caulking materials, such as OraSeal (*Ultradent; South Jordan, Utah*), are available to secure a fluid-tight treatment environment. Infrequently but on occasion, it may be useful to initiate an endodontic access cavity without a rubber dam to improve orientation. This may be considered when encountering heavily restored teeth, significant calcification within the pulp chamber, or when the clinical crown is not aligned with the underlying root.

### ACCESS OBJECTIVES

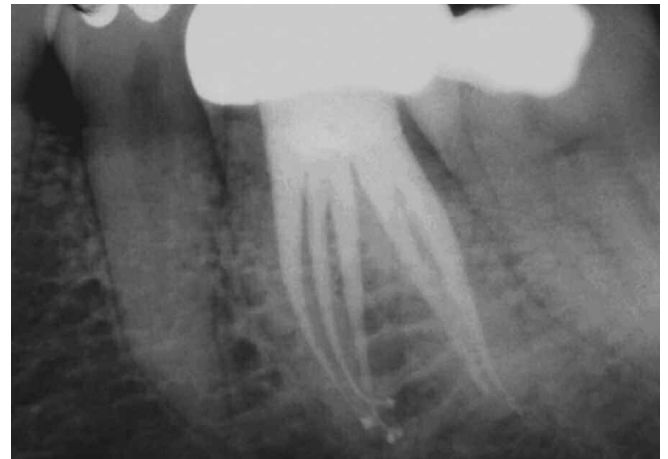The access preparation is an essential element for successful endodontics.<sup>6</sup> Preparing the endodontic access cavity is a critical step in a series of procedures that potentially leads to

the three-dimensional obturation of the root canal system (*Figure 2*). Access cavities should be cut so the pulpal roof, including all overlying dentin, is removed. The size of the access cavity is primarily influenced by the anatomical position of the orifice(s). The axial walls are extended laterally such that the orifice(s) is just within this outline form. When required, access preparations are further expanded to eliminate any other restrictive interference that could compromise any aspect of ensuing treatment.<sup>7</sup>

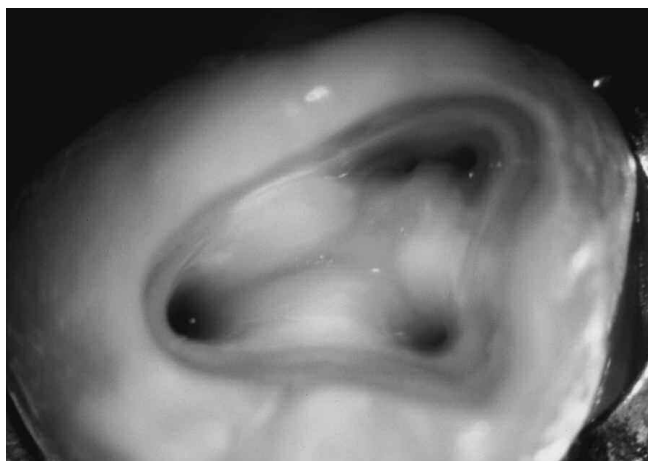Endodontic access cavities should parallel the principle of restorative dentistry. Dentists performing prosthetic dentistry readily appreciate the importance of being able to withdraw a wax pattern from a stone or copper dye without distorting the wax. Endodontically, access objectives are confirmed when all the orifices of a furcated tooth can be visualized without moving the mouth mirror. Cleaning and shaping potentials are dramatically improved when instruments conveniently pass through the occlusal opening, effortlessly slide down smooth axial walls and are easily inserted into a preflared orifice (*Figure 3*). Spacious access cavities are an opening for canal preparation.<sup>8-10</sup>



*Figure 2a.* This post-treatment film demonstrates straightline access, apical curvature and recurvature of the P and DB systems, and a treated furcal canal.



*Figure 2b.* This post-treatment film illustrates straightline access and that five canals were identified, shaped, and filled.



*Figure 3.* This photo demonstrates straightline access, smoothly prepared and divergent axial walls, and that the preflared orifices are just within this outline form.

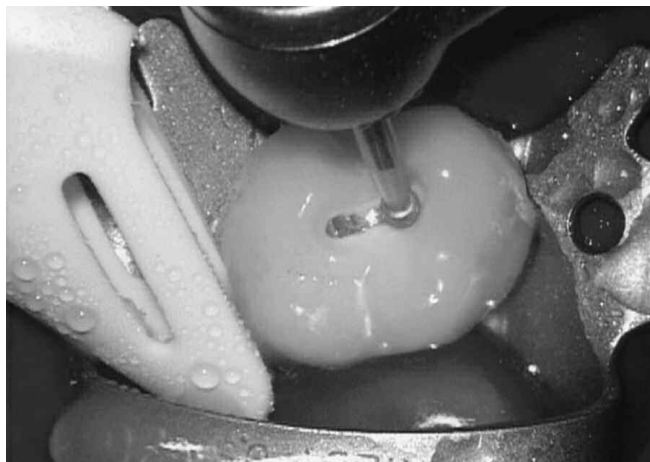
## ACCESS TECHNIQUES

Having knowledge regarding the external and internal anatomy of human teeth is fundamental and serves to prepare the clinician to more successfully treat endodontically involved teeth.<sup>11</sup> From experience, it is best to initially prepare the size of the access window about 80% of what the final outline form will ultimately expand and become. Initially preparing a close to optimal opening improves vision as the preparation moves deeper into the tooth. Once the pulpal roof has been removed, then the position of the orifice(s) may be identified on the pulpal floor. With anatomical orientation, the position of the axial walls may be adjusted, and the access preparation fully expanded and finished accordingly.<sup>12</sup>

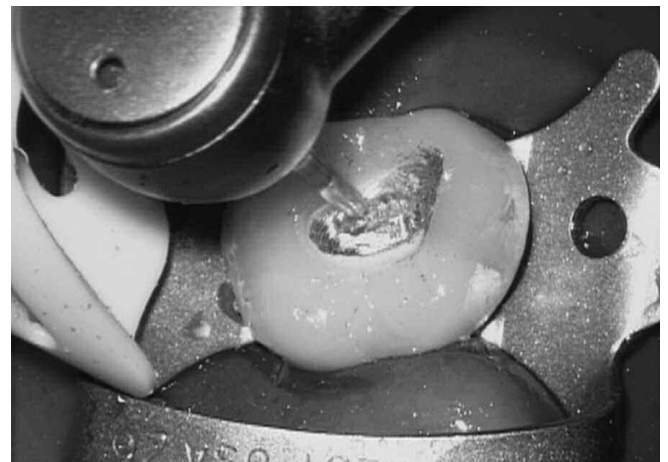
Depending on the material comprising the clinical crown, the appropriate bur is selected to initiate treatment (*Figure 4a*). Subsequent restorative materials, at times, require a different bur to improve efficiency while reducing unwanted vibration (*Figure 4b*). Like a painter painting a canvas, the clinician

moves the handpiece utilizing a light brushing motion. The bur is swept mesial to distal and facial to lingual, as the access preparation is extended toward the pulp chamber. A light brushing motion with a new sharp bur reduces friction and related heat, and affords more control when progressively carrying the access preparation pulpally. From a patient's perspective, brush cutting versus drilling dentin promotes peaceful endodontics, especially when accessing pulpitic teeth. The access cavity is continued until the pulpal roof is penetrated. Upon entry, an appropriately sized surgical length carbide round bur is placed inside the chamber and is repetitively dragged occlusally until the entire pulpal roof has been removed (*Figure 4c*).

After completely de-roofing the pulp chamber and identifying the orifice(s), a surgical length tapered diamond (*Brasseler; Savannah, Georgia*) may be used to flare, flatten, and finish the axial walls (*Figure 4d*). The axial walls are tapered so they diverge from the pulpal floor towards the occlusal surface. Smooth, flat, and tapered axial walls improve the refraction of light and, hence, vision. Tapered diamonds serve to create



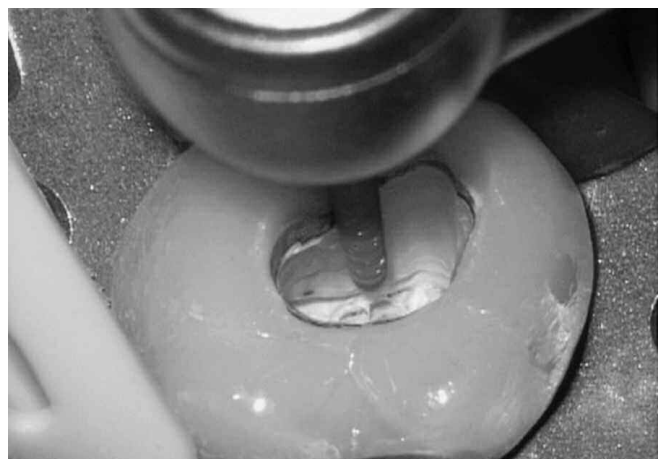
*Figure 4a.* A round bur diamond in conjunction with a water coolant is utilized to initiate access through a porcelain fused to metal crown.



*Figure 4b.* This transmetal bur has a saw-tooth blade configuration which may be used to efficiently cut a window through metal restoratives.



*Figure 4c.* A surgical length carbide round bur provides a line-of-site for safely and progressively extending the access preparation and de-roofing the pulp chamber.

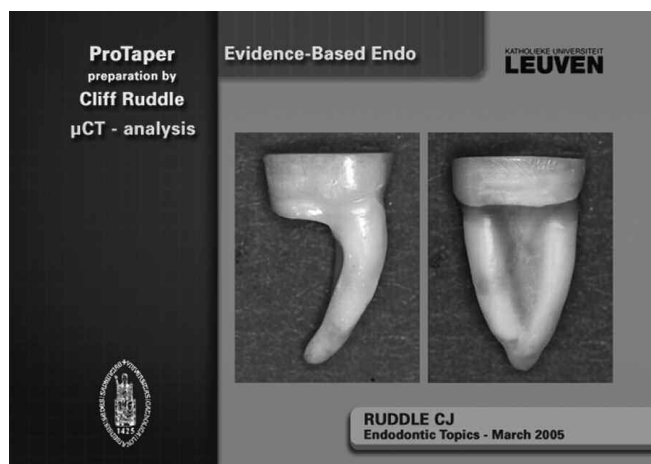


*Figure 4d.* A surgical length tapered diamond provides continuous vision and may be utilized to smooth the axial walls and finish the access preparation.

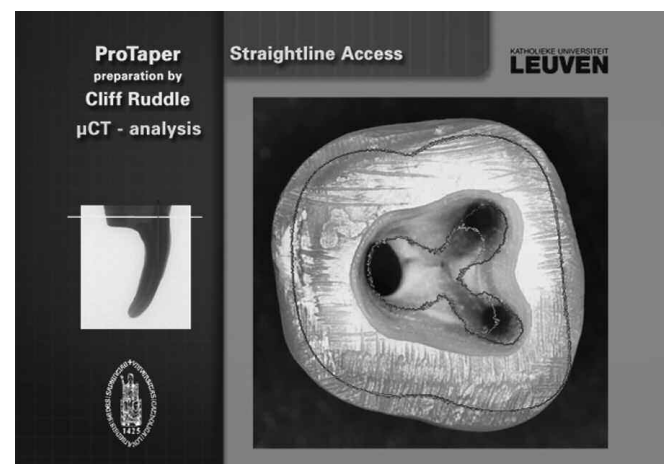straightline access to each orifice. When radicular space is available, an explorer may be placed into an orifice to determine the entry angle of any given canal relative to the long axis of the tooth. When radicular space is more restrictive, a small-sized hand file can generally be inserted into the coronal-most aspect of a canal to judge the entry angle of the canal relative to the long axis of the tooth. Placing a small-sized hand file will disclose the existence of any irregularities or interferences that could pose a nuisance during subsequent cleaning and shaping procedures.

In the author's opinion, Gates Glidden (GG) burs, sizes 1-4 (*Dentsply Maillefer; Tulsa, Oklahoma*), are the rotary cutting burs of choice to preflare the orifice(s), intentionally relocate the coronal aspect of a canal away from external root concavities, and remove internal triangles of dentin. This procedure establishes a reproducible opening to any canal, facilitating subsequent instrumentation. Research has shown that a single X-Gates, comprised of GG sizes 1-4, (*Dentsply Maillefer; Ballaigues, Switzerland*) or a few GGs

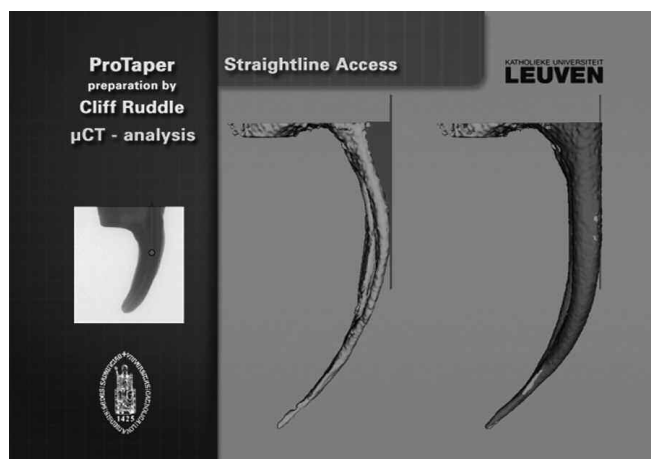
can be safely used with a "brushing action" and at a "low speed" of about 750 rpm to selectively cut dentin and produce a final preparation that is centered within the circumferential dimensions of the root (*Figure 5*). The size of the GG initially selected is dependent on the size of the orifice. As a guideline, select the largest GG that can passively fit into any given orifice, and then proceed from the big to smaller sizes. Excluding teeth that exhibit calcification within the pulp chamber, most orifices can typically accommodate a GG-4. The selected and non-rotating GG is placed just within the orifice and, upon activation, the head of the hand-piece is moved in a circular motion above the GG/orifice pivot point. The belly of the GG serves to flare and blend the orifice into the adjacent axial wall. A preflared orifice produces a smooth, flowing funnel to easily facilitate the subsequent placement of small-sized hand files. In smaller diameter canals, typically associated with the buccal roots of maxillary molars or the mesial roots of mandibular molars, limit the use of the GG-4 so that its flame-shaped active portion is no more than one bud depth below the orifice.



*Figure 5a.* A  $\mu$ CT image of a mandibular molar demonstrates the distal root has been removed and that the mesial root has a furcal side concavity.



*Figure 5b.* The green outline pattern seen in this  $\mu$ CT image demonstrates the original anatomical position of the orifices. The red outline pattern shows that the orifices have been intentionally relocated away from furcal danger.



*Figure 5c.* This  $\mu$ CT image shows before (green) and after (red) shaping procedures. The red triangle of dentin (left image) was removed with GGs (right image).

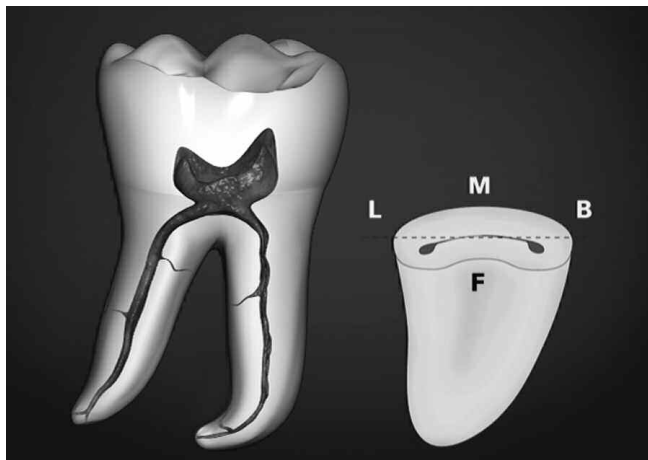
(Figures 5a-5c courtesy of Dr Lars Bergmans and BIOMAT Research Cluster, Catholic University, Leuven, Belgium).

In non-calcified teeth, GGs are strategically used starting with the bigger and sequentially proceeding through the smaller sizes. As such, if the orifice was initially preflared with a GG-4, then proceed to a GG-3. Since the GG-3 is smaller than the GG-4, its loose fit will enable the clinician to use its belly to selectively brush and cut dentin on the outstroke. The goal of this specific procedure is to improve radicular access by intentionally relocating the coronal most aspect of the canal away from external root concavities and toward the greatest bulk of dentin. Fortuitously, utilizing GGs with a brushing action allows the clinician to more fully address root canal cross-sections that are irregularly-shaped anatomically. Following the use of the GG-3, sequentially proceed to the smaller sized GG-2, then to the GG-1. It is perfectly normal to break the shafts of these smaller sized GGs when they are correctly and deliberately used like a brush. Breaking the shaft of a GG is clinically a non-issue, as the active portion is completely loose in the canal during use.

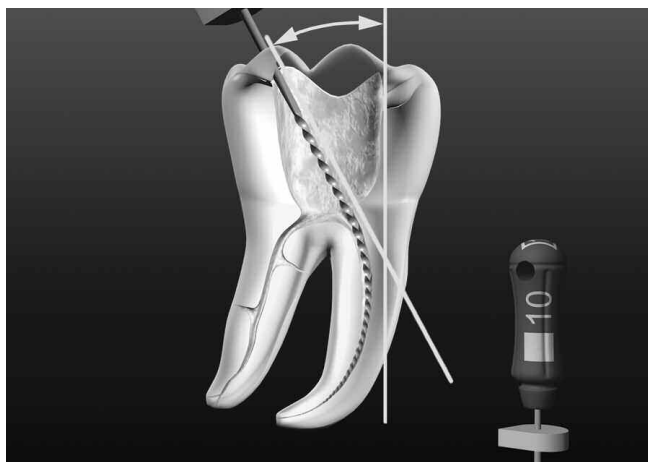
Preflaring and intentionally relocating the coronal most aspect of the canal is a strategic decision that will influence all sub-

sequent steps of treatment. As a single example, the coronal aspects of mesial canals of mandibular molars are rarely anatomically centered within a root (*Figure 6*). Using NiTi rotary files to uniformly expand the coronal portion of a canal outward from its original anatomical position results in preparations that tend to move toward furcal danger. Preparations which are not centered within any given root are predisposed to root thinning, radicular fractures, and strip perforations.<sup>5,13</sup>

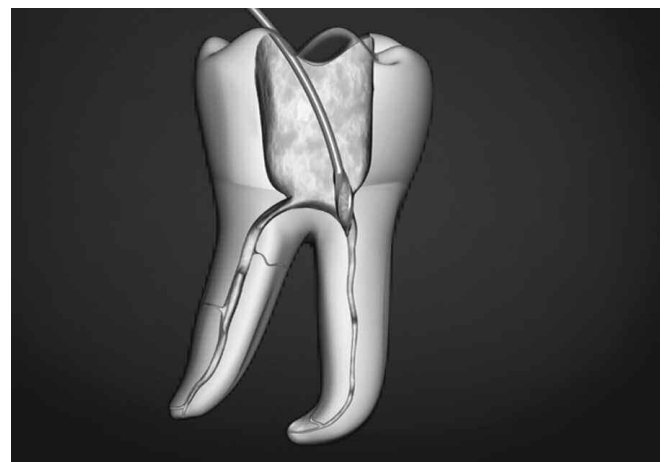Preflaring the coronal one-third of a canal is especially important in the clinical situation where the handle of the initially placed file is not aligned with the long axis of a tooth. Clinicians can observe the handle position of the smaller sized instruments to see if they are upright and paralleling the long axis of the tooth or skewed off-axis. When the handle of the file is upright, or “ON” the long axis of the tooth then the clinician is able to confirm both coronal and radicular straightline access. However, when the handle of the initial instrument is “OFF” the long axis of the tooth, then recognize the triangle of dentin must be removed to upright the file handle and position it ON axis (*Figure 7*).<sup>7</sup>



*Figure 6.* A cross-section through the mesial root illustrates that the orifices are generally positioned anatomically closer toward the furcal side of the root.



*Figure 7a.* The handle of a small-sized hand file is frequently “OFF” axis in furcated teeth due to an internal triangle of dentin.



*Figure 7b.* The shaft of a GG is arced so the bud will cut and intentionally move the coronal most aspect of a canal away from furcal danger.

Scouter files confirm the presence or absence of straightline coronal and radicular access. Complete straightline endodontic access simplifies all subsequent instrumentation procedures while virtually eliminating many cleaning and shaping frustrations.<sup>5</sup> Following the use of GGs, the access cavity is almost routinely adjusted and subtly refined with a surgical length tapered diamond to fulfill the mechanical objectives for straightline access and to promote all ensuing treatment steps. The access preparation should be thought of as a progressive procedure that frequently requires adjustment during canal preparation procedures.

## ACCESS REFINEMENT PROCEDURES

The challenge of every dentist initiating endodontic treatment is to safely prepare the access cavity and to definitively identify the orifice(s). Today, this procedure can be more predictably performed due to better vision, advancements in ultrasonic instrument designs, and improved clinical techniques. Importantly, ultrasonically driven procedures remove the bulky head of a traditional handpiece, providing an unsurpassed line-of-sight into the operating field. Specifically, the new SINE ultrasonic instruments (*Advanced Endodontics; Santa Barbara, CA*), provide an important breakthrough for access refinement procedures (*Figure 8a*). This 6-instrument set is available in 18 mm lengths, offers unique tip configurations, and has a contra-angled design for better access. Additionally, the SINE ultrasonic instruments have water ports, as well as a unique and corrosion-resistant double composite diamond coating. Remarkably, this instrument line has nearly 3x more diamond particles per unit area than other popular tips on the market today (*Figure 8b*). A denser coating equates to a safer and more efficient cutting action. The SINE ultrasonic instruments are strategically designed




**Figure 8a.** The SINE ultrasonic instruments feature innovative tip configurations, a unique diamond coating, optional water delivery system, and a contra-angle design for better access and visibility.

to remove stones, trough for hidden orifices, chase calcified canals, refine and finish axial walls and line angles, eliminate triangles of dentin, flare orifices, cut-off the coronal aspect of a carrier-based obturator, and clean the pulp chamber post-treatment in preparation for restorative dentistry (*Figure 9*).


The specific SINE instrument chosen is based on the tip configuration required to effectively perform any given procedure. The SINE tips should be used with a light brush-cutting motion at the lowest power setting that will efficiently accomplish the clinical task. The SINE ultrasonic instruments have been designed and tuned to work optimally on the new piezoelectric ultrasonic generators that more safely regulate tip movement. The P5 (*Dentsply Tulsa Dental Specialties; Tulsa, Oklahoma*), P5 Newtron (*Acteon Group; Merignac, France*), or NSK (*Brasseler; Savannah, Georgia*) represent state-of-the-art generators that provide the technology to optimize ultrasonic instrumentation procedures. To avoid thermal injury, when performing certain ultrasonic procedures requiring higher energy levels conducted over longer intervals of time, a water mist should be used to provide a coolant.<sup>14</sup>

## CONCLUSION

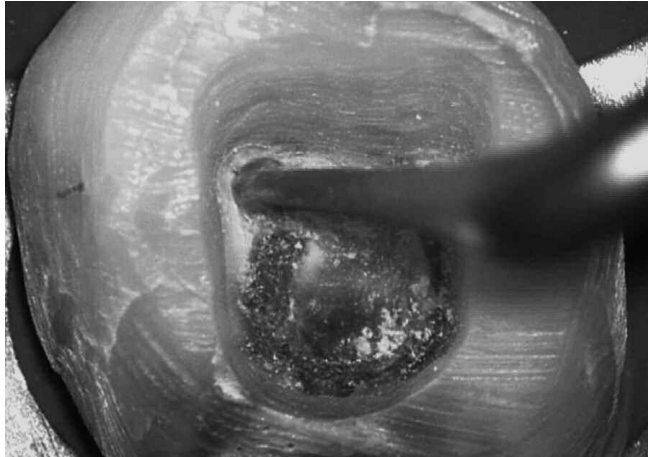
This article has described concepts, strategies, and techniques for creating predictably successful endodontic access preparations. It could be said that preparing an access preparation is a game, and as such, can be played at various levels of skill, producing a range of results. The endodontic access preparation influences all ensuing treatment steps and provides the opening for shaping canals, cleaning root canal systems, and three-dimensional obturation. Visualizing and executing great play moves each clinician toward mastery and winning the inner game of endodontics. ▲



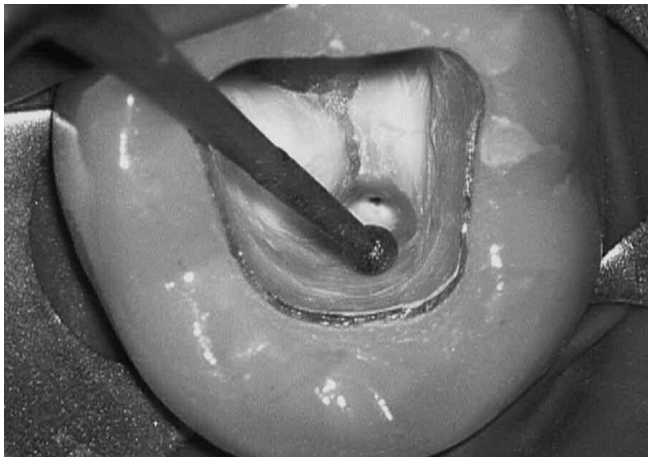
**Figure 8b.** An SEM image reveals why the SINE ultrasonic instruments are super-efficient and provide such a smooth cutting action. Note there are nearly 3 times more diamond particles per unit area as compared to other competitive lines.



*Figure 9a. A SINE instrument with a pointed or rounded tip may be used to track and explore grooves, trough for hard-to-find orifices, and uncover hidden canals.*



*Figure 9b. A SINE instrument with a football-shaped tip may be used for de-roofing dentin, flaring and relocating an orifice away from furcal danger, and smoothly blending the orifice into the line angle.*



*Figure 9c. A SINE instrument with a ball-shaped tip may be used for many tasks such as eliminating a pulp stone and cleaning the pulp chamber post treatment.*

## REFERENCES

1. Burns RC, Herbranson EJ: Ch. 7: Tooth morphology and cavity preparation. *Pathways of the Pulp*, 7th ed., Cohen and Burns, Mosby, St. Louis, 1998.
2. Nevins M, Mellonig JT (ed.): *Periodontal Therapy, Clinical Approaches and Evidence of Success*, Quintessence Publishing Company, Chicago, 1998.
3. Lenchner NH: Restoring endodontically treated teeth: ferrule effect and biologic width, *Pract Periodont Aesth Dent* 1:19, 1989.
4. Sorensen JA, Engelman MJ: Ferrule design and fracture resistance of endodontically treated teeth, *J Prosthet Dent* 63:529, 1990.
5. Ruddle CJ: Ch. 25, Nonsurgical endodontic retreatment. In *Pathways of the Pulp*, 8th ed., Cohen S, Burns RC, eds., St. Louis: Mosby, pp. 875-929, 2002.
6. Levin H: Access cavities. *Dent Clin North Am* 11:701, November, 1967.
7. Ruddle CJ: Ch. 8, Cleaning and shaping root canal systems. In *Pathways of the Pulp*, 8th ed., Cohen S, Burns RC, eds. St. Louis: Mosby, pp. 231-291, 2002.
8. Machtou P: Ch. 8, La cavité d'accès. In *Endodontie - guide clinique*, Pierre Machtou, ed., Paris: Editions CdP, pp. 125-137, 1993.
9. Ruddle CJ: The protaper technique. *Endodontic Topics* 10:187-190, 2005.
10. Schilder H: Cleaning and shaping the root canal system. *Dent Clin North Am* 18(2):269, 1974.
11. Brown WP, Herbranson EJ: Brown and Herbranson Imaging, Portola Valley, CA: www.toothatlas.com, 2005.
12. Ruddle CJ: *Ruddle on Clean•Shape•Pack*, 2-part video series / DVD. Studio 2050, producer, Santa Barbara, California: Advanced Endodontics, 2002.
13. Ruddle CJ: *Ruddle on Retreatment*, 4-part DVD series. James Lowe Productions / Studio 2050, producers, Santa Barbara, California: Advanced Endodontics, 2004.
14. Gluskin AH, Ruddle CJ, Zinman EJ: Thermal injury through intraradicular heat transfer using ultrasonic devices, *J Am Dent Assoc* 136:9, pp. 1286-1293, 2005.