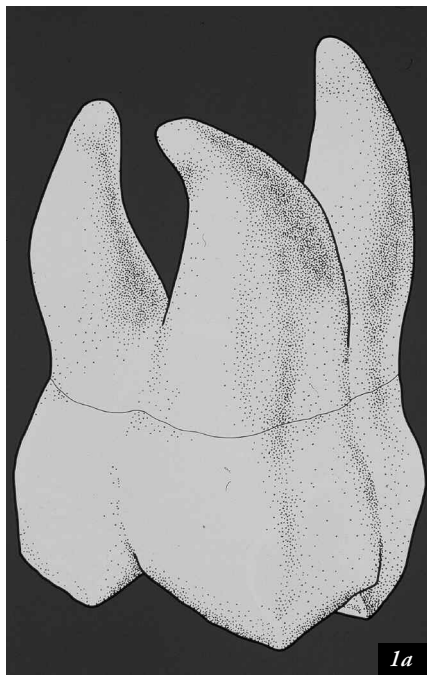


# MB<sup>2</sup> ROOT CANAL SYSTEMS IN MAXILLARY FIRST MOLARS

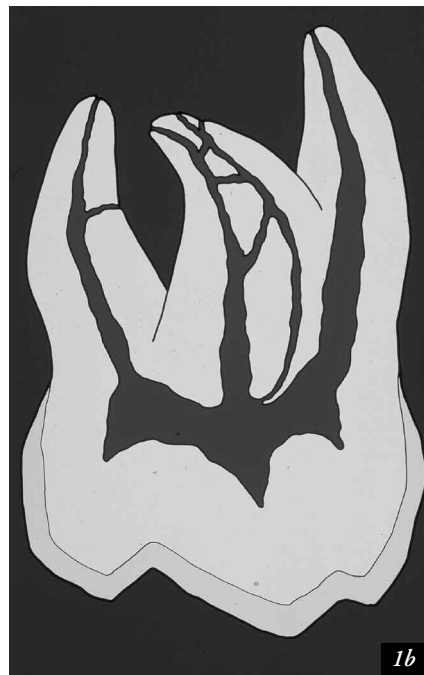
by Clifford J. Ruddle, D.D.S.

The maxillary first molar has fascinated researchers and clinicians for a variety of reasons (*Figures 1a, 1b*).<sup>1</sup> This particular tooth has the largest volume and has generated more research than any other tooth in the mouth.<sup>2</sup> Endodontically, it is one of the most misunderstood teeth, and presents a variety of considerations for the treating practitioner.

Clinically, the mesiobuccal root (MBRT) contains a second root canal system, which can be identified and treated more than 70 percent of the time (*Figures 2a, 2b*).<sup>3,4</sup> Histological evidence, however, suggests the presence of two MB systems approaching a remarkable 100 percent.<sup>5</sup> These systems communicate frequently along their lengths, and terminate



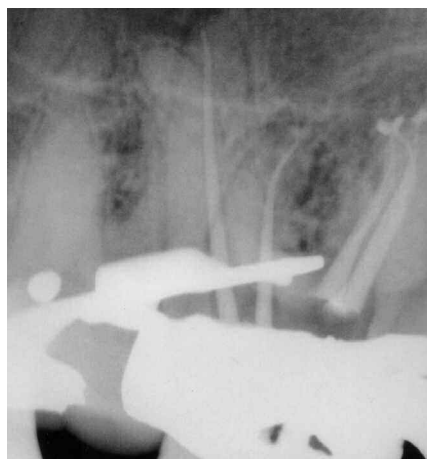1a



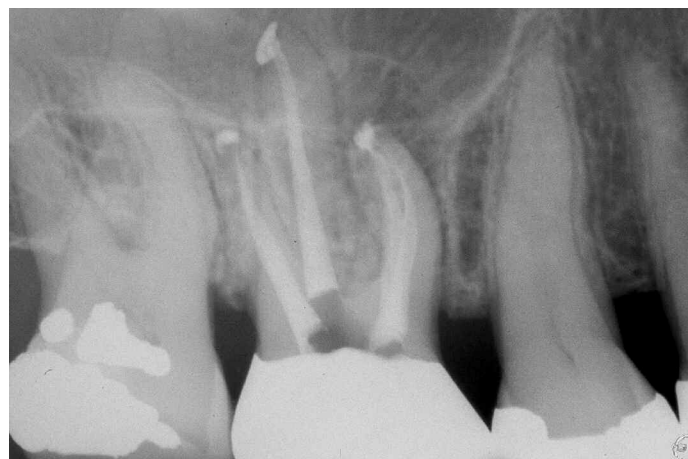
1b

*Figure 1a.* A mesial-oblique view reveals the buccal to lingual breadth of the mesiobuccal root. Anticipate and appreciate the inner root canal system anatomy.

*Figure 1b.* Research and clinical studies demonstrate the MB root holds two canals more than 70 percent of the time with frequent anastomosing between systems.



*Figure 2a.* A disto-oblique angle shows the packed MB<sup>1</sup> and MB<sup>2</sup> systems with multiple apical portals of exit and cone fit in the DB and P canals.



*Figure 2b.* The more conventional straight-on angled film reveals the pack. Off-angled radiographs give an important and different perspective of treatment.

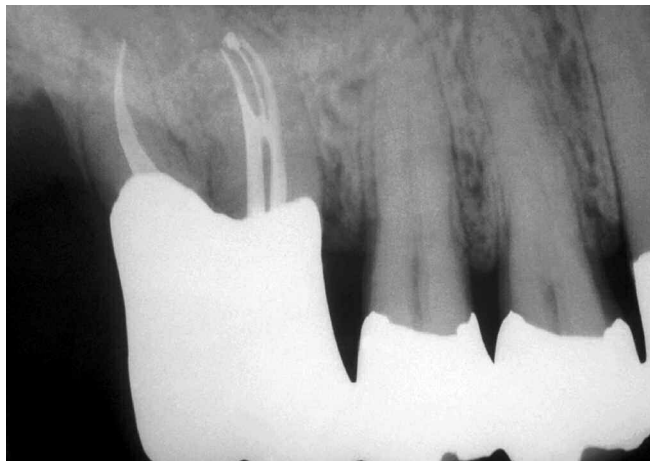separately in two or more portals of exit greater than 58 percent of the time (*Figures 2, 3*).<sup>3,4</sup> The thorough clinician must, therefore, assume that all maxillary first molars have four canals until proven otherwise. Infrequently, but on occasion, maxillary first molars can exhibit extra canals in their other roots (*Figures 4, 5*). It is essential, therefore, to completely de-roof the pulp chamber, expand the access cavity's axial walls, and carefully explore the pulpal floor for aberrant orifices/systems (*Figures 6a, 6b*).

## TERMINOLOGY

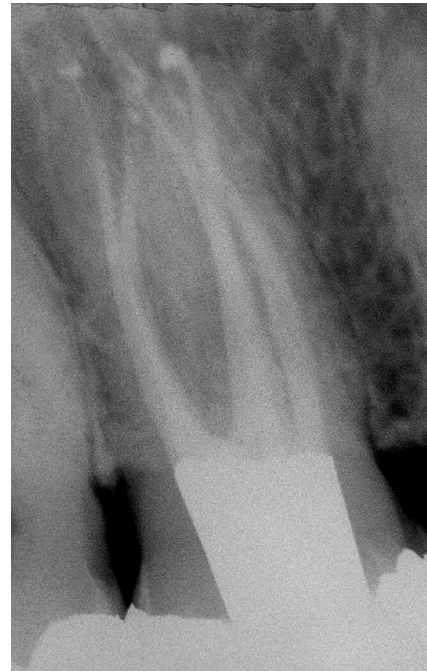Looking into the access preparation toward the mesiobuccal axial wall, the larger, more buccally positioned, more readily identifiable orifice/system is called the MB<sup>1</sup>. The smaller, more palatally positioned, most frequently overlooked orifice/system is called the MB<sup>2</sup> (*Figures 7, 8*).

## LOCATION

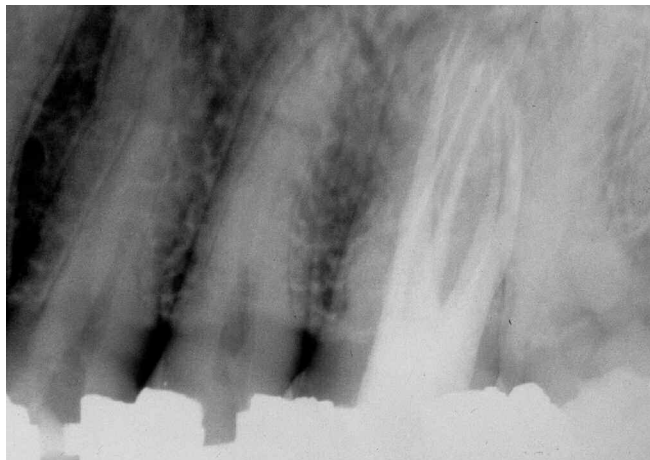
Clinical experience and histological studies reveal that the MB<sup>2</sup> is commonly located within the developmental groove on an approximate line between the MB<sup>1</sup> and palatal orifices (*Figures 9a, 9b*). To assist locating the MB<sup>2</sup> system, the clinician should be prepared to extend the access cavity mesially at the expense of the mesial marginal ridge (MMR). It is useful to know that all orifices originate on the pulpal floor, and lie approximately on the same plane, and the clinician may need to move the mesial axial wall of the access mesially rather than chase apically into the pulpal floor to identify the MB<sup>2</sup>. The MB<sup>2</sup> orifice may be displaced lingually at times, and actually lie far from the MB<sup>1</sup> orifice and closer to the palatal orifice. This latter situation emphasizes the importance of creating complete access and totally eliminating the pulpal roof.



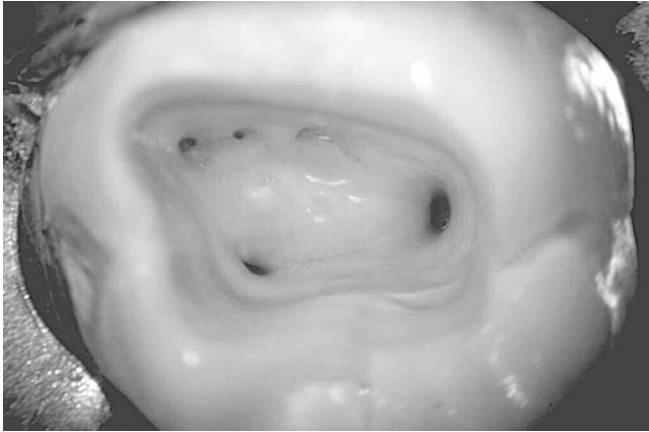*Figure 3. The most posterior abutment has had a palatal root amputation, and the buccal roots were treated endodontically. Note that the MBRT contains exciting and complex root canal system anatomy.*



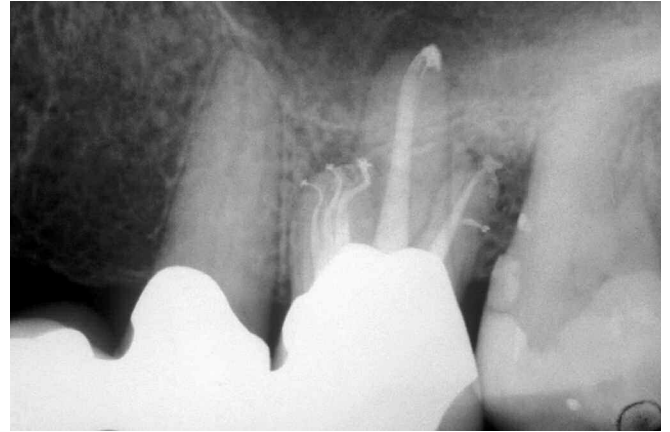
*Figure 4. A maxillary first molar with five canals. Two systems in each of the MB and DB roots and one palatal canal.*



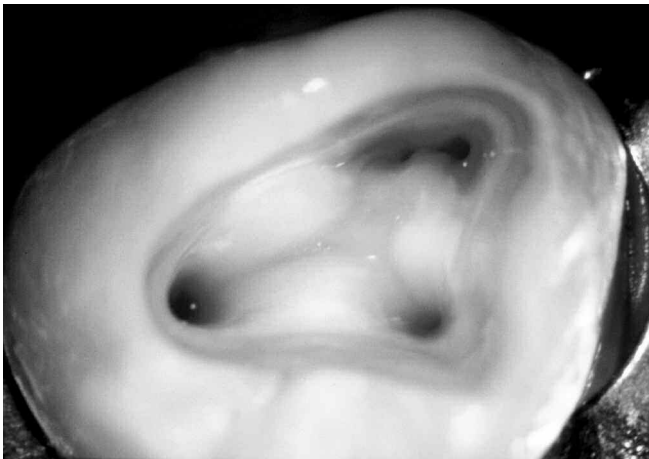
*Figure 5. A maxillary first molar with six canals. Two systems in each of the three roots. Note the anastomosing between the MB<sup>1</sup> and MB<sup>2</sup>.*



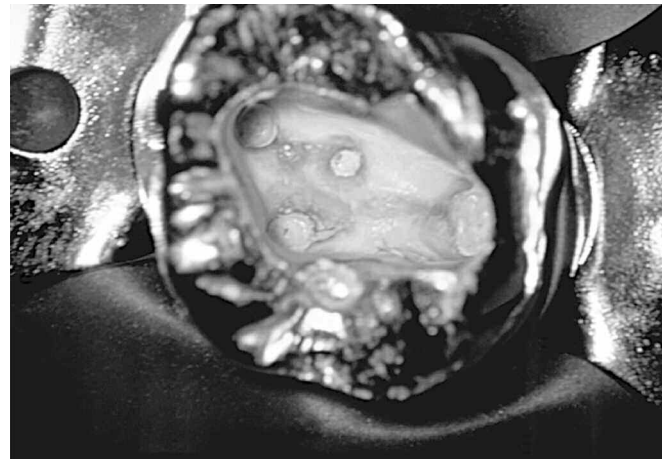
*Figure 6a.* The operating microscope offers excellent documentation and vision at 15X. Note the MB<sup>1</sup>, MB<sup>2</sup>, and MB<sup>3</sup> orifices in the maxillary first molar.



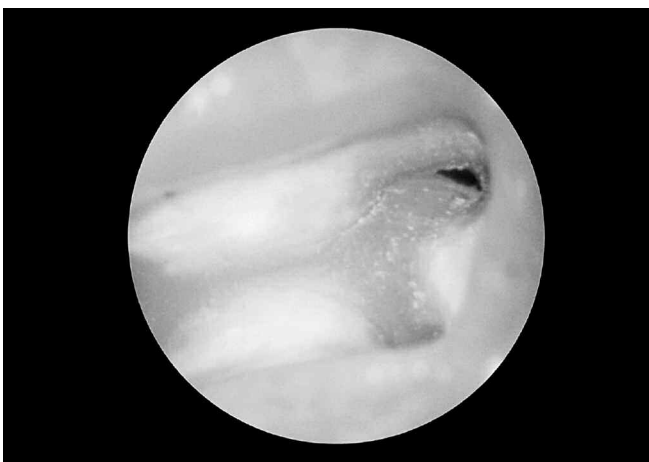
*Figure 6b.* The pack reveals three MB systems with significant apical one-third recurvature, palatal bifidity, and a significant lateral canal off the DB system.



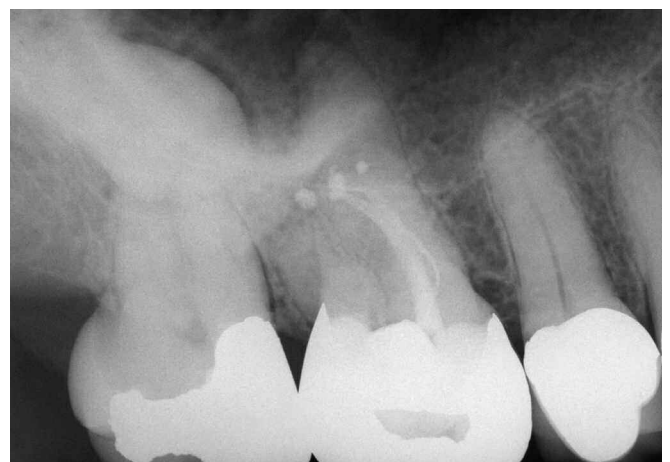*Figure 7.* Complete access reveals a larger, more buccally positioned MB<sup>1</sup> orifice. The MB<sup>2</sup> often communicates with the MB<sup>1</sup> via a narrow isthmus.



*Figure 8.* A post-pack photograph reveals straight-line access to all orifices. The MB<sup>2</sup> is smaller and quite palatal to the larger, more buccal MB<sup>1</sup> orifice/system.



*Figure 9a.* A photograph taken at 12X reveals the MB<sup>1</sup> and related groove. A dentinal shelf frequently hides the underlying MB<sup>2</sup> orifice system.

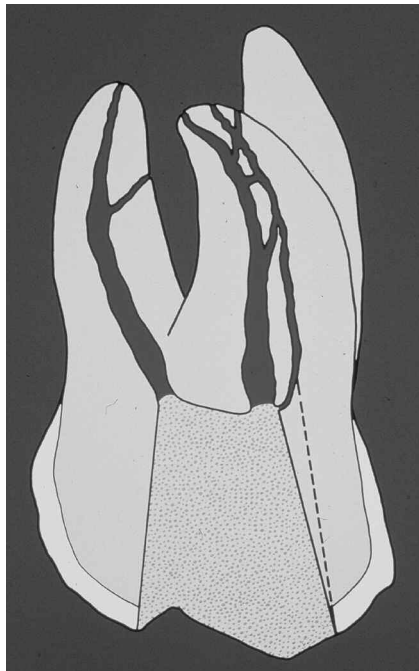


*Figure 9b.* Endodontic treatment in progress. Three-dimensional obturation of the MB root reveals the outer loop re-anastomosing and multiple apical portals of exit.

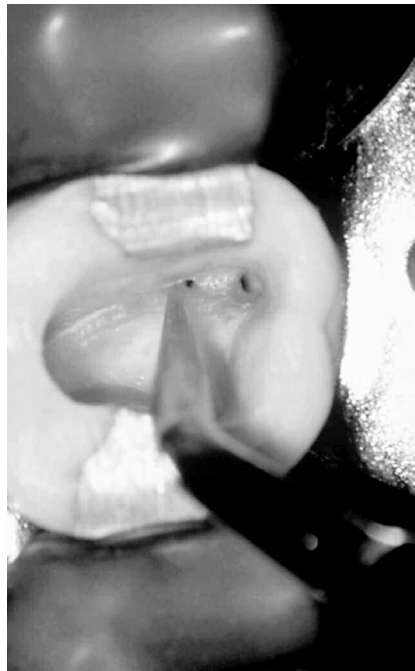## IDENTIFICATION

There are a number of strategies that, when used in combination, greatly increase the identification of the MB<sup>2</sup> orifice/system. The more useful concepts/techniques include the following:

1. Philosophically believing the MB<sup>2</sup> is present motivates the clinician to actually be in action to find it.<sup>1-5</sup>
2. Complete access is absolutely necessary if MB<sup>2</sup> orifices/systems will be routinely identified. The access cavity needs to be completely deroofed and expanded mesially at the expense of the MMR in the groove/orifice region. "Finishing" the access cavity eliminates a shelf of overlying dentin, exposing the MB<sup>2</sup> orifice (**Figures 6-10**).
3. Firmly probe the isthmus or developmental groove with an explorer. The clinician's fingers should blanch, and the thumb from the off hand can assist in directing forces down the long axis of the explorer to punch through a thin roof of overlying dentin. Explorers are often discarded as tips collapse, much like when the smallest files are discarded during cleaning and shaping procedures.
4. Magnification is a critically essential element to consistently identify the MB<sup>2</sup> orifices. Clinicians should wear loupes, magnification glasses, or ideally, use the dental operating microscope to visualize pulpal floor anatomy and extra orifices. Microscopes afford unsurpassed lighting, magnification, optics, ergonomics, and potential to add a variety of additional accessories, including documentation packages.
5. Lighting parallels magnification in importance, and is enhanced with fiberoptic handpieces and straight wand lights held by the dental assistant directed buccal to lingual either above or below the rubber dam. Operating head lamps beam a column of light that is coaxial with the line of sight which significantly enhances vision. The operating microscope affords extraordinary light and magnification, giving the clinician unsurpassed vision, control, and confidence in identifying or chasing extra canals (**Figures 6-9**).
6. Use of the Satelec P5 piezoelectric ultrasonic unit (*Dentsply Tulsa Dental*), as well as specially designed tips (*ProUltra Endo Tips, Dentsply Tulsa Dental*) has provided a phenomenal breakthrough for safely sculpting away secondary dentin overlying the MB<sup>2</sup> orifice. Small, specifically angled tips can easily be inserted into the handpiece, greatly enhancing control during light-touch brush-cutting action (**Figure 11**).
7. Following complete access, a 1 percent solution of Methylene Blue dye can be irrigated into the pulpal chamber, then flushed out. Dye will roadmap the anatomy by penetrating into orifices, developmental grooves, and/or fractures, enhancing diagnosis and treatment.
8. The "champagne test" is conducted within the access cavity filled with a 5.25 percent solution of sodium hypochlorite. The clinician can frequently visualize bubbles emanating from organic tissue hidden within fins, and extra orifices rising toward the occlusal table.



**Figure 10.** The dotted lines graphically represent how the access cavity must be expanded to remove the shelf of overlying dentin hiding the MB<sup>2</sup> canal.



**Figure 11.** After establishing straightline access, an appropriately selected ultrasonic tip easily, rapidly, and safely eliminated the dentine shelf and exposes the more palatal MB<sup>2</sup> orifice.

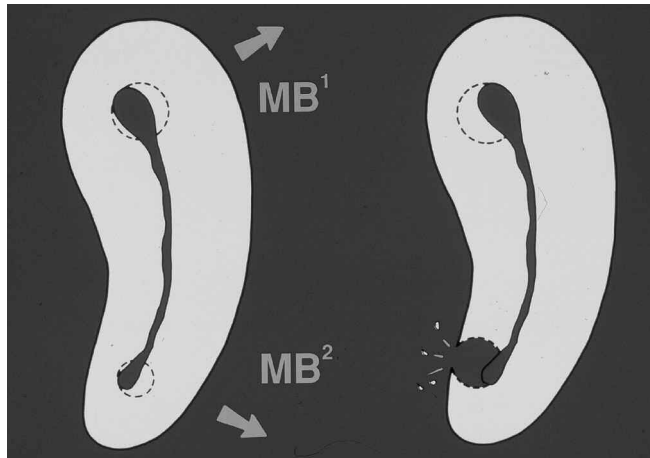
9. Multiple obliquely angled radiographs preoperatively begin to demonstrate the buccal to lingual dimensions of the MBRT. The broader the root, the greater the likelihood of a second canal system. Off-angled working films with a file or gutta percha in the MB<sup>1</sup> canal will also either reveal equal amounts of tooth structure on each side of the file, i.e., symmetry, or the file skewed off the longitudinal central axis of the root, strongly suggesting the presence of a second canal (*Figure 2a*).
10. Bleeding emanating away from the previously cleaned and shaped MB<sup>1</sup> orifice/system and/or patient discomfort when placing files within the already extirpated MB<sup>1</sup> are a sign of residual tissue, and possible inter-canal communication, suggesting a second canal harboring pulpal tissue.
11. Anatomical familiarity, experience, and cataloguing creates a mental library of countless cases, and assists the clinician in mapping and providing successful treatment.
12. Commitment, perseverance, dedication, and mental toughness are essential elements for complete treatment.

## TREATMENT

Recall that the MBRT has a concavity on its furcal side, and its mesial to distal dimensions are smaller palatally than buccally. The access cavity must be expanded toward the

mesiobuccal line angle and mesiomarginal ridge areas, respectively, to provide optimal straightline access to the MB<sup>1</sup> and MB<sup>2</sup> root canal systems. Proper access will free instruments from coronal tooth structure or restorative interferences. During early coronal enlargement of MB<sup>1</sup> and MB<sup>2</sup> root canals, small gates gliddens are selected and run at a slow rpm, and their shaft intentionally arced away from furcal danger while brush-cutting out of the canal. This strategy redirects and moves the preparations mesially and to the greatest bulk of dentin while concomitantly preserving maximum remaining furcal tooth structure (*Figure 12, left*). When identified, the optimally cleaned and shaped MB<sup>2</sup> must be prepared more conservatively than the MB<sup>1</sup> system due to root morphology (*Figure 12, left*). Anatomically, the MB<sup>1</sup>, MB<sup>2</sup>, and related isthmus aspects of the root canal system lie closer to the external furcal side concavity, which predisposes this root to furcal thinning during cleaning and shaping procedures, increasing the potential for future fractures and/or strip perforations (*Figure 12, right*).

An endodontic referral may be prudent prior to complications or to enhance restorative dentistry. The general dentist and specialist should, therefore, work together to maximize the excellence of healthcare delivery, particularly in strategic teeth that might not be amenable to nonsurgical or surgical retreatment (*Figures 3, 6*). ▲



*Figure 12. Two coronal cross-sectional views of the MBRT. Left Graphic: Preparation procedures need to redirect the MB<sup>1</sup> and MB<sup>2</sup> canals away from furcal danger. Right Graphic: Incomplete access and improper canal preparation procedures predispose to root thinning or perforation.*

## REFERENCES

1. Hess W, Zürcher E: The anatomy of the root canals of the teeth of the permanent and deciduous dentitions, New York: William Wood & Co, 1925.
2. Burns RC, Buchanan LS: Ch. 7, Tooth Morphology and Access Openings. In Cohen S, Burns RC, editors: *Pathways of the Pulp*, 6th ed., Mosby Yearbook Co., 1994.
3. Ruddle CJ: The Mesial-Buccal Root of the Maxillary First Molar: Treatment Considerations, *The Endodontic Report*, Fall/Winter, 1986.
4. Stropko JJ: Dental Canal Systems: An Exhaustive Clinical Canal Morphological Study, Personal Communication and to be published.
5. Kulid JC, Peters DD: Incidence and configuration of canal systems in the mesiobuccal root of maxillary first and second molars, *J Endod* 16:311, 1990.