

NONSURGICAL RETREATMENT OF ENDODONTIC FAILURES: TREATMENT CONCEPTS AND CONSIDERATIONS

by Clifford J. Ruddle, D.D.S.

In a recent interview, *Endodontic Therapy* and Dr. Cliff Ruddle discussed nonsurgical retreatment and the integration of traditional and modern techniques for achieving excellence and producing predictable outcomes. The following is a presentation of the interview.

ET: *What are the most important concepts for endodontic success?*

RUDDLE: Success is comprised of many elements, including making an accurate diagnosis. The first procedural step is complete access which provides the opening for finding all the orifices and canal systems. Next, we prepare a canal with efforts directed towards fulfilling the mechanical objectives of cleaning and shaping. Over time, it is becoming understood that files shape...irrigants clean. Importantly, shaping facilitates cleaning and shaping facilitates obturation. Vertical condensation carries a wave of warm gutta percha and sealer

into all aspects of the root canal system resulting in three-dimensional obturation. Following endodontic treatment, dentists must produce restorations that are esthetic, well-designed and that achieve a coronal seal (*Figure 1*).

ET: *Is it really possible to clean a root canal system, and if so, what are the methods you employ to accomplish this?*

RUDDLE: Sodium hypochlorite is a powerful, inexpensive and, when used correctly, safe irrigant that has been repeatedly shown to digest vital and necrotic tissue, destroy bacteria, spores and viruses, and eliminate their byproducts. Think of the root canal system as a tree. A tree is comprised of a main trunk with smaller branches. Clinicians shape a root canal utilizing instruments with efforts directed towards preparing the main canal. Shaping removes restrictive dentin. A shaped canal holds an effective reservoir of irrigant which can penetrate, circulate and clean into the lateral branches. A series of files progressively opens and shapes the main canal, but it is the irrigants that can potentially clean a root canal system.

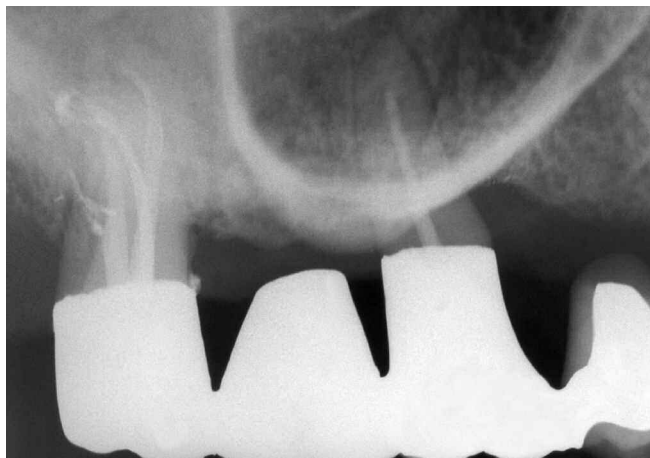

Figure 1a. A pre-operative film shows multidisciplinary treatment. The maxillary left first molar's remaining palatal root is endodontically failing.

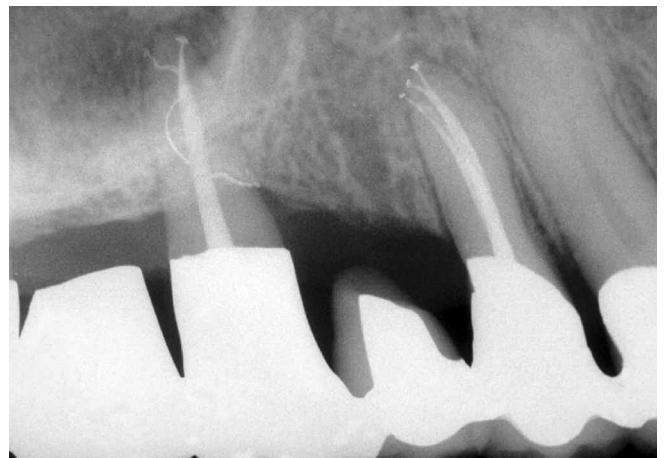

Figure 1b. Three-dimensional endodontic retreatment is the foundation of perio-prosthetics.

ET: *If endodontic treatment is generally successful, why do certain endodontically treated teeth fail and what are the causes of such failures?*

RUDDLE: Root canals fail due to microleakage and bacterial infection. The precise cause of endodontic failures can be attributable to inadequacies in three-dimensional cleaning, shaping and obturation. Additionally, failures occur because of missed canals, iatrogenic events, radicular fractures, or re-infection of the root canal system when the coronal seal is lost after the completion of root canal treatment. Regardless of the etiology, the sum of all causes is leakage, bacterial contamination or re-contamination.

ET: *Retreatment must address a multitude of circumstances to reach a successful outcome. What are the circumstances that will make retreatment successful?*

RUDDLE: Typically, endodontic retreatment involves accessing through a restorative, in other instances, sacrificing the dentistry, or employing techniques and devices to remove and save an existing restorative. Next, all core materials must be eliminated from the pulp chamber. With access and vision the pulp chamber is inspected to see if there have been any missed orifices/canals. Additionally, retreatment involves the removal of post and cores, broken instruments, and previously placed obturation materials. During retreatment we must be prepared to manage iatrogenic events such as negotiating blocked canals, bypassing ledges, repairing perforations and sealing apical transportations. When disassembly has been successfully completed then the root canal is negotiated and optimally shaped. A shaped canal facilitates removing all of the residual contents harbored within the root canal system. Cleaned and shaped canals can then be three-dimensionally packed. In fact, if there are no radicular fractures, if the tooth is not periodontally hopeless, and if the tooth is restorable, then we should be able to achieve success (*Figure 2*).

ET: *Would you discuss the endodontic flare-up and the antibiotics and NSAIDs that may be beneficial?*

RUDDLE: Endodontic flare-ups are situations where patients report pain and/or swelling following the initiation or continuation

of root canal treatment. The frequency of exacerbations associated with retreatment are notorious. Classically, patients present asymptomatic, have endodontic treatment, are dismissed then later report significant pain and/or swelling. In many instances, although the patient presented asymptomatic, there was a chronic underlying problem. Oftentimes, the flare-up occurred due to inoculating irritants into the attachment apparatus during the removal of existing materials or during the preparation of the canal. As an example, post-operative exacerbation may result following the removal of a silver point, cytotoxic paste, or shaping a previously missed necrotic canal. Antibiotics such as Penicillin, Amoxicillin or Clindamycin may be judiciously used to manage a flare-up. Empirically, some patients are prophylactically placed on an antibiotic to reduce the potential for a retreatment flare-up. Clinicians must use antibiotics intelligently and appropriately.

Nonsteroidal anti-inflammatory drugs (NSAIDs) such as Motrin, Lodine, Orudis or Toradol are very effective for managing pain and inflammation. Clinicians need to carefully review the patient's medical history and discuss with their patients the risk versus benefits of the medication as NSAIDs can induce G.I. complications or interact with other drugs.

ET: *What are the success rates for root canal treatment and for retreatment?*

RUDDLE: If we have an accurate diagnosis and when endodontic treatment is properly performed, then success rates can potentially approach 100%. However, most success and failure studies have been conducted over short timelines such as six months, one or two years. Regrettably, there have been few studies that have been conducted over time-line horizons of say 10, 15 or 20 years.

The good news is with a good biological rationale, utilizing the best presently developed technologies and integrating proven treatment techniques, there is enormous potential for success. Better trained dentists, in conjunction with a general public who increasingly votes for endodontics as an alternative to the extraction, have synergistically led to the annual

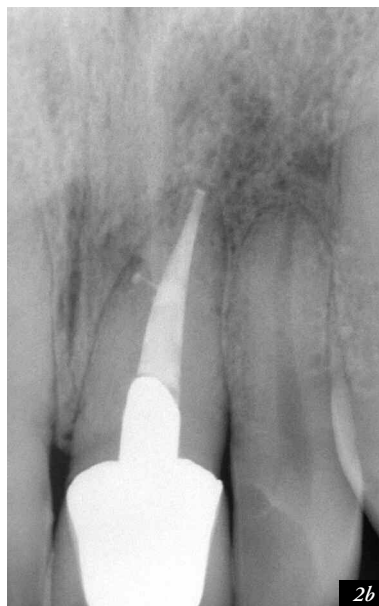
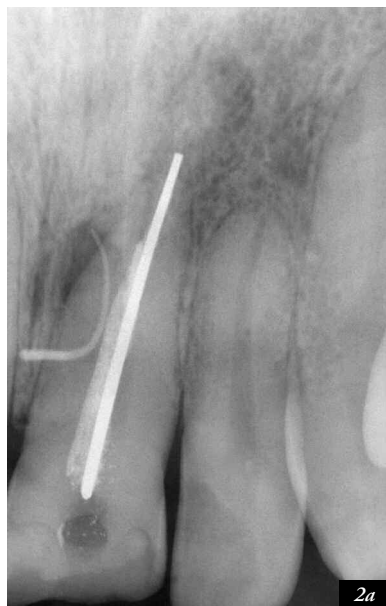
Figure 2a. A pre-operative film demonstrates a failing central incisor with a gutta percha point tracing a fistulous tract to a large lateral root lesion.

Figure 2b. A 5-year recall film demonstrates osseous repair following three-dimensional endodontics.

treatment of over 50 million cases in the United States alone. The bad news is even if we assume that 90% of all endodontics works, the reciprocal failure rate is 10%. Ten percent of 50 million equates to the possibility of 5 million failures per year. It should be understood that it may take 3, 4 or 5 years for an endodontically treated case to fail. Time catches up with deficiencies in endodontic treatment.

In terms of retreatment success, I can only report my experience. For me, nonsurgical endodontic retreatment success is about 85%. Virtually all failures can be successfully retreated nonsurgically, which means about 15% of my nonsurgical retreatment cases will continue to fail and will require either microsurgery or extraction. The reason there is a higher failure rate performing retreatment is because we're trying to overcome a variety of existing problems. In other words, I can't solve every problem case that presents in my office. In some cases I tell the patient, "We might get 3, 4 or 5 years out of this treatment and if signs or symptoms manifest, we can always consider surgery or extraction." Appreciate that if we can get a few additional years out of our retreatment efforts, then new technologies, materials and techniques will inevitably be available in the future to more predictably manage these cases.

ET: *What are the most important advances in the field of endodontic retreatment?*

RUDDLE: There are three major advancements driving endodontic retreatment today: (1) Vision utilizing dental operating microscopes, (2) piezoelectric ultrasonics and specifically designed instruments, and (3) mineral trioxide aggregate. Prior to 1990, many clinicians skipped nonsurgical retreatment and proceeded directly to surgical retreatment. The mindset was perform conventional root canal treatment (clean, shape and pack), and if that failed, proceed directly to surgery. If surgery failed, then infrequently an intentional replant was done, or more typically the tooth was extracted.

One of the reasons we have seen a significant increase in nonsurgical retreatment is because of vision technology. Vision equals magnification plus lighting. For most clinicians, vision is enhanced utilizing some form of magnification such as magnification glasses or loupes. Adjunctive lighting, beyond the overhead light, could include fiberoptic capabilities in high and low speed handpieces and/or the use of fiberoptic

transillumination devices. As an example, transilluminating devices enhance vision by collimating and directing more light into the pulp chamber to enhance diagnostics and treatment.

The breakthrough in vision has been the introduction of the dental operating microscope (*Carl Zeiss, Leica, Global Surgical*). The microscope has significantly impacted various disciplines within dentistry and refined and driven many procedural techniques (*Figure 3*). The microscope provides unsurpassed vision through the utilization of coaxial light and a range of magnification powers up to approximately 20X. In the field of endodontics we can now visualize deep into the root canal space. There is an old expression if you can see it – you can do it. Microscopes are one of the single most important instruments in dentistry today.

Microscopes have driven refinements in instruments. Piezoelectric generators, in conjunction with uniquely designed ultrasonic instruments, has led to "microsonic" techniques. Piezoelectric generators (*Satelec P5, Dentsply Tulsa Dental*) need to provide a broad range of power and focus the energy so that ultrasonic instruments work efficiently, precisely and safely (*Figure 4a*). I've developed specific ultrasonic instruments (*ProUltra ENDO Tips #1-8, Dentsply Tulsa Dental*) that are unique because they're contra-angled, parallel walled and coated (*Figure 4b*). The ProUltra ENDO tips are used internationally by both general dentists and endodontists to perform many treatment and retreatment procedures. Many dentists are discovering the enormous benefits of ultrasonic technology to remove pulp stones, chase a calcified canal, or trough for an MB2. Importantly, ultrasonics is routinely used in NSRCT to remove gutta percha, silver points, carriers, paste, posts, and broken instruments. Additionally, ultrasonic techniques have been developed to vibrate Mineral Trioxide Aggregate (MTA), commercially available as ProRoot (*Dentsply Tulsa Dental*) into radicular defects. In many instances, sealing a perforation facilitates osseous repair.

ProRoot is a relatively new material that creates an extraordinary breakthrough for managing radicular repairs. ProRoot is used to manage canals that exhibit reverse apical architecture, such as immature roots or iatrogenically induced apical transporations. Additionally, this material is used for the nonsurgical repair of perforations or microsurgical procedures. Remarkably, sharpey's fibers grow into this material allowing

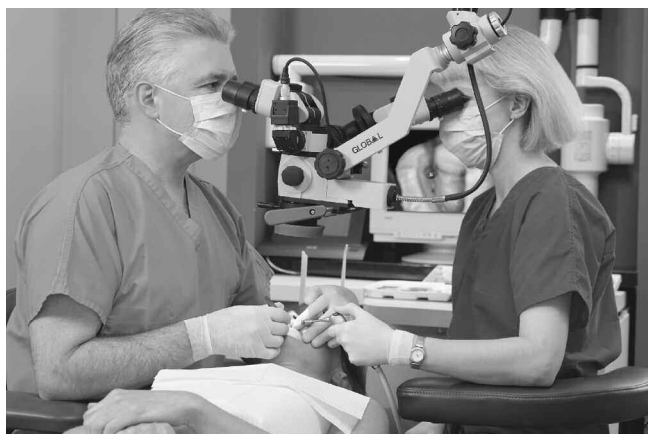

Figure 3. All phases of endodontic treatment are significantly improved when the dental team utilizes the microscope.

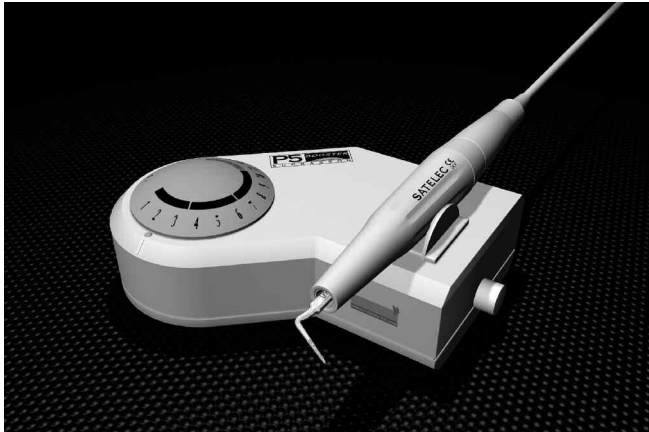


Figure 4a. The Satelec P5 piezoelectric ultrasonic unit powers a variety of innovative ultrasonic instruments.

cementum to grow over this nonresorbable and radiopaque material, thus allowing for a normal periodontal attachment. Many scientific articles have elaborated on ProRoot and reported that it is not compromised by moisture, sets brick-hard in approximately 4 hours, and creates a seal as good as or better than the best materials used today. ProRoot has allowed us to save countless teeth that previously would have been considered hopeless.

ET: *I understand that endodontic procedures are often performed through an existing restoration, while in other instances, a restoration may be sacrificed. Is it possible to safely remove an existing restoration to facilitate treatment?*

RUDDLE: There are a variety of devices and techniques that can successfully remove definitively cemented restoratives. The safe dislodgment of a restoration is dependent on the type of preparation, the restorative design and strength, the restorative material, and the cementing agent. There are many important removal devices and they may be generally divided into three categories: (1) Grasping instruments, such as K.Y. Pliers (*GC America*), (2) Percussive instruments like the Peerless Crown-a-Matic (*Henry Schein*) and the Coronaflex (*KaVo America*), and (3) Passive-active instruments such as the Metalift (*Classic Practice Resources*) (*Figure 5*).

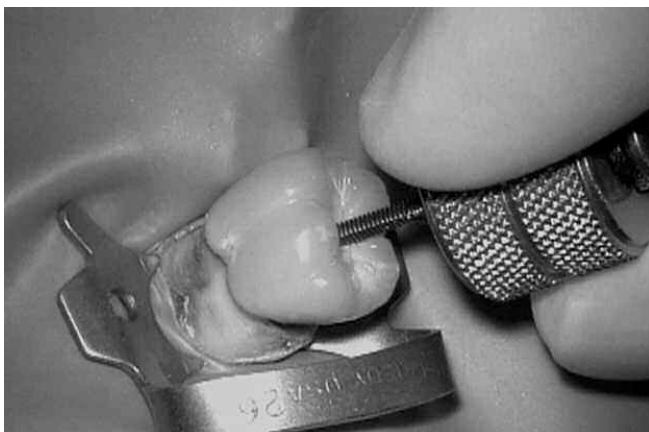

Figure 4b. The ProUltra Endo #1-5 zirconium nitride coated ultrasonic instruments improve vision, access and control when performing clinical procedures.

ET: *Would you discuss the process for locating previously missed canals associated with endodontic failures?*

RUDDLE: Clinicians need to completely understand and fully appreciate the anatomy of human teeth and use this knowledge to locate calcified, aberrant, or previously missed canals. One of the common causes of failure in endodontics is missed canals which hold tissue, and at times bacteria and their related irritants. These breakdown products inevitably contribute to clinical symptoms and lesions of endodontic origin. There are multiple concepts, armamentarium and instruments that are useful to locate canals, including anatomical familiarity, radiographic analysis, magnification and lighting, complete access, ultrasonics, microscopes, dyes, sodium hypochlorite (NaOCl), color and texture, removing restorations, probing the sulcus and, when appropriate, a timely referral.

ET: *Can you discuss the various methods to remove gutta percha from a root canal?*

RUDDLE: With good case selection, NiTi rotary files are very effective and efficient for removing gutta percha. NiTi instruments are used for shaping canals at a speed of approximately 300 RPM. For rotary removal of gutta percha we recommend approximately 1,000 RPM as greater rotational speed is necessary to create the friction and heat necessary

Figure 5. A clinical photograph demonstrates the removal of a PFM crown utilizing the Metalift device.

to thermosoften gutta percha. The blades of nickel titanium instruments engage softened gutta percha and effectively auger this material out of a root canal space (*Figure 6*). Certainly, hand files in the presence of a chemical, such as chloroform, is another important method to remove gutta percha from smaller and more curved canals. Chloroform rapidly softens gutta percha and, in conjunction with files, allows for the removal of gutta percha in a crown-down manner. With the canals filled with chloroform bath then paper points are utilized to wick residual gutta percha and sealers from the more inaccessible regions of the root canal system.

Another important method to remove gutta percha, especially when the canal has been overextended vertically and under-filled laterally, is to utilize the hedstroem displacement technique. The gutta percha is first thermosoftened with heat and then a 35, 40, or 45 hedstroem file is passively rotated clockwise into this mass. Let the gutta percha cool and harden within the blades, and upon withdrawing the hedstroem file, oftentimes the entire mass of gutta percha will be removed as well (*Figure 7*).

ET: *What are some of the more important methods to remove silver points, carrier-based obturators, and paste from endodontically failing teeth?*

RUDDLE: The first thing I consider when removing silver points is careful access. In many instances a silver point extends out of the canal and into the pulp chamber. Clinicians need to thoughtfully perform access so as not to inadvertently foreshorten a silver point which could result in making it more difficult to grasp and pull out. It's important to remove all circumferential material surrounding the silver point to facilitate loosening and removal. A grasping tool such as the Stieglitz pliers (*Henry Schein*) can generally get a strong purchase on the coronal end of a silver point and then, utilizing the concept of fulcrum mechanics, elevate the silver point out of the canal.

Indirect ultrasonics is another important method to remove silver points. It is not wise to place any ultrasonic instrument directly on the silver point because it will rapidly erode away this soft material. Rather, first engage the silver point with a grasping instrument and then place an ultrasonic instrument, such as a ProUltra Endo Tip #1, on the pliers to indirectly

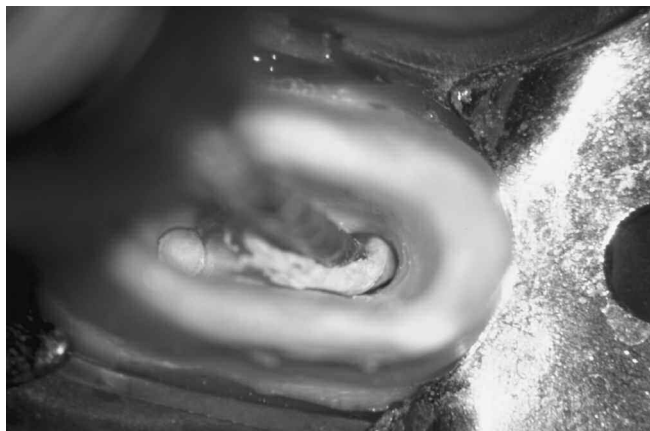


Figure 6. A photograph at 15x demonstrates the removal of gutta percha from a palatal canal with a 0.06 tapered NiTi rotary profile.

vibrate it loose. Since most canals are irregular in their cross-sectional dimensions and since silver points are round, then theoretically, space exists between the wall of the canal and the silver point. Files, solvents, and chelators can be utilized to eliminate sealer thus undermining and loosening the silver point so it can be removed. The hedstroem displacement technique is an invaluable technique to remove silver point segments. Finally, microtubes can be utilized to engage and remove certain silver points. The Post Removal System (PRS) (*SybronEndo*) has small microtubular taps, allowing the clinician to mechanically tap and engage any silver point that is 0.6 mm or greater in diameter.

The successful removal of carrier-based obturators utilizes the same techniques described for removing gutta percha and silver points. Oftentimes, the biggest secret to remove a carrier is patience and perseverance.

When evaluating a paste case for retreatment, it is wise to recognize that certain pastes are very difficult to remove because they set up brickhard. However, it is important to appreciate that due to the method of placement, the most dense portion of the paste is coronal and the material is less dense apically. Ultrasonic instruments, in conjunction with the microscope, afford excellent control in removing paste from the straight-away portions of the canal. To remove paste apical to canal curvature we can use a precurved stainless steel file attached to a specially designed "file adapter" that hooks to the ultrasonic handpiece. Other removal methods include heat, end-cutting rotary NiTi instruments, chemicals such as Endosolv R and Endosolv E (*Endoco*) and Micro-Debriders (*Dentsply Maillefer*).

ET: *What are the considerations and techniques for post removal?*

RUDDLE: Before entertaining any post removal method, the clinician should have complete access to the pulp chamber floor, and have removed all materials circumferential to the post. Factors that will influence post removal are post diameter, length and the cementing agent. Posts can be catalogued into parallel versus tapered, stock versus cast, actively engaged versus non-actively retained and metallic versus non-metallic compositions. Additionally, other considerations include available

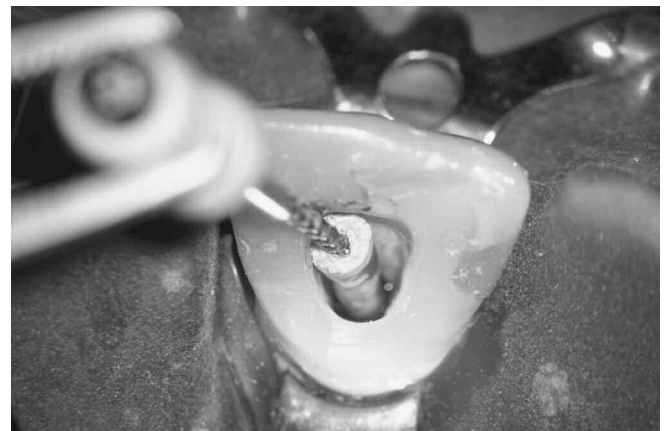

Figure 7. A photograph at 8x shows a 45 hedstroem mechanically removing a heat softened single cone of gutta percha.

interocclusal space, existing restorations and if the post head is supra- or sub-crestal. The first line of offense to remove a post is utilizing piezoelectric ultrasonic energy. The Satelec P5 power source in conjunction with the ProUltra Endo Tip #1 will transfer energy, powerfully vibrate, and dislodge most posts (*Figure 8*). The majority of posts can be safely and successfully removed in about 10 minutes. In smaller teeth or roots that have deep concavities use water to keep the post and root cool during the removal procedures.

ET: *When a post cannot be removed with ultrasonics, is there any other backup techniques that can be employed?*

RUDDLE: Certain posts resist removal even after ultrasonic efforts using the “10 Minute Rule”. Clinicians need a fall-back position to liberate these posts from the canal. The Post Removal System (PRS) is the next line of offense and provides an extraordinary opportunity to remove a post or other intracanal obstruction (*Figure 9*). In this removal method a trephine is used to machine down the most coronal aspect of the post 2-3 mm. Then a correspondingly sized tap is screwed in a

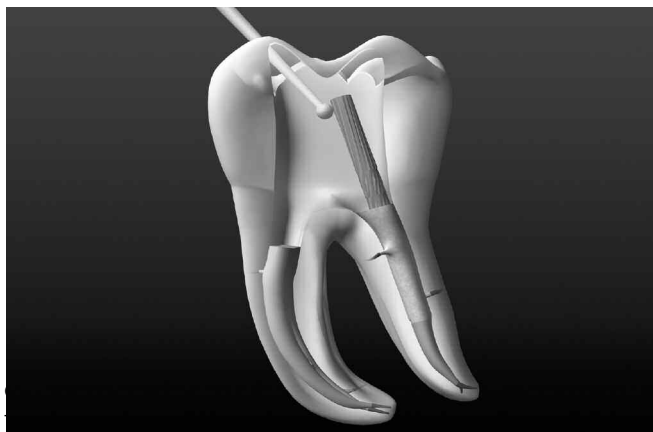

Figure 8. The ProUltra Endo Tip #1 has a working-end ball that, when ultrasonically energized, can be used to powerfully vibrate against all aspects of the exposed post.



Figure 9. The PRS kit is comprised of 5 variously sized trephines and corresponding taps, a transmetal bur, rubber bumpers, a torque bar and the extracting plier. This system is designed to safely remove virtually any post.

the post, the extracting pliers are used to safely and progressively elevate the post out of the canal (*Figure 10*).

ET: *What are the considerations and techniques for removal of broken instruments from the root canal system?*

RUDDLE: The ability to access and remove a broken instrument will be influenced by the cross-sectional diameter, length and curvature of the canal, and further guided by the depth of external concavities. As a rule of thumb, if one-third of the overall length of an obstruction can be exposed, it can usually be removed.

Clinicians need to radiographically visualize if the broken instrument is in the coronal, middle or apical one-thirds of the root. Instruments that lie in the straightaway portions of the canal can usually be removed. If a separated instrument lies partially around the curvature and if safe access can be established to its most coronal extent, then removal is oftentimes still possible. If the entire segment of the broken instrument is apical to the curvature of the canal and safe access cannot be accomplished, then removal is usually not possible.

The technique required to remove a broken instrument first begins with establishing complete coronal access. Before establishing radicular access, attention is directed towards pre-operative radiographs and working films to better appreciate the root bulk, thickness of the dentinal walls, and if present, the depth of an external concavity. If radicular access is limited, then hand files are used serially small to large, coronal to the obstruction, to create sufficient space to safely introduce gates glidden (GG) drills. GG's are used like “brushes” and each larger GG is stepped out of the canal to create a smooth flowing funnel which is largest coronally and tapers down to the head of the broken file.

The microscope, in conjunction with ultrasonic techniques, has led to precise microsonic techniques. Once the head of the broken instrument is readily visible then specially designed contra-angled, parallel-walled and abrasively-coated ultrasonic instruments (ProUltra Endo Tips #3, 4, 5) are




Figure 10. A graphic demonstrates the mounted and activated PRS extracting plier. Note the energized ProUltra Endo Tip #1 may also be utilized to vibrate against the tap and further encourage cement-bond failure.

selected to sand away dentin and trephine circumferentially around the obstruction. The idea is to transfer ultrasonic energy to the broken instrument so that it will loosen, unwind and then spin. Oftentimes, the broken instrument will “jump out” of the canal.

When ultrasonic techniques fail, the fall-back option is to use the Instrument Removal System (iRS) (*Dentsply Tulsa Dental*) which provides a breakthrough in the retrieval of broken instruments lodged deep within the root canal space. The iRS is composed of variously sized microtubes and screw wedges. The microtube has a small handle to enhance vision and its distal end is constructed with a 45° beveled end and side window. The microtube is inserted into the canal and, in the instances of canal curvature, the long part of its beveled end is oriented to the outer wall of the canal to “scoop-up” the head of the broken instrument and guide it into its lumen. The screw wedge is then placed through the open end of the microtube and passed down its internal lumen until it contacts the broken instrument. Rotating the screw wedge handle tightens, wedges, and oftentimes, displaces the head of the file through the microtube’s side window. With the

broken instrument strongly engaged, it can generally be readily removed (*Figure 11*).

ET: *Would you discuss the causes of blocked and ledged canals?*

RUDDLE: Blocks and ledges are attributable to working short, apical preparation first schemes, the types of instruments employed and their methods of use. Generations of dentists have been trained to “work short” of the radiographic terminus (RT). The extent of shortness, although well-intentioned, has been arbitrary and based on misinformation, misconceptions and myths. Every dentist who has worked short has experienced the frustration of apical “blockage”, ending up even shorter than was their intent. A loss of working length occurs due to the compaction of collagenous tissue apically and/or the accumulation of dentine mud. Apically blocked canals frequently hold combinations of pulp, bacteria, related irritants and dentine mud in their terminal extents. The ledge is a progression of the block. Aggressively trying to place progressively larger files to full working length in a blocked and curved canal negates the possibility for the file

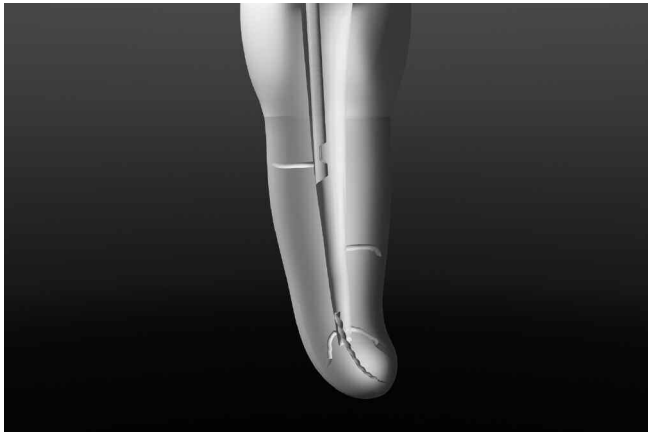

Figure 11a. This graphic illustrates that the iRS microtube is introduced so its beveled-end is oriented towards the outer wall of the canal.

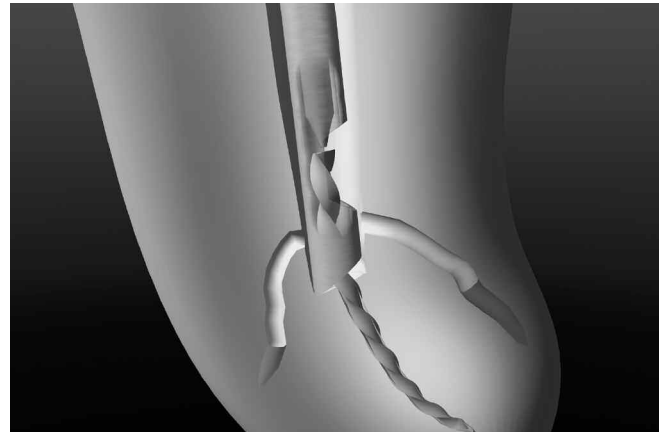


Figure 11b. This graphic shows the head of the broken file “scooped-up” and the screw wedge internally approaching the broken instrument.

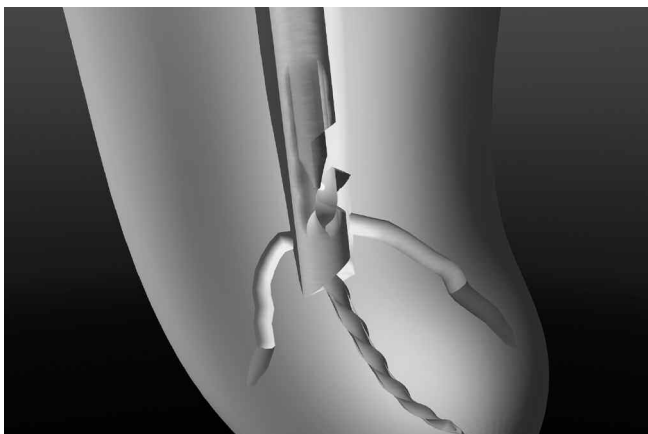


Figure 11c. This graphic shows the screw wedge actively engaging and displacing the head of the file out the side window.

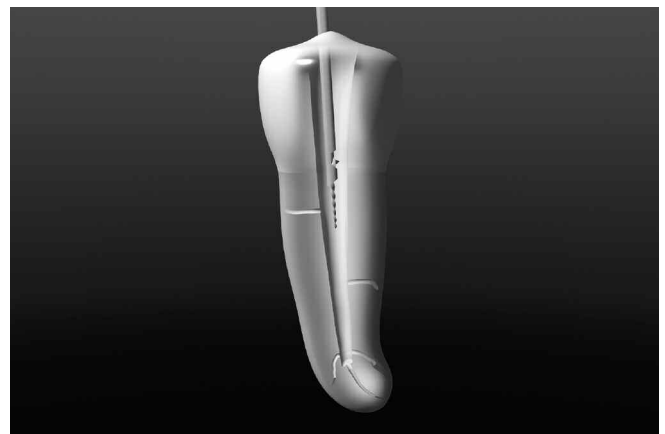

Figure 11d. This graphic shows the mechanics and powerful purchase that can be attained with the iRS in order to liberate the broken instrument.

to “follow” the true canal. Files begin to dig into the outer wall and the block becomes a ledge (*Figure 12*).

With “*apical preparation first*”, the approach to canal preparation is to negotiate and prepare the apical one-third of the root canal first followed by a coronal flaring technique to facilitate obturation. The breakdown is the failure to recognize that frequently the rate of taper of the instrument exceeds the rate of taper of the canal which prevents the file’s apical movement. When an instrument binds on its more shank-side cutting blades, the clinician loses apical file control. Attempting to negotiate and prepare the apical one-third of the canal first is equivalent to launching a “surprise attack” in the most delicate part of the microanatomy. Canals typically exhibit their greatest curvatures and deep divisions in their apical extents. Specifically, passing a precurved negotiating file through a coronally tight and underprepared canal straightens the instrument. Unknowingly attempting to work straighter files to length in curved canals first invites the block then predisposes to the formation of a ledge.

Further contributing to breakdowns in the *apical preparation first* sequence is the fact that non-flared canals hold a small or non-existent volume of irrigation which in turn invites the accumulation of dentine mud. Working short, in conjunction with attempting to prepare the apical one-third first, has contributed to blocked foramens or in other instances, has led to canals that have been ledged, externally transported or apically perforated.

The types of “*instruments employed*” to prepare canals has traditionally been files, reamers and hedstroems in conjunction with rotary driven instruments. In practice, increasing stiffness was clinically noted when progressing through any type of instrument series. In fact, the stiffness problem was compounded by the mathematical fact that there is a nonlinear increase in apical diameters between successively larger ISO files. Specifically, there is a significant “percentage change” among the most terminal diameters of the smaller instruments.

Beyond imperfect file designs, a major contributor to cleaning and shaping breakdowns has been, and continues to be, “*method of use*”. Techniques advocating getting to length early have encouraged aggressive cutting action. Screwing

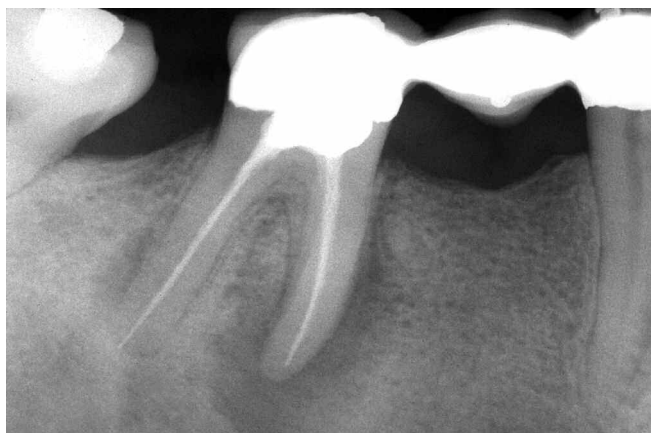

Figure 12a. A pre-operative radiograph shows an endodontically failing posterior bridge abutment. Note the amalgam in the pulp chamber and that the mesial root appears to have been ledged.

larger, less flexible files into canals is the primary reason for blocks, ledges, transportations, perforations, interappointment flare-ups, short-term failure, surgeries and extractions. Preparation breakdowns continue to drive the growing field of endodontics.

ET: *What are apical transportations and how are they managed?*

RUDDLE: An apical transportation of the root canal represents iatrogenically moving the physiologic terminus to a new location on the external root surface. In many instances, these canals become wet with exudates and difficult to dry. Transportations lead to post-operative flare-ups, surgeries and extractions. A canal that has been apically transported predisposes to obturation overextension where gutta percha moves beyond the foramen and into the periapical tissues. Consequently, the canal is vertically overextended, but importantly, laterally underfilled which contributes to failure.

Managing transportations requires optimal preparation of the coronal two-thirds of the canal prior to placing ProRoot into that portion of the canal that exhibits reverse apical architecture. ProRoot is easy to use and the powder is mixed with anesthetic solution or sterile water to a heavy cake-like consistency (*Figure 13*). A small aliquot of this cement is picked-up and introduced into the prepared canal with a microtube carrying device such as a customized spinal tap needle, or on the side of a West Perf Repair Instrument (*SybronEndo*). ProRoot is then gently tamped and coaxed down the canal to approximate length using a customized nonstandard gutta percha cone as a flexible plugger. In straighter canals, ProRoot can be vibrated, moved into the defect and to length with the ProUltra Endo Tip #3, 4 or 5. Direct ultrasonic energy will vibrate and generate a wave-like motion which facilitates moving and adapting the cement into the apical extent of the canal. Prior to initiating subsequent procedures, a dense 4-5 mm zone of ProRoot in the apical one-third of the canal should be confirmed radiographically.

In the instance of repairing a defect apical to the canal curvature, a 4-5 mm column of ProRoot is first shepherded around the curvature with a flexible gutta percha plugger. A precurved 15 or 20 stainless steel file is then carried around the canal curvature, into the ProRoot and to within 1-2 mm of the

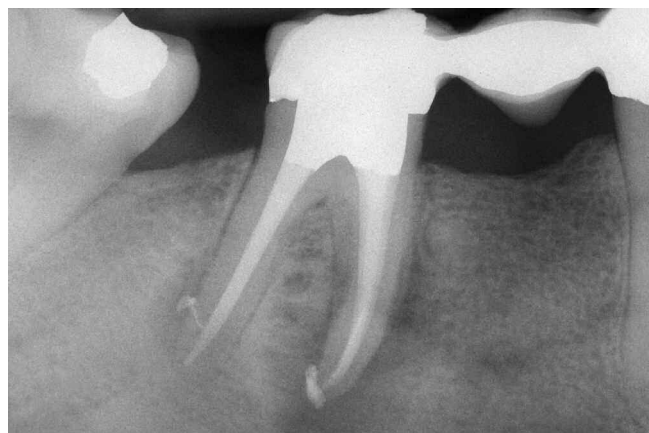

Figure 12b. A post-treatment film demonstrates ledge management with the obturation materials following the root curvature.



Figure 13. ProRoot is packaged in a powder form and then mixed with sterile water to a heavy cake-like consistency.

working length. Indirect ultrasonics with a ProUltra Endo Tip #1 is then utilized on the shaft of the file. This vibratory energy will encourage ProRoot to slump, move and adapt to the configurations of the canal laterally as well as control its movement to and gently against the periapical tissues. Again, the clinician should radiographically confirm that there is a dense 4-5 mm zone of ProRoot in the apical extent of the canal.

ET: *Could you define perforations, describe their etiology, treatment considerations and best materials?*

RUDDLE: Perforations represent pathologic or iatrogenic communications between the root canal space and the attachment apparatus. The causes of perforations are resorptive defects, caries, or iatrogenic events that occur during and after endodontic treatment. Regardless of etiology, a perforation is an invasion into the supporting structures that initially incites inflammation and loss of attachment and ultimately may compromise the prognosis of the tooth.

When evaluating a perforated tooth, there are a number of variables that must be considered individually and collectively to properly guide treatment. Treating clinicians must identify the four dimensions of a perforation and understand how each of these entities critically affects treatment selection and prognosis.

1. *Level:* Perforations occur in the coronal, middle and apical one-thirds of roots. More coronally positioned perforations

threaten the sulcular attachment and pose different treatment challenges than more apically occurring perforations. In general, the more apical the perforation, the more favorable the prognosis.

2. *Location:* Perforations occur circumferentially on the buccal, lingual, mesial and distal aspects of roots. The location of the perforation is not so important when nonsurgical treatment is selected but its position is critical if a surgical repair is considered.
3. *Size:* The size of a perforation greatly affects the clinician's ability to establish a hermetic seal. The area of a circular shaped perforation can be mathematically described as πr^2 . Therefore, doubling the perforation size with any bur or instrument increases the surface area to seal by four-fold. Compounding the challenge to efficiently seal a perforation is that many of these defects are ovoid in shape due to their nature of occurrence.
4. *Time:* Regardless of etiology, a perforation should be repaired as soon as possible to discourage further loss of attachment and prevent sulcular breakdown. Chronic perforations exhibiting a loss of sulcular attachment pose treatment challenges that potentially escalate to surgical correction and efforts directed towards guided tissue regeneration procedures.

In general, ProRoot is the restorative material of choice to repair virtually all perforation defects. At the present, ProRoot is a grayish-colored material which may preclude its use if there is an esthetic consideration. Since I have already spoken about ProRoot, let me briefly describe the concept of how to repair a perforation when there is an esthetic consideration. Tooth-colored restoratives, such as a dual cured composite, require the placement of a barrier so the material is not contaminated during use. A barrier serves as a "hemostatic" and a "backstop" so a restorative material can be placed into a clean, dry preparation with control. Calcium sulfate is the barrier of choice when using the principles of wet bonding, is biocompatible, osteogenic, resorbable, and following placement, sets brick-hard. When set, calcium sulfate is trimmed back to the cavo surface of the root. A dual cured, tooth-colored restorative can now be placed against the barrier and utilized to seal a root defect.

I trust my answers will give clinicians a greater appreciation regarding the field of nonsurgical endodontic retreatment. ▲