

NONSURGICAL RETREATMENT: POST & BROKEN INSTRUMENT REMOVAL

by Clifford J. Ruddle, D.D.S.

There has been massive growth in endodontic treatment in recent years. This upward surge of clinical activity can be attributable to better trained dentists and specialists alike. Necessary for this unfolding story is the general public's growing selection for root canal treatment as an alternative to the extraction. Over time, patients have become more confident selecting endodontic treatment because of the changing perception that pain can be managed, techniques have improved and longterm success is achievable.

With all the potential for endodontic success the fact remains clinicians are confronted with post-treatment disease.^{1,2} Before commencing with any treatment, it is wise to fully consider all the various treatment options.^{3,4} When the choice is endodontic nonsurgical retreatment, then the goal is to access the pulp chamber and remove materials from the root canal space and if present, address deficiencies or repair defects that are pathologic or iatrogenic in origin.^{5,6} Further, endodontic access provides the opportunity to diagnostically evaluate teeth for coronal leakage, fractures and missed canals.^{7,8} Importantly, following disassembly procedures, these root canals can be re-shaped, if necessary, and potentially these root canal systems can be three-dimensionally cleaned and filled (*Figure 1*).⁹⁻¹¹

Endodontic nonsurgical retreatment is a comprehensive field and may be divided into the following categories: coronal disassembly, locating previously missed canals, removing obturation materials, negotiating blocks, bypassing ledges, managing fractures, repairing perforations, treatment planning fractures, and removing posts and broken instruments.⁵ This field of endodontics has its own science, literature, specific technologies, best materials, and escalating range of techniques that are, at times, required to achieve clinical success. Because the field of nonsurgical retreatment is comprehensive, this article will limit its focus to post and broken instrument removal.

POST REMOVAL

It is common for clinicians to encounter endodontically treated teeth that contain posts. Frequently, when endodontic treatment is failing, the need arises to remove a post to facilitate successful nonsurgical retreatment. In other instances, the endodontic treatment may be judged successful, but the restorative needs require the removal of an existing post to improve the design, mechanics or esthetics of a new restoration. Over time, many techniques have been advocated for the removal of posts and other large intracanal obstructions.¹²⁻¹⁴

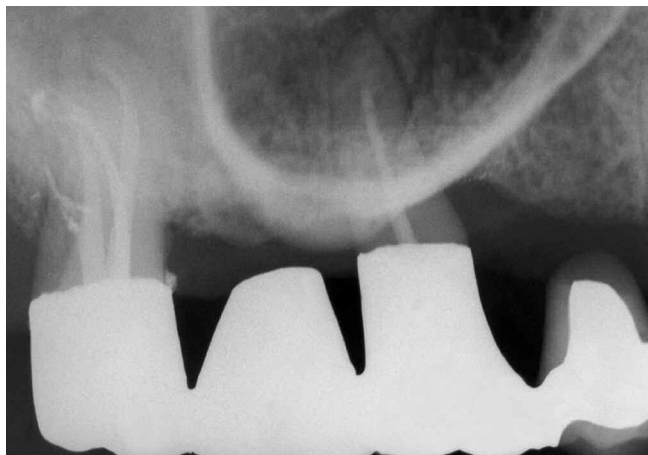

Figure 1a. A pre-operative film demonstrates multidisciplinary treatment and reveals the remaining palatal root of this maxillary left first molar is endodontically failing.

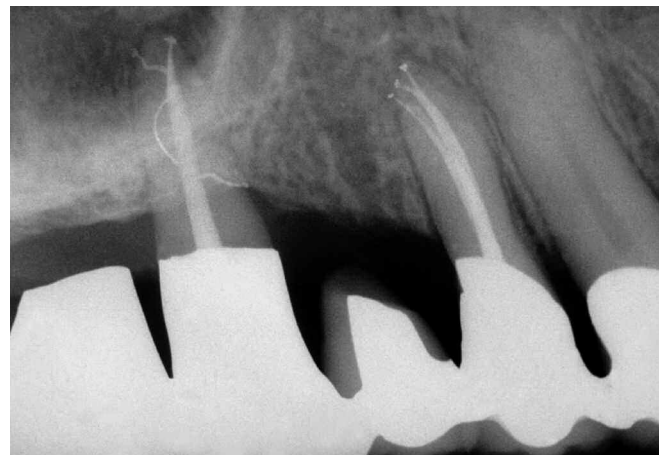


Figure 1b. Three-dimensional endodontic retreatment is the foundation of perio-prosthetics.

FACTORS INFLUENCING POST REMOVAL

There are many factors that influence successful post removal such as operator judgment, training, experience, and utilizing the best technologies and techniques.^{9,15} Further, clinicians should have knowledge and respect for the anatomy of teeth and be familiar with the typical range of variation associated with each tooth type.¹⁶ As an example, it is important to know tooth morphology including the length, circumferential dimension and curvature of any given root including, if present, the depth of an external concavity. This information is best appreciated by obtaining three well-angulated pre-operative radiographs. Films also assist the clinician in visualizing the length, diameter and direction of the post, and aid in determining if it extends coronally into the pulp chamber.¹⁷

Other factors influencing post removal are the post type and cementing agent.^{18,19} Posts can be catalogued into parallel versus tapered, active versus non-active, and metallic versus new, non-metallic compositions (*Figure 2*).^{20,66} Posts retained with the classic cements like zinc phosphate can generally be removed; however, posts bonded into the root canal space with materials like composite resins or glass ionomers are oftentimes more difficult to remove.^{21,66} In addition, other

important factors that impact post removal are the available inter-occlusal space, existing restoration, and whether the coronal most aspect of the post is supra or subcrestal (*Figure 3*). In general, post removal becomes more challenging moving from anterior to posterior teeth. The difficulty in removing a post substantially increases in furcated teeth containing multiple posts joined coronally with single or multiple interlocking key-ways (*Figure 4*).

When evaluating a tooth for post removal, the clinician must weigh risk versus benefit before proceeding with this procedure.²² As an example, the relative radiodensity between a titanium or a titanium alloy post can appear very similar, or even identical, to gutta percha when viewed radiographically. As such, when considering nonsurgical retreatment, clinicians need to be familiar with the radiographic characteristics of these non-metallic posts.^{23,66} A root can be structurally weakened, perforated or fractured during any phase of retreatment ranging from radicular disassembly to subsequent shaping and filling procedures. In some instances, it may be wise to consider a surgical approach to resolve an endodontic failure. However, surgery should not be performed promiscuously because of lack of training in the best, presently developed, techniques utilized for post removal.

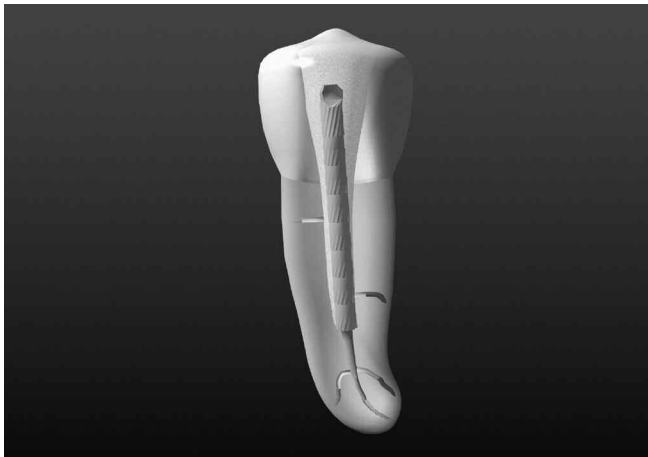


Figure 2a. Parallel post.

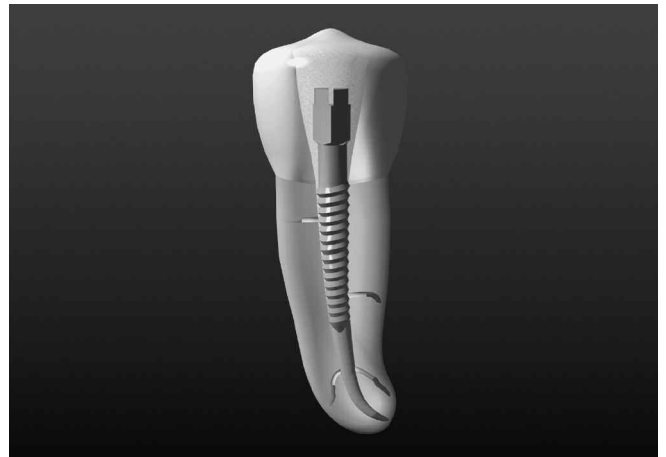

Figure 2b. Screw post.

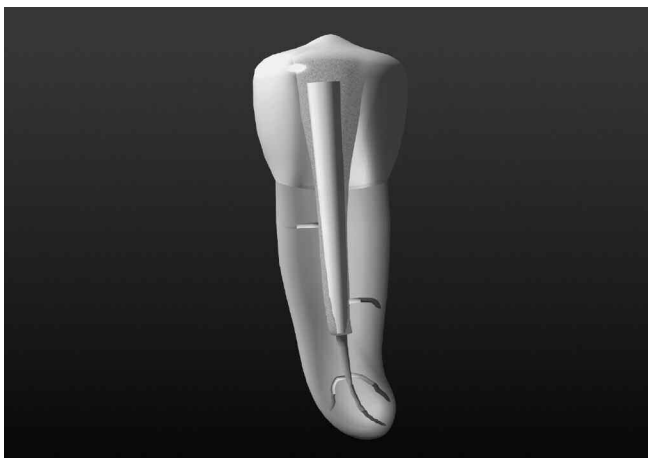


Figure 2c. Composite post.

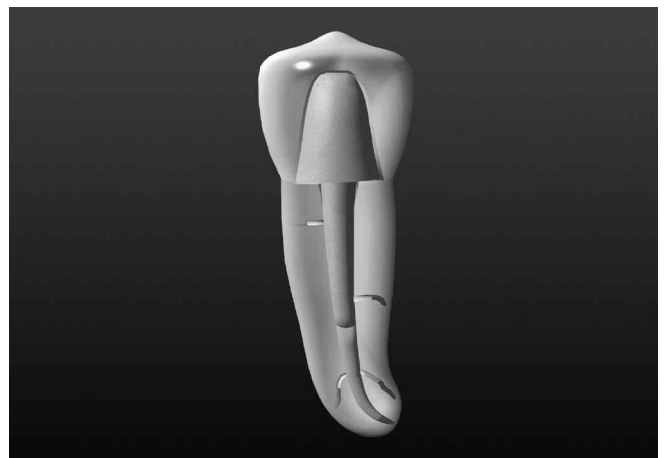


Figure 2d. Cast gold post / core.

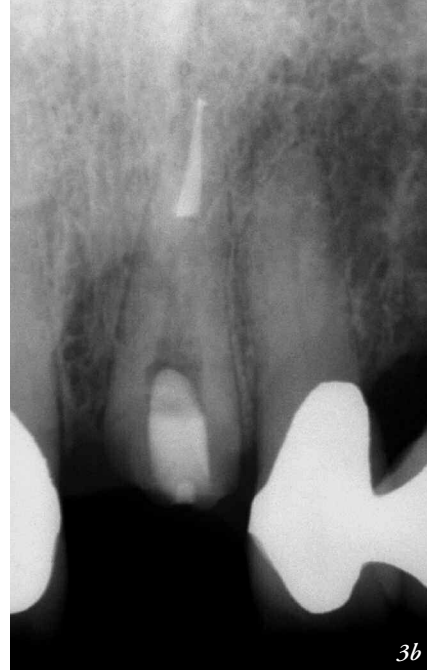
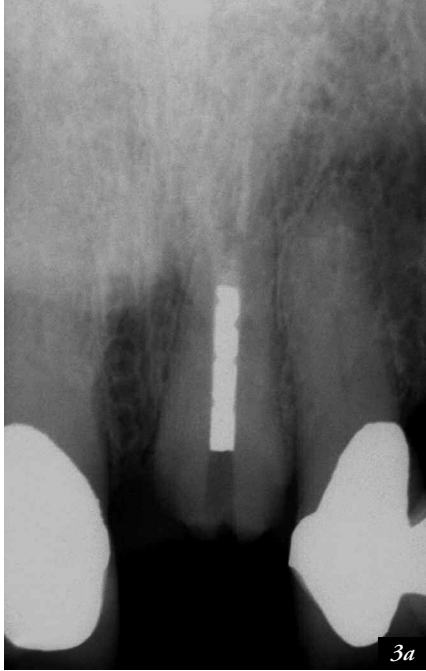
Figure 3a. A pre-operative film of a maxillary central incisor shows a post broken subcrestally and serves to emphasize the importance of treatment planning.

Figure 3b. The post-treatment film shows post removal, retreatment, and post space prior to crown lengthening and restorative treatment.

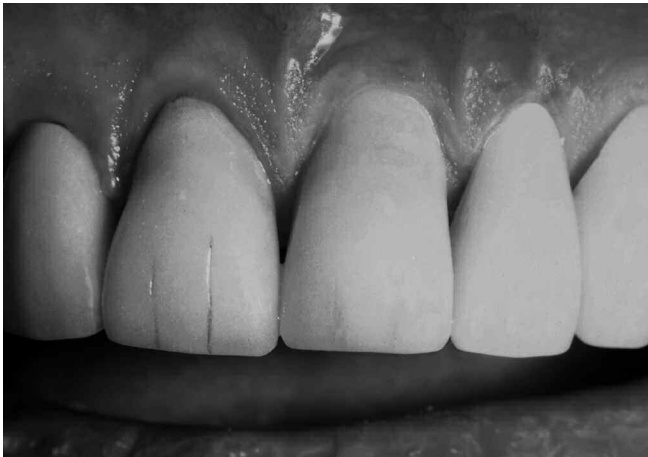

Figure 3c. A post-treatment photograph shows the restoration.

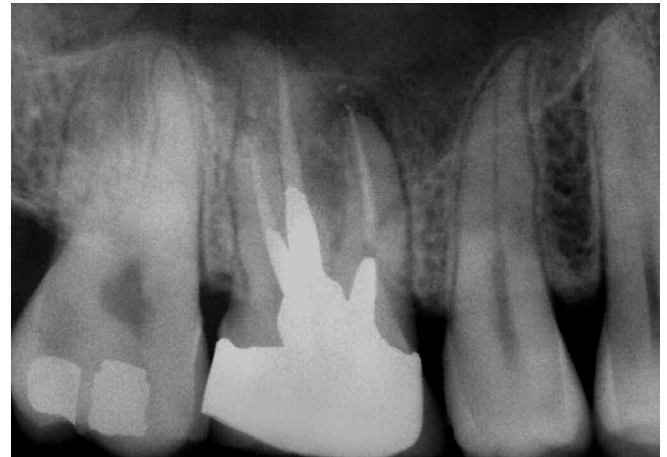


Figure 4a. A pre-operative film reveals the MB root of this maxillary first molar is endodontically failing. Note 3 cast posts interlocking within the pulp chamber.

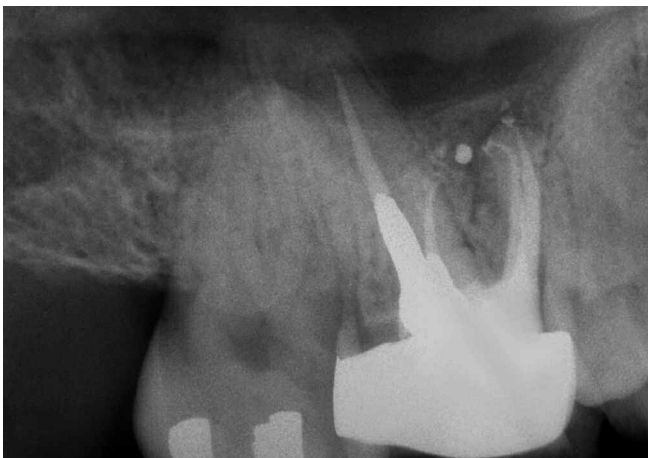

Figure 4b. A distal angulated radiograph demonstrates the retreatment effort of the MB root. Note the identification and treatment of the MBII system.

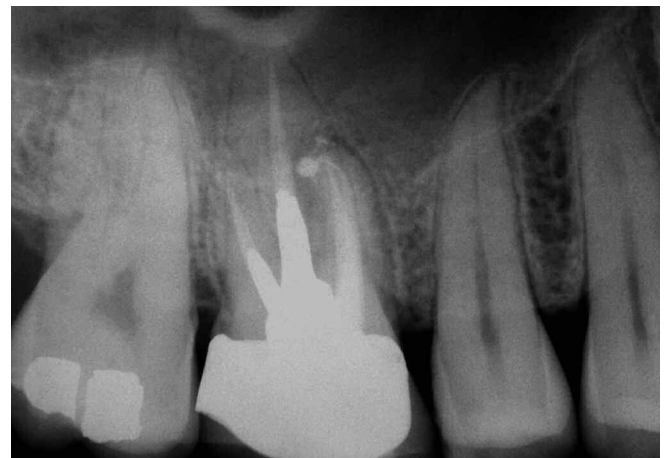


Figure 4c. A 2-year recall radiograph demonstrates excellent healing associated with the MB root.

TECHNIQUES FOR ACCESS

Successful post removal requires sufficient access so all restorative materials from the pulp chamber can be eliminated (*Figure 5*). Clinicians oftentimes access the pulp chamber through an existing restoration if it is judged to be functionally designed, well-fitting and esthetically pleasing.⁷ If the restoration is deemed inadequate and/or additional access is required to accomplish the retreatment task, then it should be sacrificed. However, on specific occasions, it may be desirable to remove the restoration intact so it can be re-cemented following endodontic treatment.⁵ Coronal disassembly improves access, vision and the retreatment efforts. When post removal procedures are performed through an existing restoration, then highspeed rotary cutting tools are utilized to prepare a lingual or occlusal window, section and eliminate the core, and create straightline access into the pulp chamber. The #2 and #4 round bur diamonds, in conjunction with water, are utilized to more safely brush-cut through tooth-colored restoratives such as porcelain. The transmetal bur is the bur of choice for cutting metal because the sawtooth configuration of its blades reduces unwanted vibration when cutting various types of precious and non-

precious metals. Surgical length, #2 and #4 carbide round burs provide extended reach which improves access and vision into the pulp chamber. Round burs efficiently remove dentin and the restorative materials that commonly entomb the head of a post. Surgical length tapered diamonds are advantageously used with a light brushing motion to refine, smooth and flare the axial walls and finish all aspects of the access preparation.

Piezoelectric technology in conjunction with ultrasonic instruments provides important advantages when performing access refinement procedures. Advantageously, small profiled ultrasonic instruments afford continuous and improved vision into the field of operation (*Figure 6a*). On the contrary, a rotating bur in a dental handpiece is oftentimes difficult to see because even a small sized head oftentimes blocks the line of sight. Strategically, contra-angled, parallel-sided and abrasively coated stainless steel ultrasonic instruments enhance access, vision and cutting precision when progressively sanding away various materials. In general, ultrasonic instruments are used at the lowest power settings that will efficiently accomplish the clinical task. Thinner and more parallel-sided ultrasonic instruments are

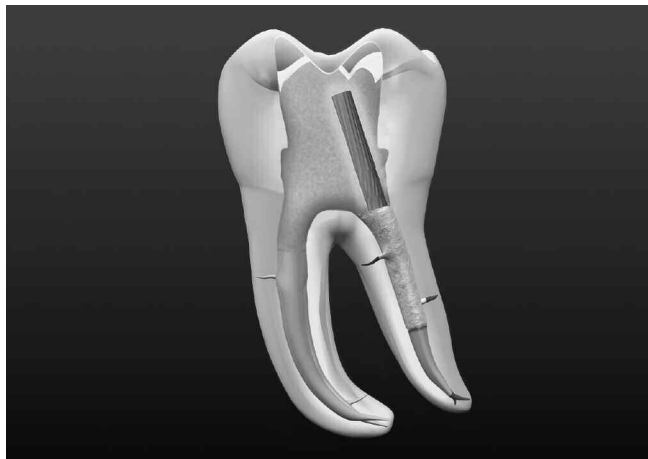


Figure 5a. A graphic demonstrates a mandibular molar with previous endodontic treatment. Note inadequate access, core material inside the pulp chamber and a post.

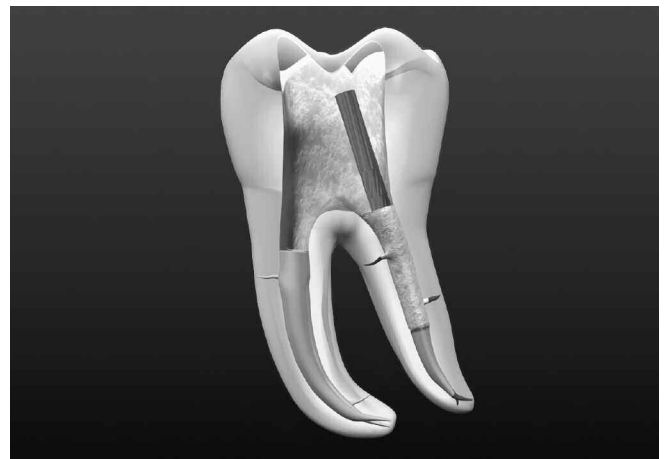

Figure 5b. A graphic shows complete straightline access. Rotary cutting burs and abrasively coated ultrasonic instruments are used to fully expose the post.



Figure 6a. The ProUltra ENDO 1-5 ultrasonic instruments (Dentsply Tulsa Dental; Tulsa, Oklahoma) have an abrasive zirconium nitride coating to improve efficiency, precision and clinical performance.



Figure 6b. The ProUltra ENDO-6, 7 and 8 titanium ultrasonic instruments (Dentsply Tulsa Dental; Tulsa, Oklahoma) provide longer lengths and smaller diameters, and are utilized when space is restrictive.

designed to work in smaller spaces such as between a post and an axial wall. Importantly, a parallel-sided ultrasonic instrument may be safely used below the orifice and lateral to a post, especially in an irregularly shaped canal.²⁴

If space is even more restrictive within the field of operation, then an appropriately sized titanium ultrasonic instrument can be selected and is generally used on a lower intensity. These instruments provide the clinician thinner diameters and longer lengths as compared to abrasively coated or non-coated stainless steel ultrasonic instruments (*Figure 6b*). Ultrasonic instruments are best utilized with a light brush-cutting motion and on the peripheral edge of a sectioned core to chip, break up and sand away materials such as cement, composite or amalgam. Eliminating these materials from the pulp chamber serves to undermine the retention of a post. To optimize vision, virtually all nonsurgical ultrasonic procedures are performed dry. When an abrasively coated ultrasonic instrument contacts, brushes and sands away dentin or a restorative material, then the byproduct of this work is dust. The assistant utilizes the Stropko three-way adapter with the White Mac tip (*Ultradent; South Jordan, Utah*) to direct and control a continuous stream of air into the field. This clinical action serves to blow out debris and, importantly, allows the clinician to maintain visual contact at all times on the energized tip of the instrument.⁹

Water port technology in nonsurgical ultrasonic instruments is contraindicated for four important reasons: One, water flowing through an ultrasonic instrument dampens movement and decreases tip performance. Two, small diameter ultrasonic instruments are weakened and more predisposed to expensive breakage when they are machined for internal water flow. Three, there is an undesirable aerosol effect regardless of where the water port is positioned on an ultrasonic instrument. Four, and most important, water in combination with dentinal dust, creates mud, lost vision and the potential for iatrogenic outcomes. In summary, clinical experience supports the vast majority of all nonsurgical ultrasonic procedures may be performed DRY, at the lowest power setting that will safely accomplish the clinical task. However, if ultrasonic procedures are performed at higher energy levels, for longer periods of time, and against larger, conductive objects, such as a metal post, then it is critically essential that the dental assistant use a triplex syringe with an intermittent water spray to reduce heat build-up and transfer. Fortunately, heat does not conduct well through dentin and is further rapidly dissipated due to the moisture content in the attachment apparatus.²⁵⁻²⁷

TECHNIQUES FOR POST REMOVAL

Once straightline access into the pulp chamber has been accomplished, all core materials eliminated and the post has been fully exposed, then a variety of techniques have been advocated to potentially remove a post.^{13,28-30} It should be appreciated that no one particular method always produces a successful result. As such, clinicians need to be familiar with an escalating range of techniques to maximize success.⁵

ROTONSONIC VIBRATION

Rotosonics is a straightforward method to potentially loosen and remove a fully exposed post. The Regular Tip Roto-Pro bur (*Ellman International; Hewlett, New York*) is a high-speed, friction grip bur whose six faces are joined by six edges and when rotated one revolution, its edges produce six vibrations per revolution. When the instrument is rotated at 200,000 RPM, it produces 1.2 million vibrations per minute, or 20,000 vibrations per second. This instrument provides an inexpensive method to remove certain posts. The bur is kept in intimate contact with the obstruction and is generally carried counterclockwise around the post. Clinically, rotonsonic vibration provides a low tech method to potentially remove a post retained with a more traditional cement such as zinc phosphate.

ULTRASONIC ENERGY

The relative performance among ultrasonic generators commonly used for post removal should be completely understood.³¹ Further, it should be fully appreciated ultrasonic instruments perform optimally when they are designed, manufactured and tuned for a specific generator. Synergistically, a piezoelectric generator in conjunction with a specific ultrasonic instrument may be utilized to transfer energy and potentially dislodge a post (*Figure 7a*).^{17,21,28} The most active distal end of an appropriately designed ultrasonic instrument is kept in intimate contact with the post to maximize energy transfer and promote cement/bond failure. The selected ultrasonic instrument is energized and moved around the post circumferentially and up and down along its exposed length. Again, it must be recognized that the byproduct of ultrasonic energy is heat (*Figure 7b*). When performing ultrasonic procedures for longer periods of time and against larger conductive metal posts, the field should be frequently flushed with water to decrease heat buildup and the potential for dangerous heat transfer to the attachment apparatus (*Figure 7c*).¹⁵ Experience suggests that after removing all circumferential restorative materials, the majority of posts can be safely and successfully removed within approximately 10 minutes (*Figure 7d*).^{18,32}

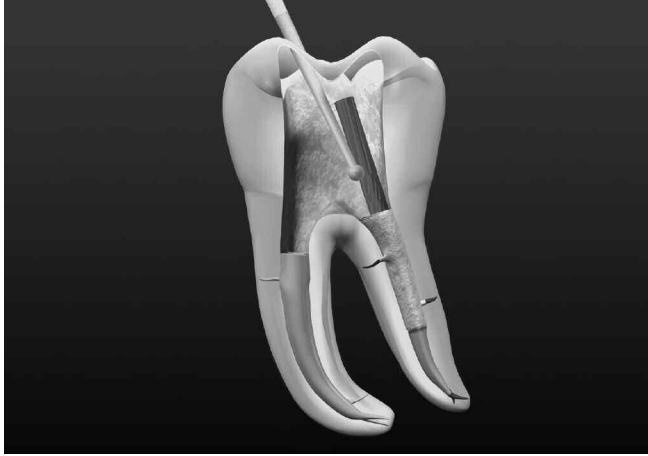


Figure 7a. The ProUltra ENDO-1 is activated and used to powerfully vibrate against all aspects of the exposed post.

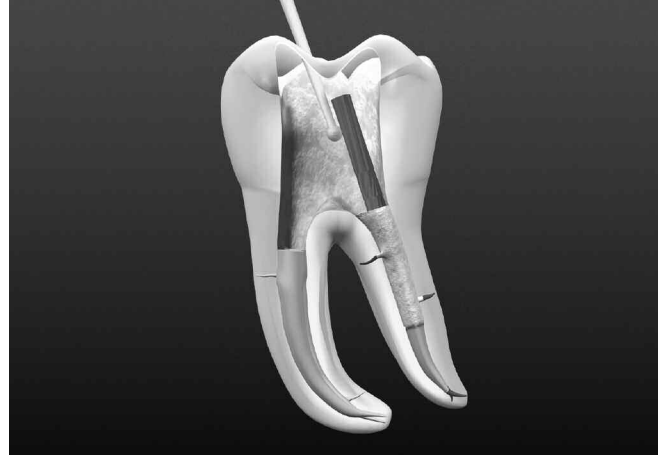

Figure 7b. This graphic serves to illustrate ultrasonic procedures generate heat, particularly when removing larger, more conductive metal posts.

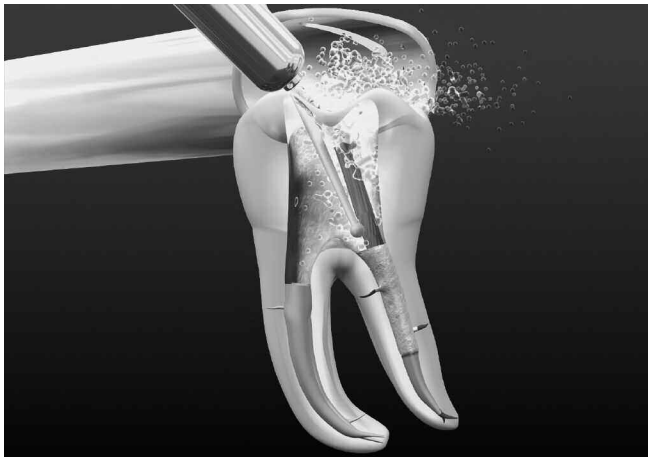

Figure 7c. This graphic demonstrates the importance of using an external water source to reduce temperature and eliminate heat transfer.

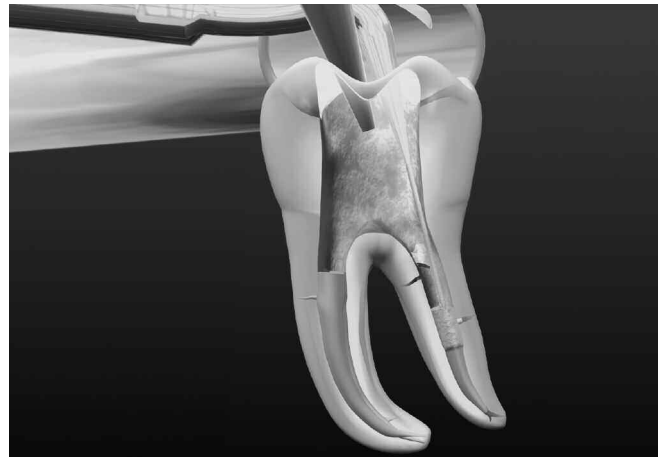


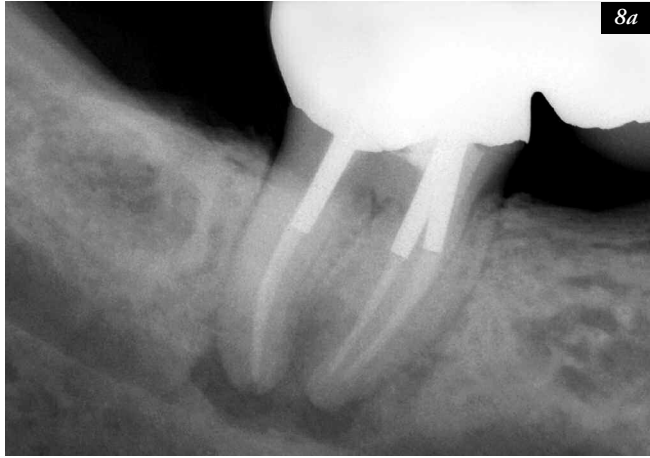
Figure 7d. Following post removal, an ultrasonic instrument breaks up intracanal cement and a White Mac Tip collimates air and blows out debris.

The clinical steps for post removal utilizing sectioning burs and the ultrasonic option are shown in *Figure 8*. Certain posts resist removal even after ultrasonic efforts using the "10-Minute Rule". As such, clinicians need a safe and efficient fall-back position to liberate these posts.³³

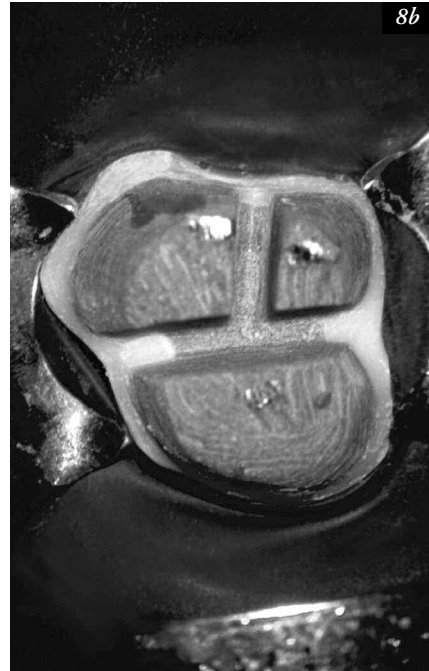MECHANICAL OPTION

A number of different devices have been designed to mechanically remove a post. However, many of these devices, such as the Masserann kit (*Micromega; Besançon, France*) and the Post Puller (*Brasseler USA; Savannah,*

Georgia) have had limited success because they frequently require the excessive removal of tooth structure, which predisposes to ledges, perforations or root fractures. The Gonon post extractor (*EFDM-Pneumat; Bourge, France*) represents a definite improvement over the Masserann and the Post Puller devices in that it is less invasive and has enjoyed good success, but regrettably, for a variety of reasons, by a limited number of clinicians.^{12,13} As such, the Post Removal System (PRS) kit (*SybronEndo; Orange, California*) was developed to provide significant improvements in simplicity, versatility and sizing during post removal procedures (*Figure 9*).



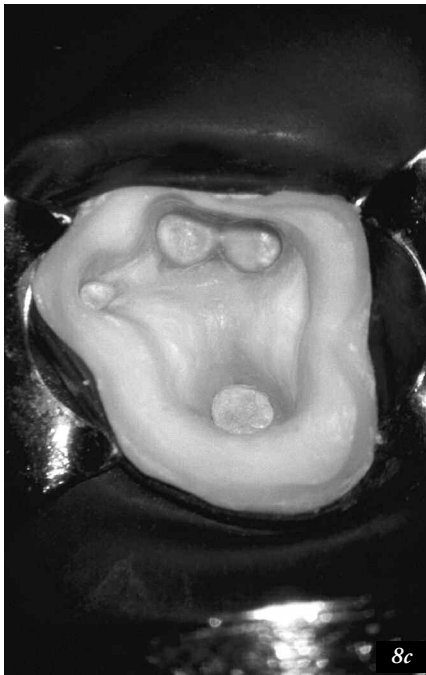
8a



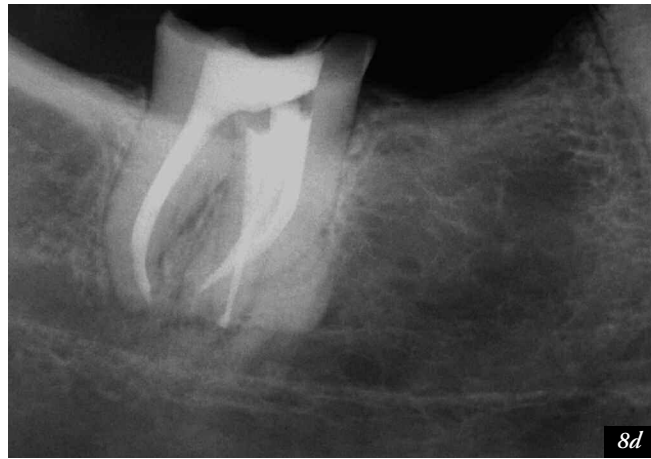
8b

Figure 8a. A pre-operative radiograph of a mandibular right second molar bridge abutment demonstrates three posts, previous endodontics, and apical pathology.

Figure 8b. Following coronal disassembly, the isolated tooth reveals the core sectioned into thirds, the heads of three posts and a marked mesiolingual protuberance.



8c



8d

Figure 8c. The pulp floor is shown following three-dimensional cleaning, shaping, and obturation procedures. Note the displaced most lingual orifice.

Figure 8d. A mesially angulated post-operative radiograph confirms the disassembly efforts and demonstrates the pack, including the displaced lingual system.



Figure 9. The Post Removal System is a kit designed to mechanically engage and potentially remove many different types of posts.

The PRS is designed to mechanically engage and remove different kinds of post types or other intracanal obstructions whose cross-sectional diameters are 0.60 mm or greater.^{9,24} The PRS kit contains extracting pliers, a transmetal bur, five trephines of varying internal diameters, five corresponding tubular taps whose internal diameters range from 0.60-1.60 mm, a torque bar, tube spacers, and a selection of rubber bumpers. The preparatory procedures before utilizing the PRS require straightline access and complete circumferential visualization of the post within the pulp chamber.

A transmetal bur is used to round-off, chamfer or taper the coronal most aspect of the post (*Figure 10a*). "Doming" the head of the post will serve to effectively guide the subsequent instruments over the post. A drop or two of chelator, such as RC Prep, Glyde or ProLube, is then placed on the head of the post to act as a lubricant to facilitate the machining process. In order to ensure circumferential milling, the largest trephine that will just engage the post is selected. The latch-type trephines should rotate at approximately 15,000 RPM in a clockwise (CW) direction, in a slowspeed, high torque handpiece. The trephine is used with a "peck" drilling motion to maintain RPM and to keep the head of the post cooler so it does not work-harden and become more difficult to machine. The trephine is utilized to machine down a 2-3 mm length of the most coronal aspect of the exposed post (*Figure 10b*). If the chosen trephine fits passively, then a sequentially smaller size trephine is selected to ensure proper circumferential milling. In some instances the configuration of the coronal most aspect of the post, such as a cast post/core, dictates the use of a transmetal bur or diamond to grind down the head of the post to create a relatively round cylinder. The trephine can then machine a precisely round cross-sectional diameter on the post.

Generally, the trephine used for machining the post dictates the subsequent selection of a correspondingly sized tubular tap. An appropriately sized rubber bumper is selected and inserted over the distal end of the tap. The bumper serves to cushion, evenly distribute the loads and protect the tooth during the removal procedure. The tubular tap is pushed against the head of the milled down post and is manually turned counterclockwise (CCW) to form threads (*Figure 10c*). Firm apical pressure and small quarter-turn CCW motions will generally draw-down and securely engage the tap to the post. The tap can be screwed over the post as little as 1 mm or, more optimally, up to a maximum of 3 mm. Caution should be exercised so that the tap is not drawn down too far over the post because its maximum internal depth is 4 mm. If the tap bottoms out against the post head, it can predispose to stripping the threads, breaking the wall of the tap, or shearing off the obstruction inside the lumen of the tap. When the tubular tap has snugly engaged the post, the protective rubber bumper is pushed down onto the biting surface of the tooth (*Figure 10d*).

The post removal pliers are then selected and the extracting jaws are mounted onto the tubular tap. The instrument is held securely with one hand, while the fingers of the other hand begin opening the jaws by turning the screw knob clockwise. As the jaws slowly begin to open, increasing pressure will be noted on the screw knob. The clinician should repeatedly verify that the compressing rubber cushion is properly protecting the tooth. Further, when utilizing this removal method, the clinician should visually confirm the post is being safely withdrawn along the long axis of the root canal. If turning the screw knob becomes increasingly difficult, the clinician should either hesitate a few seconds before continuing and/or use the indirect ultrasonic technique to vibrate on the post-engaged tubular tap (*Figure 10e*). In combination, the PRS and indirect ultrasonic techniques enhance post retention failure, encourage the screw knob to turn further, and are potent adjuncts to successful post removal (*Figure 10f*).³³ Ultimately, the PRS provides clinicians an important post removal method that can be safely employed when ultrasonic techniques are unsuccessful (*Figure 11*).

Clinicians also encounter actively engaged threaded posts which require removal. The PRS is specifically designed to address this scenario because each tubular tap turns in a CCW rotation. The post head is milled down as previously described and a tubular tap threaded until snug. In instances where threaded posts are encountered, the use of the extracting pliers is contra-indicated. Typically, the clinician backs the post out of the canal using a CCW rotation with finger pressure. If the post is strongly anchored, an ultrasonic instrument may be used to vibrate on the tap and, if necessary, the torque bar is inserted into the handle port to increase leverage (*Figure 12*).

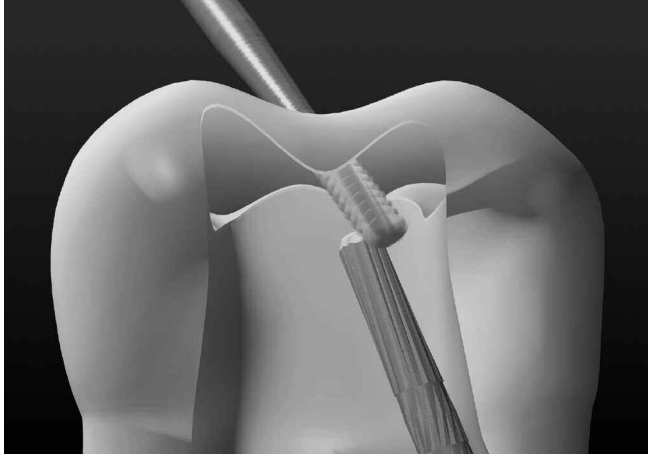


Figure 10a. A graphic depicting a transmetal bur efficiently doming the post head.

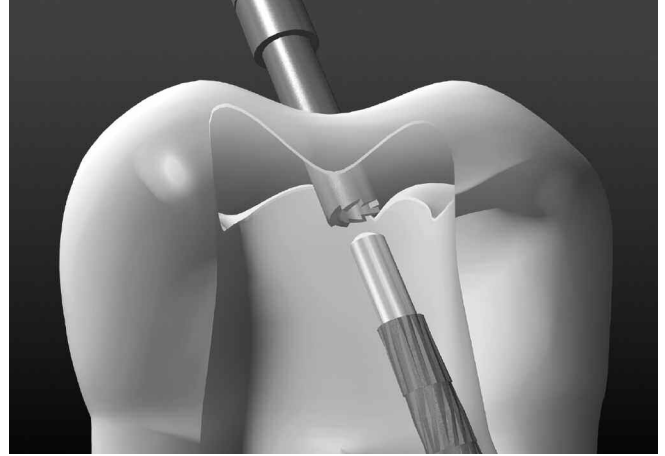


Figure 10b. A graphic depicts that the No. 3 trephine has precisely machined down the coronal 3 mm of the post.

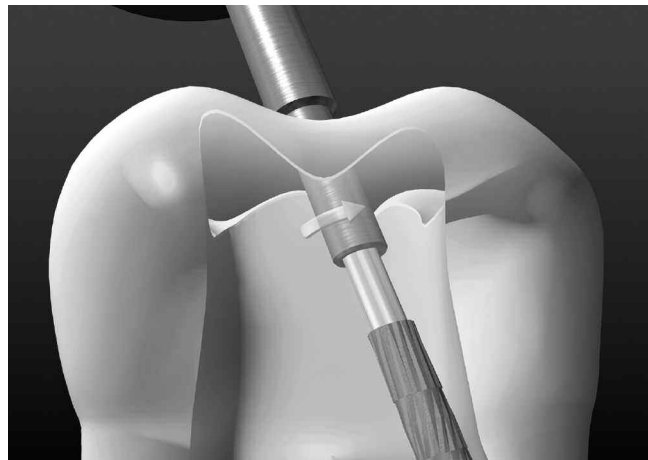


Figure 10c. This graphic demonstrates the tubular tap is turned CCW to form threads, draw down and strongly engage the post.




Figure 10d. A graphic shows that once the tap is securely engaged to the post then the rubber bumper is seated against the occlusal surface to protect the tooth.




Figure 10e. A graphic demonstrates the mounted and activated PRS extracting plier. Note the energized ProUltra ENDO-1 may advantageously be placed against the post-engaged tap to synergistically facilitate the removal effort.

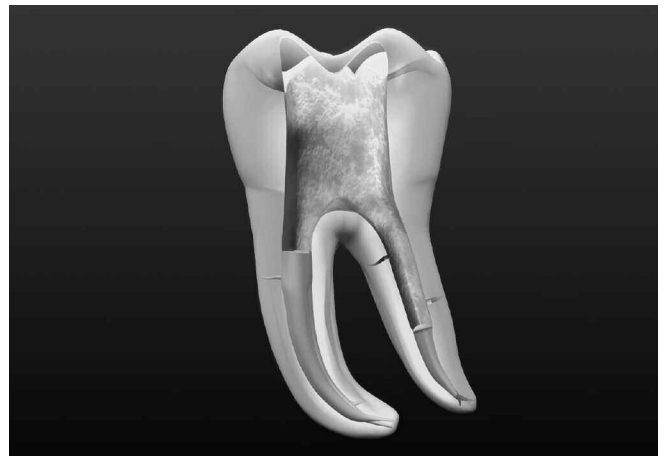

Figure 10f. This graphic demonstrates post removal. Attention can now be directed towards selecting the best gutta percha removal scheme.

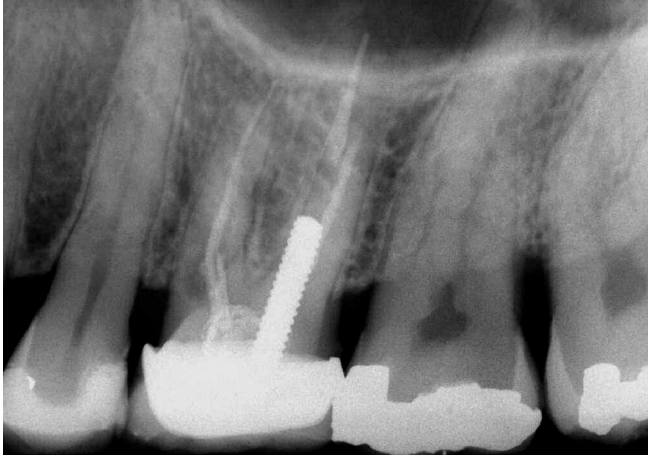


Figure 11a. A radiograph shows incomplete endodontics and resultant failure. Note the poor fitting crown, internal resorption, furcal involvement and the large post.

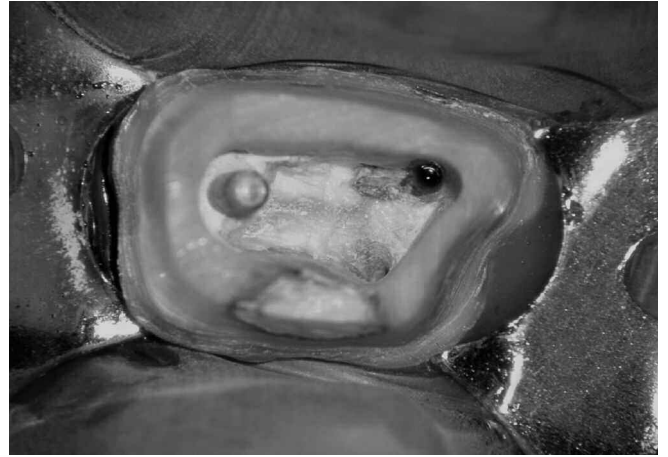
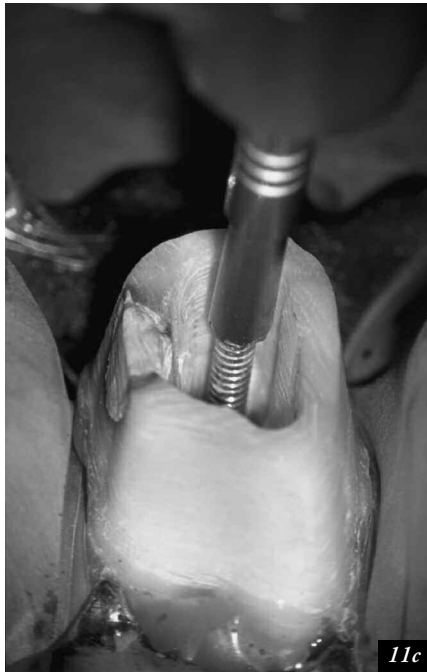

Figure 11b. Straightline access demonstrates the fully exposed post, bleeding from the MB1 orifice and evidence of an MBII orifice/system.



11c



11d

Figure 11c. A selected trephine precisely machines the coronal 2-3 mm of the post.

Figure 11d. A photo depicts the mounted extracting plier, compression of the protective rubber cushion, and an ultrasonic instrument vibrating on the engaged tap.

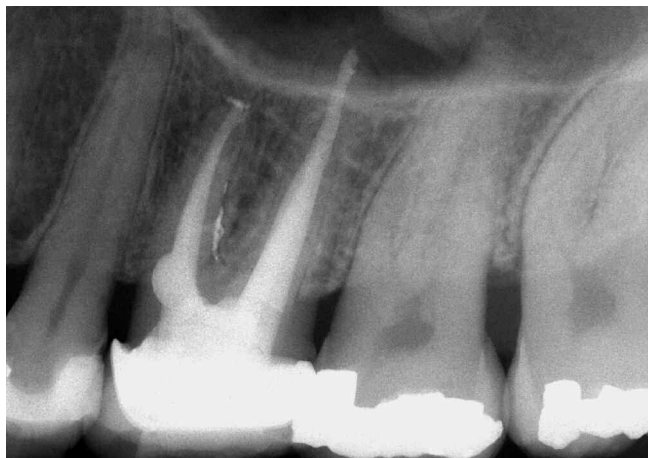

Figure 11e. An off-angled radiograph reveals a well-packed resorptive defect, a furcal canal and the provisionalized PFM crown.

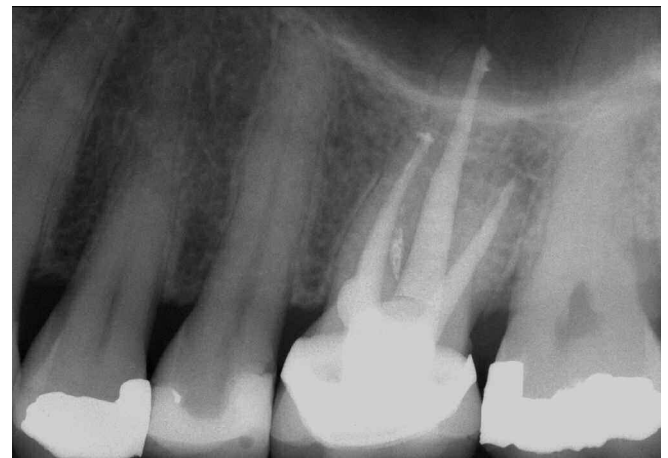

Figure 11f. A 4-year recall shows a new restoration and endodontic healing.

SPECIAL CIRCUMSTANCES

The extracting pliers have two arms that operate around a pivot joint and are activated by turning a screw knob. The optimal extracting force on the post occurs during the initial travel and early separation of the extracting pliers' arms. During this early travel, the extracting force is "on-axis" as the outward pull on the post is aligned and parallel to the long axis of the root canal. As the arms move further apart, the extracting force on the post subtly shifts to "off-axis" and deviates from the actual path of post insertion. Re-orienting the removal force to parallel the long axis of the root is accomplished by selecting one of the following two solutions.

- (1) When the removal force is off-axis, then the screw knob is turned CCW to deactivate and close the arms. Space will now exist between the arm approximating the occlusal surface and the rubber bumper. One or more

additional bumpers is selected and a cut is made from the outer edge of the rubber to the center hole. The bumper is gently opened along this cut and stretched over the engaged tap. The bumper is rotated so the cut is aligned perpendicular to the arms of the extracting pliers. Once remounted, the activated arms will be closer together to more optimally direct the force along the long axis of the root canal.

- (2) Infrequently, but on occasion, the extracting pliers' arms become fully separated without removing the post. Because there is a limitation in the number of auxiliary bumpers that can be placed, an alternative technique should be used. The extracting pliers are de-activated and dismantled. The engaged tap is backed off the post by turning its handle CW and the rubber bumper removed. Doughnut shaped metal spacers or shims can be fabricated to correspond to a thickness of 1, 2 or 3 mm.¹² A metal spacer, or combination of spacers, is placed over the

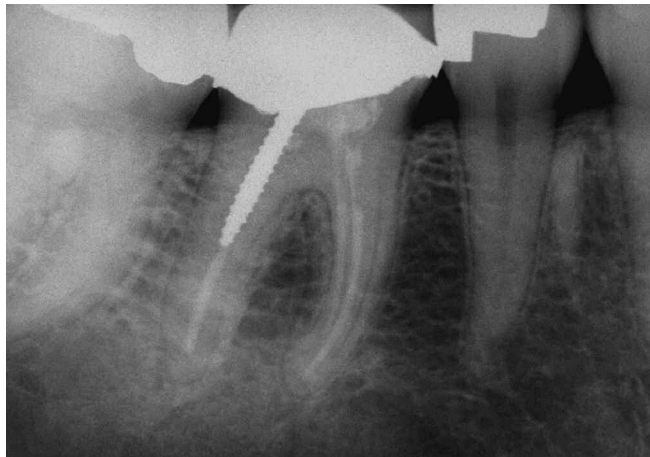


Figure 12a. A radiograph of a mandibular right first molar demonstrates a PFM crown, a screw post and inadequate endodontic treatment.

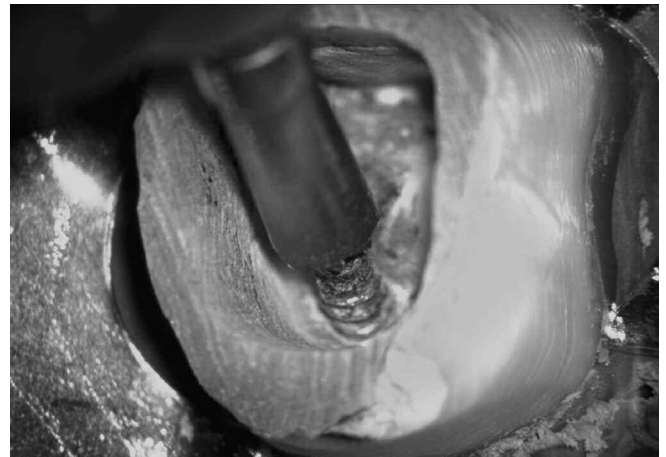

Figure 12b. A clinical photo demonstrates a tap forming threads and being drawn-down to tightly engage the post.

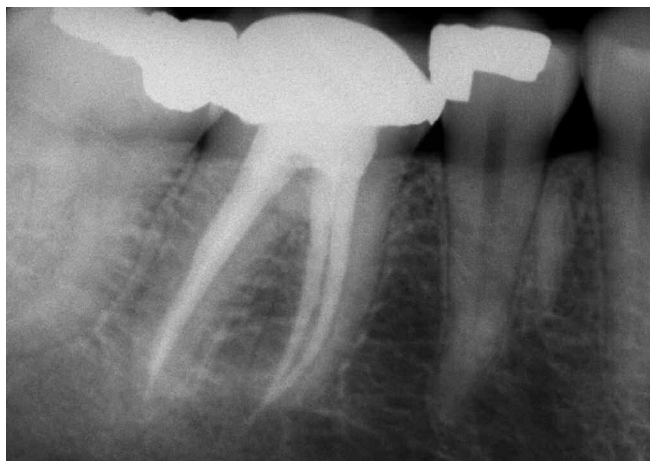


Figure 12c. A post-operative film shows the re-cemented crown and the retreatment efforts.

working end of the tap followed by a protective rubber bumper. The assembled tap is threaded back on the post until snug. Once the extracting pliers are remounted the arms will be closer together which will safely align the removal forces along the long axis of the root canal (*Figure 13*).

Inadvertent Tap “Pop-Off”

Occasionally, when utilizing the PRS, an engaged tap may inadvertently slip and “pop-off” the post. This loss of engagement results when an excessive removal load strips the threads on the post. In this instance, there are two fallback options:

- (1) When space is available, the trephine may be used to machine down the head of the exposed post one or two additional millimeters. The same tap that popped off is utilized again and rotated in a CCW direction to screw it down further and re-engage the post. Post removal techniques may now be performed as previously described.
- (2) If space is not available along the length of the exposed post, then the next smaller sized trephine is selected. A smaller sized trephine will dictate the selection of the correspondingly sized smaller tubular tap. The clinician should appreciate a smaller tap, even when snugged

down, is less retentive as it engages a smaller surface area. Post removal techniques may now be performed as previously described.

Avoiding Post “Shear-Off”

When the coronal most aspect of the post has been machined down with the smaller sized trephines, progressively smaller diameters result. Caution must be exercised when drawing down the tap so the part of the post within the lumen of the engaging instrument does not “shear-off”. A lubricant encourages the tap to form threads on the prepared post and reduces the tendency for shear-off. Another method that reduces the chance of shear-off is limiting the rotation on the handle of the tap to 60-90° during each partial CCW rotation. Additionally, after each partial CCW rotation, back off the tap by turning its handle approximately 30° CW. This progressive CCW / CW reciprocating motion reduces the risk of shearing off the post inside the lumen of the tap. In the event there is post head shear-off, the post removal procedure is started again, albeit more apical. When the post has been successfully removed from a root, be mindful of rotating the tap handle CW to disengage the tap from the post. When the head of a post does shear-off inside the tap it generally renders the tap useless.




Figure 13a. A clinical photo demonstrates that when the arms of the pliers move too far apart, the extracting force is not aligned with the long axis of the canal.



Figure 13b. A photo shows a tubular tap, a rubber bumper, and two doughnut-shaped metal spacer tubes of varying thickness.




Figure 13c. A clinical photo shows that spacer tubes bring the arms of the extracting pliers closer together to safely re-align the removal loads from off-axis to on-axis.

Using the PRS on Anterior Teeth

Clinicians can carefully remove posts from the roots of anterior teeth with the PRS kit. Because natural or restored anterior teeth have thin dimensions facial-lingual toward their middle and incisal one-thirds, special attention is required during post removal procedures to prevent fractures. If the incisal edges of the anterior teeth essentially lie on the same plane, then the post removal loads may be distributed over multiple teeth. Two or three wooden tongue depressors can be customized to lay across the incisal edges and once positioned can be stabilized with any adhesive restorative material. The extracting pliers' gingival arm can brace against this working platform to redistribute the total removal load from one tooth to several teeth. It should be appreciated if the post removal force is not against the root that holds the post then tooth extraction could result. Therefore, in this method of removal, it is wise to keep an eye on the tooth holding the post to ensure it is not inadvertently elevated out of its socket.

BROKEN INSTRUMENT REMOVAL

Every clinician who has performed endodontics has experienced a variety of emotions ranging from the thrill-of-the-fill to an upset like the procedural accident of breaking an instrument. During root canal preparation procedures, the potential for instrument breakage is always present. When instrument breakage occurs, it immediately provokes frustration, despair and anxiety.³⁴ In fact, the broken instrument dilemma has caused such emotional distress that this event is frequently referred to as a "separated" or "disarticulated" file.

Many clinicians associate a "broken instrument" with a separated file, but the term could also apply to a sectioned silver point, a segment of a lentulo, a gates glidden drill, a portion of a carrier-based obturator, or any other device obstructing the canal.^{35,36} With the advent of rotary NiTi files, there has been an unfortunate increase in the occurrence of broken instruments and the factors contributing to breakage have been identified.^{37,38} The prognosis of leaving, versus removing broken instruments from the canal have been discussed in the literature.^{39,40} Over the years a variety of approaches for managing broken instruments have been presented.⁴¹⁻⁴³

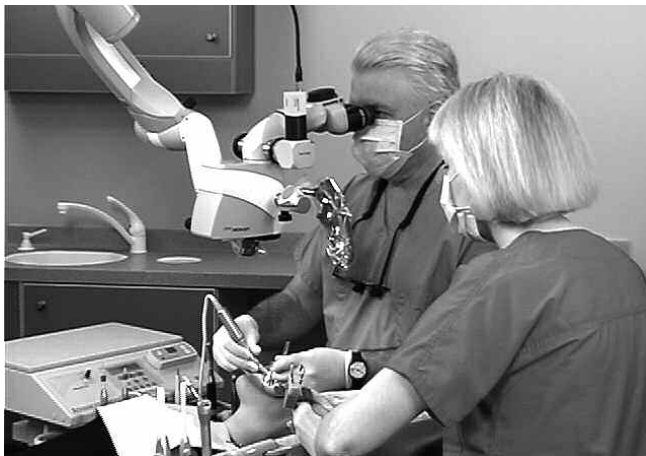

Figure 14. The dental operating microscope (Carl Zeiss; Thornwood, New York) provides many features to facilitate vision, ergonomics and documentation.

Today, separated instruments can usually be removed due to technological advancements in vision, ultrasonic instrumentation, and microtube delivery methods.^{44,45} Specifically, the increasing integration of the dental operating microscope into clinical practice is allowing clinicians to visualize the most coronal aspect of most broken instruments.⁴⁶ The microscope fulfills the age old adage, "If you can see it, you can probably do it". In combination, the microscope and ultrasonic instrumentation have driven "microsonic" techniques which have dramatically improved the potential and safety of removing broken instruments (*Figure 14*).^{5,47,48}

FACTORS INFLUENCING BROKEN INSTRUMENT REMOVAL

The factors influencing broken instrument removal should be identified and fully appreciated.^{49,50} The ability to nonsurgically access and remove a broken instrument will be influenced by the diameter, length and position of the obstruction within a canal. Additionally, the potential to safely remove a broken instrument is guided by anatomy, including the diameter, length, and curvature of the canal. Importantly, the potential for safely removing a broken instrument is limited by root morphology, including the circumferential dimensions and thickness of dentin and the depth of an external concavity.^{51,52} In general, if one-third of the overall length of an obstruction can be exposed, it can usually be removed. Instruments that lie in the straightway portions of the canal can typically be removed. Separated instruments that lie partially around canal curvatures, although more difficult, can oftentimes be removed if straightline access can be established to their most coronal extents (*Figure 15*).^{5,48,53} If the broken instrument segment is apical to the curvature of the canal and safe access cannot be accomplished, then removal is usually not possible and, in the presence of signs or symptoms, surgery or an extraction will at times be required.

The type of material comprising an obstruction is another important factor to be considered. As an example, stainless steel files tend to be easier to remove as, in general, they do not further fracture during the removal process. Nickel-titanium broken instruments may break again, albeit deeper within the canal, during ultrasonic efforts presumably due to heat buildup.⁵⁴ Perhaps the most important factors central to successful instrument removal are knowledge, training and competency in selecting the best presently developed and proven technologies and techniques. Importantly, no one removal method will always produce the desired result. As such, successful removal oftentimes requires patience, perseverance and creativity. However, no removal method should be attempted until access has been made to the head of an intracanal obstruction.

CORONAL AND RADICULAR ACCESS

Prior to commencing with efforts to remove a broken instrument, the clinician should thoughtfully observe different horizontally angulated pre-operative radiographs. Coronal access is the first step in the removal of broken instruments. Highspeed, friction grip, surgical length burs are selected to create straightline access to all canal orifices. Special attention should be directed towards flaring the axial wall that

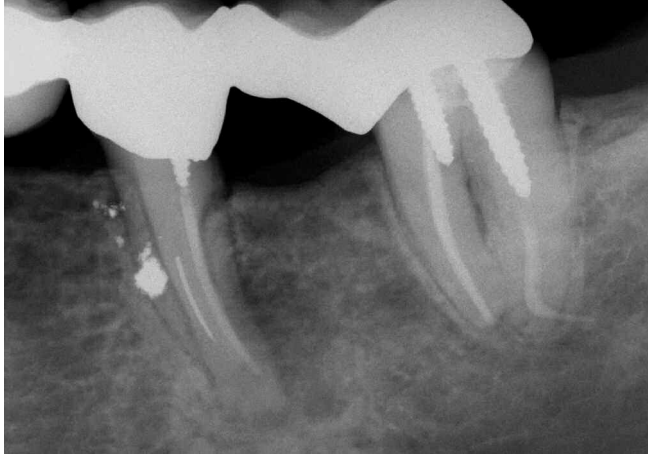

Figure 15a. An endodontically failing mandibular first molar. Note a short screw post, a separated instrument and amalgam debris from the hemisection procedures.

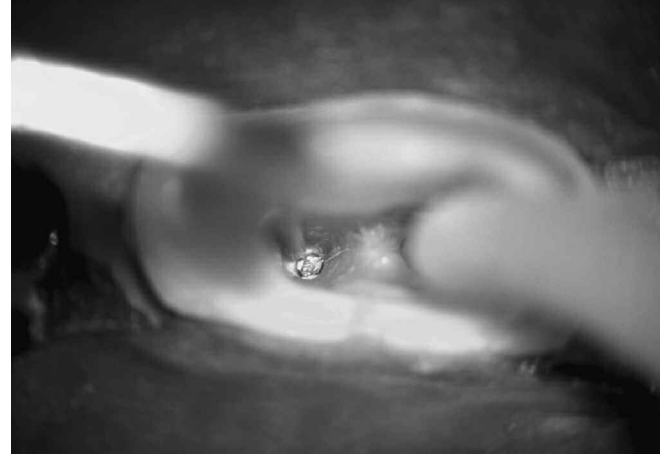


Figure 15b. A photograph shows the splint removed, the post out, and an ultrasonic instrument trephining around the broken file.

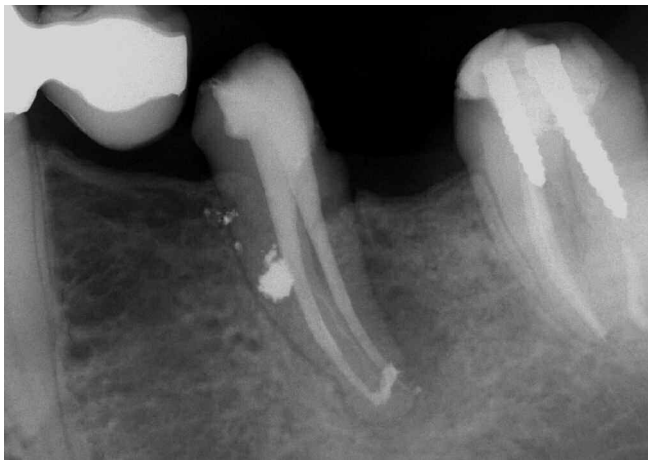

Figure 15c. A post-treatment radiograph reveals three-dimensional retreatment. Note the third mesial system between the MB and ML canals.

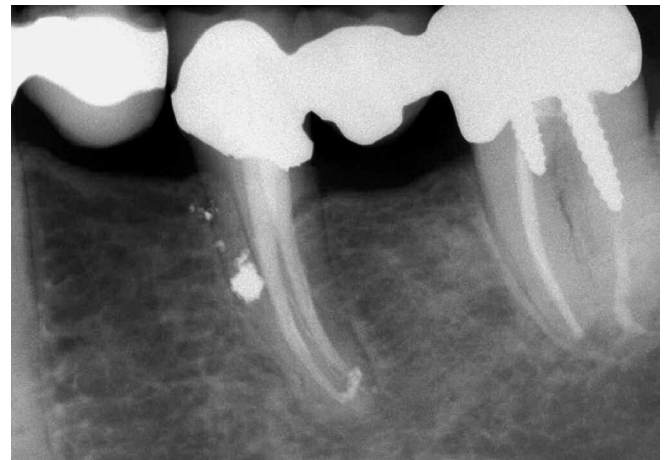

Figure 15d. An 8-year recall film demonstrates a new bridge and excellent periradicular healing.

approximates the canal holding the broken instrument in efforts to subsequently improve microsonic techniques below the orifice.

Radicular access is the second step required in the successful removal of a broken instrument. However, before commencing with radicular access, it is useful to review a few concepts that can potentially guide our clinical actions. With exceptions, the vast majority of teeth range from 19-25 mm in overall length. Most clinical crowns are about 10 mm and most roots range from 9-15 mm in length. If the root is divided into coronal, middle and apical one-thirds, then each third is between 3 and 5 mm in length. The question frequently asked is how big can a canal be optimally flared without creating an iatrogenic problem. The answer is to review the dimensions of a typical preparation in a longer, thinner and more curved root form (10). In this situation, if a 20 file is snug at length and each successively larger instrument uniformly moves away from the foramen in 1/2 mm increments, then the apical one-third of the canal would

taper 10%. In this specific example, the diameter of the canal 4 mm coronal to the foramen would be equivalent to at least a 60 file or 0.60 mm. This analogy is useful and can serve to safely guide how big to prepare a canal when there is a broken instrument.⁵⁵ Clinical experience suggests the majority of broken files separate towards their terminal extents at between D₃, D₄ or D₅. Files most frequently break in the apical 3-5 mm because this is the region where a canal usually exhibits its greatest degree of curvature or propensity to divide. Even if a file breaks at the working length, the position of the head of the instrument typically lies at about the junction of the middle and apical one-thirds. Fortunately, straightline radicular access can generally be created through the coronal two-thirds of a canal to the head of a broken instrument.^{5,53}

A number of different techniques may be employed to flare the canal coronal to an intracanal obstruction. However, experience suggests a predictable way to create safe radicular access is to initially use hand files, small to large, coronal to

the obstruction. Hand files create sufficient space to safely accommodate Gates Glidden (GG) drills (*Dentsply Maillefer; Tulsa, Oklahoma*). GG sizes 1 to 4 are most typically employed in furcated teeth and have maximum diameters of 0.50, 0.70, 0.90 and 1.10 mm, respectively. GG's are used to create radicular access and a uniform tapering funnel to the obstruction. GG's are more safely rotated at speeds of about 750 RPM and, importantly, are safely used with a "brushing motion" to create a tapered shape and maximize visibility.⁵⁵ Increasingly larger GG's are uniformly stepped out of the canal to create a smooth flowing funnel which is largest at the orifice and narrowest at the obstruction. GG drills should be limited to the straightaway portions of the canal. Generally, a GG-1 or GG-2 can be carried to the depth of the head of a separated instrument. The GG's are used cautiously in approximation to the obstruction with attention to brush-cutting out of the canal and away from furcal danger. Deliberately relocating the coronal one-third of a canal away from the furcation maximizes remaining dentin, produces a more centered preparation, and improves straightline radicular access.^{55,56} The GG-3 is carried short of the level where the GG-2 was used and, in furcated teeth, the GG-4 is confined to a depth of no more than one bud length below the orifice. Importantly, radicular access should be performed so that the canal is pre-enlarged and ideally shaped "no bigger" than it would otherwise be prepared if there was no broken instrument obstructing the canal.

CREATING A STAGING PLATFORM

When the canal has been optimally shaped, then microsonic techniques are usually the first option selected to remove a broken file segment. At times, when an ultrasonic instrument is introduced into a pre-enlarged canal, its activated tip does not have enough space, lateral to the broken file segment, to initiate trephining procedures. As such, if more lateral space is required, then the bud of a GG can be "modified" and used to create a circumferential "staging platform".^{5,54} The staging platform is made by selecting a GG drill whose maximum cross-sectional diameter is slightly larger than the visualized instrument. The bud of the GG drill

is altered by cutting it perpendicular to its long axis at its maximum cross-sectional diameter (*Figure 16*). This modified GG is carried into the pre-enlarged canal, rotated at a reduced speed of approximately 300 RPM, and directed apically until it lightly contacts the most coronal aspect of the obstruction. This clinical step creates a small staging platform which facilitates the introduction of an ultrasonic instrument. If properly performed, straightline coronal and radicular access, in conjunction with magnification and lighting, should enable the clinician to fully visualize the coronal most aspect of a broken instrument. To facilitate excellent vision to the intra-radicular obstruction, the canal should be vigorously flushed and thoroughly dried prior to beginning ultrasonic procedures.

TECHNIQUES FOR REMOVING BROKEN INSTRUMENTS

A number of devices, technologies and techniques have been reported to remove an intracanal obstruction such as a broken instrument.⁵⁷⁻⁵⁹ However, many of the removal techniques previously described in the literature did not have the benefit of the operating microscope. Today, virtually all broken instruments can be eliminated if straightline access can be safely made to the coronal most extent of a broken instrument.^{5,48,53} The most important, predictable and safe removal schemes utilize the microscope in conjunction with optimally designed ultrasonic instruments and/or a microtube method.^{53,54,60}

ULTRASONIC TECHNIQUES

Prior to performing any radicular removal techniques, it is wise to place cotton pellets over other exposed orifices, if present, to prevent the nuisance re-entry of the fragment into another canal system. The first option to remove a broken instrument is to utilize piezoelectric ultrasonic technology and specific ultrasonic instruments (*Figure 6*). An ultrasonic generator should provide a broad range of power, precise adjustment within the lower settings and electrical feedback to regulate amplitude and safe tip movement. Ideally, ultrasonic




Figure 16. A photograph showing selected GG drills and their subsequent modification.

instruments should have a contra-angled design to provide access into all regions of the mouth, parallel-sided walls to create a line of sight between the instrument and the tapered canal, and non-aggressive coatings, such as zirconium nitride, to precisely sand away dentin during trephining procedures. Further, an appropriately sized ultrasonic instrument is selected, such that its length will reach the broken obstruction and its diameter will passively fit and afford a favorable line-of-sight into the previously shaped canal. The tip of this ultrasonic instrument is placed in intimate contact against the obstruction and typically activated within the lower power settings (*Figure 17a*). The clinician should always work at the lowest power setting that will efficiently and safely accomplish the clinical task. ALL ultrasonic work below the orifice is conducted DRY so the clinician has constant visualization of the energized tip against the broken instrument. To maintain vision, the dental assistant utilizes the Stropko three-way adapter with an appropriate luer-lock tip to collimate and direct a continuous stream of air and blow out dentinal dust. Microsonic techniques, as advocated for removing broken instruments, do not generally generate sufficient heat to become harmful to the attachment apparatus.

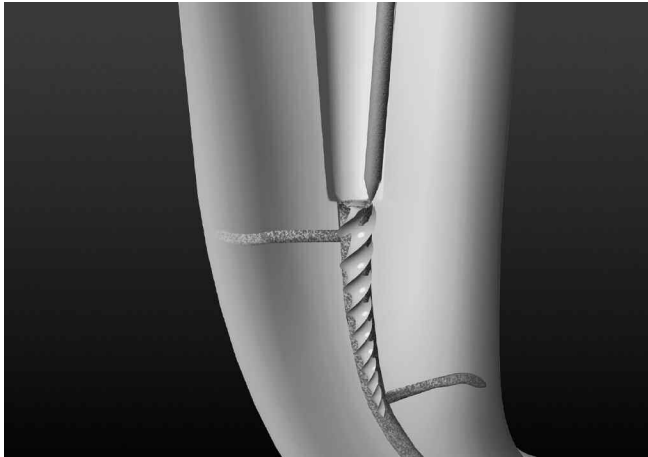
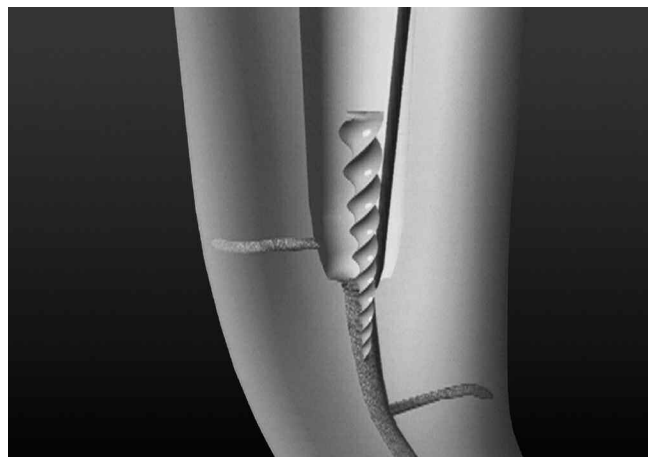


Figure 17a. A graphic demonstrates the importance of coronal and radicular access, the staging platform and the ultrasonic instrument just lateral to the broken file.



The selected ultrasonic instrument is moved lightly, in a CCW direction, around the obstruction, except when removing a file that has a left-handed thread in which case the direction would be CW. This ultrasonic action trephines, precisely sands away dentin and exposes the coronal few millimeters of the obstruction (*Figure 17b*). Typically, during ultrasonic use, the obstruction begins to loosen, unwind and then spin. Gently wedging the energized tip between the tapered file and canal wall oftentimes causes the broken instrument to abruptly “jump out” of the canal. In the instance where a broken file lies deep and ultrasonic procedures are restricted by root bulk and form, then select a longer length and smaller diameter, abrasively coated, ultrasonic instrument to promote safe retrieval efforts. In longer roots, or when space is even more restrictive, then an appropriately sized titanium instrument may be chosen. Titanium instruments provide a smooth cutting action which promotes safety when trephining deeper within a canal (*Figure 17c*). At times, weighing risk versus benefit, ultrasonic trephining procedures may have to be aborted. In these instances, the sharp cutting edges of a hypodermic needle may be safely used manually to further expose the head of a broken file.⁶¹ Exposing 2-3 mm of the coronal most aspect of an obstruction, or about

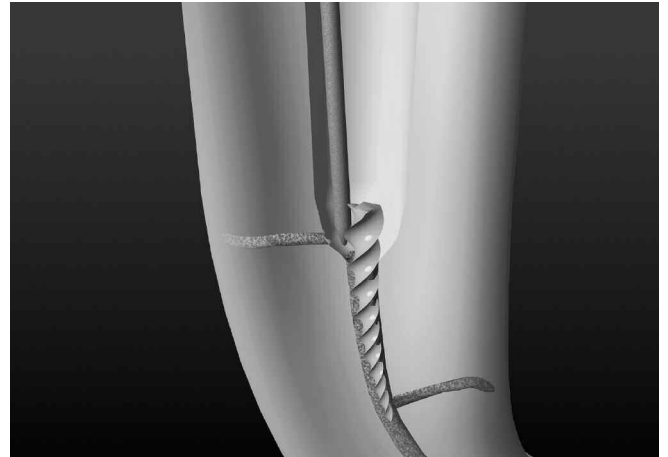


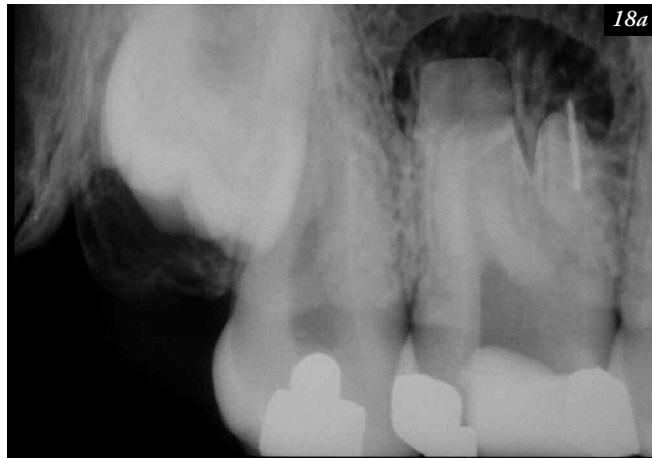Figure 17b. The ultrasonic instrument maintains contact with the broken file, precisely sands away dentin, and progressively exposes the coronal aspect of the broken file.

Figure 17c. A graphic demonstrates a longer length and smaller diameter titanium instrument is selected to conserve dentin and successfully displace the broken instrument.

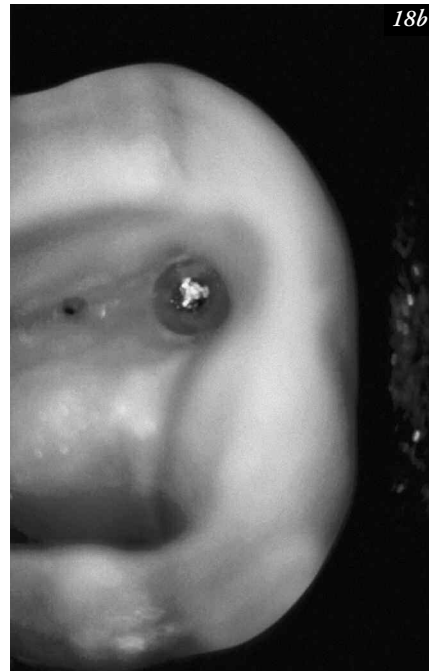
one-third of its overall length, will generally produce the desired result. The clinical steps for broken instrument removal utilizing microsonics are shown in *Figure 18*.

On occasion, the clinician may create excellent coronal and radicular access, identify and expose the separated instrument, perform ultrasonic trephining procedures, and still be unable to loosen and “jettison” the instrument out of the canal. Further, it may be unsafe to continue trephining around a broken instrument due to lack of vision or anatomical restrictions. In this instance, small hand files may be used with an aqueous or viscous chelator, to partially or completely bypass and, hopefully, remove a broken instrument. Even when this tedious removal method is unsuccessful, oftentimes a little space can be created along a portion of the overall length of a broken instrument. To maximize efficiency

and success, the handle from a stainless steel hand file can be intentionally removed and the shaft of the instrument inserted into a device called the File Adapter (*SybronEndo; Orange, California*). The File Adapter threads onto the ultrasonic handpiece and its chuck will retain a 0.02 tapered hand file. Small, stainless steel hand files can be precurved, if indicated, inserted into available space and used at low power in an ultrasonic effort to remove a broken instrument. This technique is, at times, useful when the root is thin or a portion of the file lies apical to a canal curvature.⁶² Another clinical challenge is encountered when trying to remove a broken NiTi file that lies partially around a canal curvature. In these situations, it is axiomatic the head of a broken NiTi file will always lie against the outer wall even after optimal ultrasonic trephining procedures. Even when loose, the angle



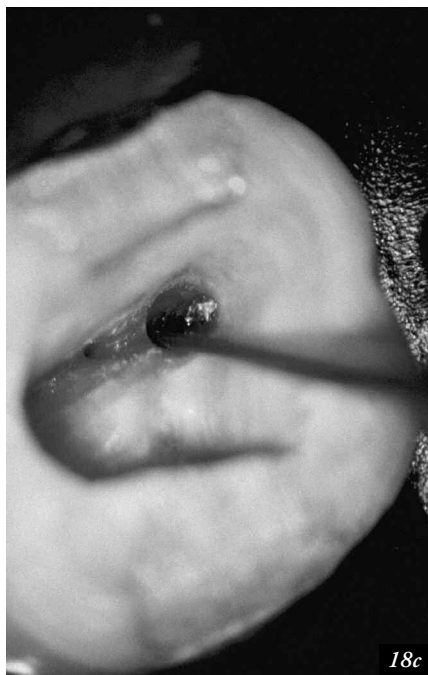18a



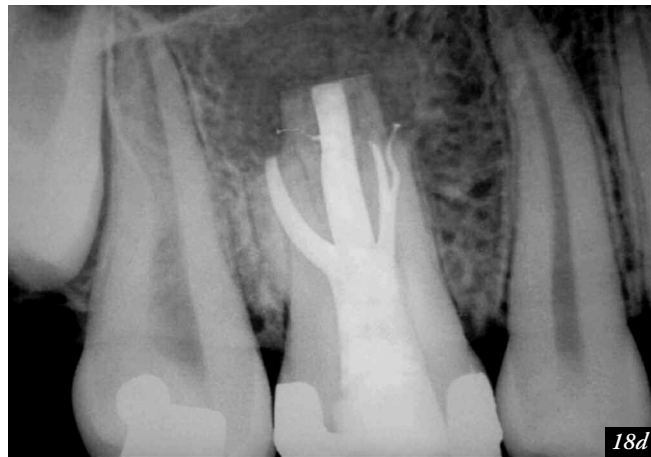18b

Figure 18a. An off-angled film of a maxillary first molar reveals a broken instrument, a possible MBII system and resected roots from previous surgery.

Figure 18b. A photograph demonstrates access, an MBII orifice, the broken instrument, and the circumferential staging platform to facilitate ultrasonics.



18c



18d

Figure 18c. Documentation reveals an ultrasonic instrument has loosened and coronally displaced the broken instrument.

Figure 18d. A recall film demonstrates initial healing. Barriers were utilized in the DB and P canals to facilitate control and encourage 3D filling.

formed between the coronally flared canal and the head of the broken instrument oftentimes precludes its removal. This situation is best managed using a microtube removal method (*Figure 19*).^{5,63}

MICROTUBE REMOVAL METHODS

There are several microtube removal methods, both old and new, that are designed to mechanically engage an intracanal obstruction, like a broken instrument. However, it must be understood and fully appreciated that many, if not most, of these microtube removal methods frequently require the excessive removal of dentin and/or oftentimes prove ineffective. For clinicians, the critical distinction when considering microtube removal methods is not the inside diameter of a device, but importantly, its outside diameter. Ultimately, the outside diameter of a device dictates how deep it can be safely introduced into a canal. Further, many of the advocated microtube removal methods occurred prior to the introduction of microscopes, better designed ultrasonic

instruments and innovative new technologies. In fact, most of the time-honored techniques and even many of the newer methods, even when successful, dangerously weakened the root due to overzealous canal enlargement. Indeed, an over-enlarged canal structurally weakens the root, and predisposes to a ledge, perforation or fracture. However, failure to remove a broken instrument compromises shaping procedures and the potential to clean and fill the root canal system. The following represents the various microtube removal methods and techniques.

- *Lasso & Anchor*: In this removal method, an appropriately sized microtube is selected and a wire passed through the tube then looped at one end and passed back through the tube. This loop can potentially lasso a coronally exposed obstruction and, when successful, form a purchase by pushing the tube apically while simultaneously pulling the wire ends coronally.⁶³ Although reported in the literature, this removal method has been essentially replaced with more practical or successful techniques.

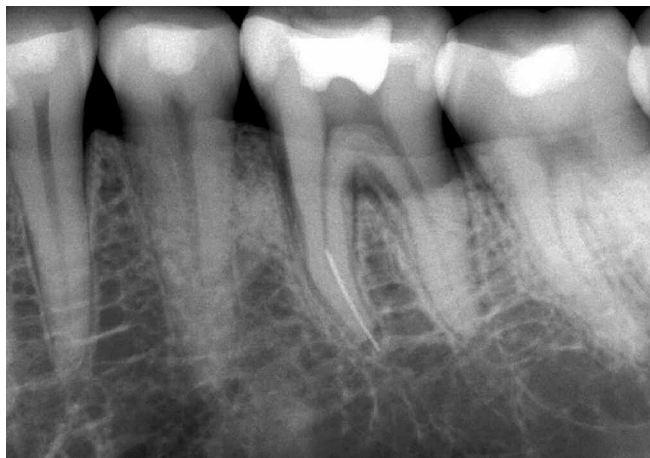

Figure 19a. A pre-operative film of a mandibular left first molar with a broken instrument in the apical one-third of the mesial root.

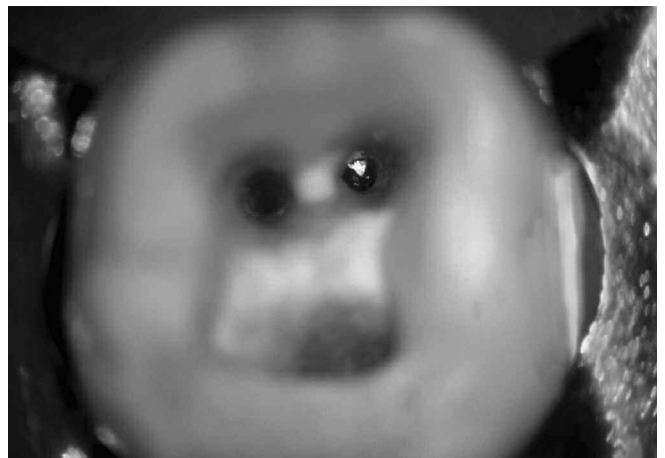

Figure 19b. After refining access and completing ultrasonic procedures, a photograph reveals the head of the broken NiTi file predictably against the outer wall.

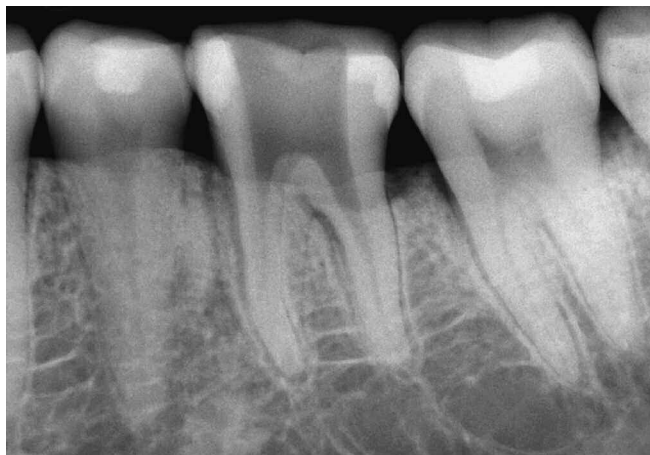

Figure 19c. A radiograph confirms straightline access and the removal of the broken file.

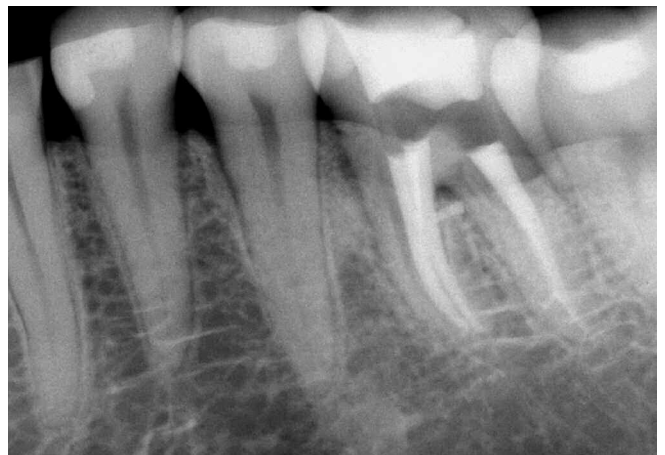

Figure 19d. A post-treatment film demonstrates the pack. Note the furcal canal and that the distal system bifurcates apically.

- **Tube & Glue:** The Cancellier Extractor Kit (*SybronEndo; Orange, California*) contains four different sized microtubes with outside diameters of approximately 0.50, 0.60, 0.70 and 0.80 mm. An abrasively coated ultrasonic instrument is typically used to trephine around and ideally expose the coronal 3 mm of an obstruction. A microtube is prefrit to ensure its internal diameter can just fit over the coronally exposed obstruction. The prefrit microtube may now be bonded onto the obstruction with an adhesive, such as core paste.⁵⁴ The Cancellier microtubes are safely scaled for progressively deeper placement into canals of posterior roots. This removal method is quite effective for retrieving a non-fluted broken instrument or when there is difficulty retrieving a separated file that is already loose. Caution should be exercised to not use too much adhesive which could inadvertently block a canal.
- **Tap & Thread:** The Post Removal System (PRS) contains five microtubular taps. The smallest PRS tap has an outside diameter of about 1.50 mm and internally forms threads and mechanically engages the most coronal aspect of any obstruction whose diameter is 0.60 mm or greater.⁵ However, the outside diameter of the smallest microtubular tap generally limits its use to radicular obstructions that extend coronally into the pulp chamber or the coronal one-third of larger canals.
- **Masserann:** The Masserann kit represents a time-honored method to purchase and remove a broken instrument.⁴³ Although this device has been around for over forty years, is superbly made and can form a strong purchase, its smallest tubular extractors have outside diameters of about 1.20 and 1.50 mm which limit their safe use to generally larger canals in anterior teeth.
- **Spinal Tap Needle:** A spinal tap needle (*Ranfac; Avon, Massachusetts*) in conjunction with its metal insert plunger or a hedstroem file is another technique advocated to remove broken instruments.⁵ With limitations, this method of removal involves sizing the correct microtube so it can be placed over an ultrasonically exposed obstruction. Microtube sizes that are clinically relevant are 19, 21 and 23 gauge needles corresponding to outside

tube diameters of approximately 1.00, 0.80 and 0.60 mm, respectively. Because of their unique ability to engage, smaller sized hedstroem files may be selected and inserted into the coronal most aspect of the microtube.^{5,64} The hedstroem is passed down the length of the tube until it wedges tightly between the obstruction and the internal lumen of the microtube. However, because ISO files taper 0.32 mm over 16 mm of cutting blades, the taper of the file oftentimes restricts its placement through a smaller sized parallel microtube. In this instance, the spinal tap needle's metal insert plunger must be used to potentially form a purchase on the obstruction. This method is quite effective when removing obstructions from larger canals.

- **Endo Extractor / Meisinger Meitrac:** The Endo Extractor System and the recently released Meisinger Meitrac Instrument System (*Hager & Meisinger GmbH; Neuss, Germany*) are able to gain a strong mechanical purchase on a broken instrument. The Meitrac Instrument System has been reported in a trade journal to be able to remove broken files from otherwise inaccessible locations. However, the smallest Meitrac I trephine and extractor have outside diameters of approximately 1.50 mm. This diameter limits the practical use of this instrument to the coronal aspects of larger canals.
- **Instrument Removal System:** The Instrument Removal System (iRS) provides another mechanical method for the removal of intracanal obstructions such as silver points, carrier-based obturators or broken file segments (*Figure 20a*).⁵ The iRS is indicated when ultrasonic efforts prove to be unsuccessful and may be used to remove broken instruments that are lodged in the straightaway portions of the root or partially around the canal curvature.^{5,44} The black instrument has an outside diameter of 1.00 mm and is designed to work in the coronal one-third of larger canals, whereas the red and yellow instruments have outside diameters of 0.80 and 0.60 mm, respectively, and can be placed deeper into more narrow canals. Each complete instrument is comprised of a color coordinated microtube and screw wedge (*Figure 20b*). Each microtube has a small-sized plastic handle to enhance vision during placement, a side window to



Figure 20a. The Instrument Removal System (iRS) is a set of devices utilized for removing broken instruments.

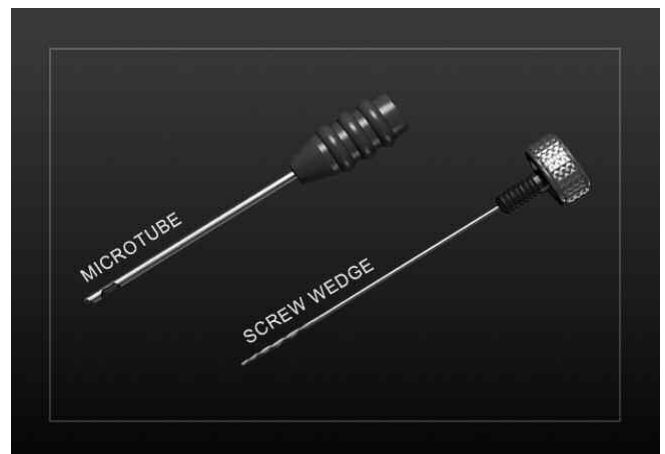


Figure 20b. Each iRS instrument is comprised of a microtube and an internal screw wedge designed to mechanically engage and remove intracanal obstructions.

improve mechanics, and a 45° beveled end to “scoop up” the coronal end of a broken instrument. Each screw wedge has a knurled metal handle, a left handed screw mechanism proximally, and a solid cylinder that transitions into 0.02 tapered K-type file blades towards its distal end to facilitate engaging an obstruction.

As has been emphasized for any removal technique, straightline coronal and radicular access is required to expose and subsequently visualize the coronal-most end of the broken instrument. As previously described, the clinician utilizes ultrasonic instrumentation to circumferentially expose 2-3 mm of the separated file. However, ultrasonic instruments can only circumferentially trephine, sand away dentin, and expose the portion of the obstruction that lies in the straightaway portion of the canal. Therefore, the goal is to expose 2-3 mm, or about one-third of the total length, of a separated instrument (*Figure 21a*).

An iRS microtube is then selected that can passively slide through the pre-enlarged canal and drop over the exposed broken instrument. As previously mentioned, in a curved

canal, the head of a broken NiTi file will always lie against the outer wall. In these instances, the microtube is inserted into the canal with the long part of its beveled end oriented to the outer wall of the canal to “scoop up” the head of the broken instrument and guide it into the microtube (*Figure 21b*). Once the microtube has been positioned, the same color coded screw wedge is inserted and slid internally through the microtube’s length until it contacts the obstruction. The obstruction is engaged by gently turning the screw wedge handle CCW. A few degrees of rotation will serve to tighten, wedge, and oftentimes, displace the head of the obstruction through the microtube window (*Figure 21c*). If any given color coded screw wedge is unable to achieve a strong hold on the obstruction, then another color coded screw wedge may be chosen to improve engagement and successful removal. When engaged, the obstruction can be potentially unwound and removed by rotating the microtube and screw wedge assembly CCW (*Figure 21d*). The direction of rotation, in the instance of a broken file, is generally CCW, but ultimately should be appropriate to the thread design of the obstruction. If difficulty is encountered when rotating the

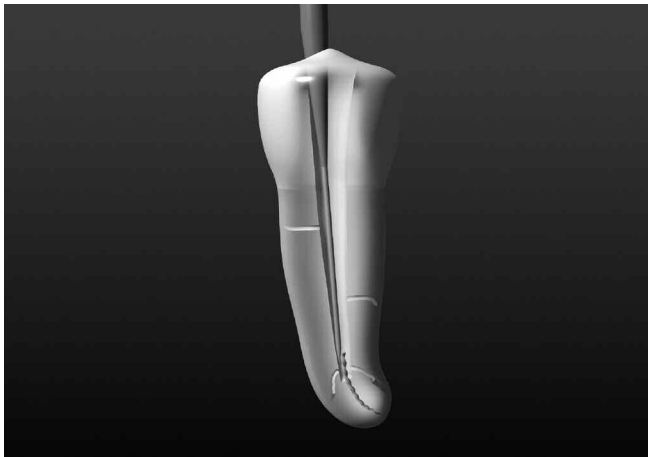

Figure 21a. This graphic demonstrates a titanium ProUltra ENDO-8 trephining deep around the coronal aspect of the broken file.

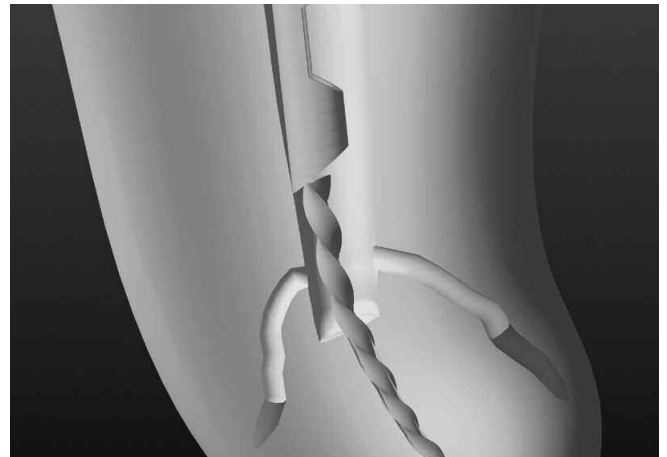


Figure 21b. When ultrasonic procedures prove ineffective, the beveled end of an iRS microtube is designed to “scoop up” the head of the broken file.

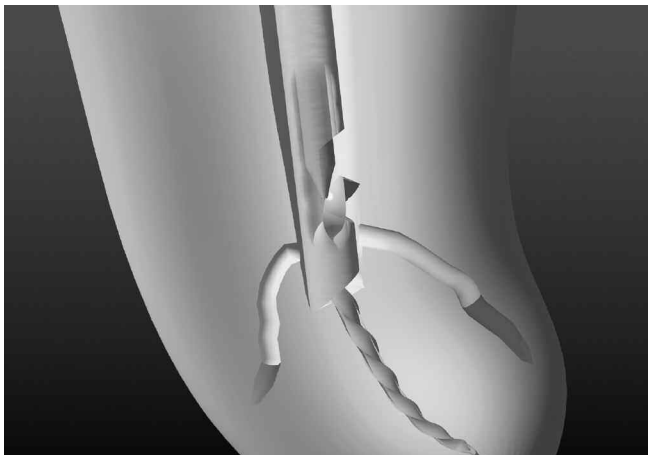


Figure 21c. This graphic shows the introduction of the screw wedge which is rotated CCW to engage and potentially displace the head of the file out the side window.

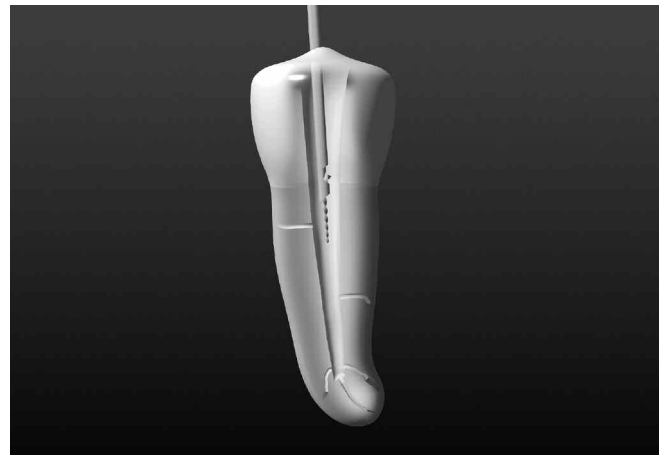

Figure 21d. This graphic demonstrates the iRS can form a strong purchase on, unwind and remove a broken instrument.

microtube and screw wedge assembly CCW, then proceed with a limited CW rotation of 3-5°, which will promote staying engaged, followed by turning the assembly CCW until snug. This repeated reciprocating handle motion will serve to loosen and facilitate the removal process. Placing an activated ultrasonic instrument on the engaged assembly is another potent adjunct that will oftentimes promote removal success. If a microtube cannot be placed over a broken instrument such that the head of the obstruction lies within the side window, then in these instances, the microtube's beveled end can be easily reduced or eliminated to achieve better mechanics. A clinical case utilizing the iRS option is shown in *Figure 22*.

The best antidote for a broken file is prevention. Adhering to proven concepts and utilizing safe techniques during root canal preparation procedures will virtually eliminate the broken instrument procedural accident.^{26,29} Prevention may also be greatly facilitated by thinking of negotiating and shaping instruments as disposable items. Simply discarding all instruments after the completion of each endodontic case will reduce breakage, lost clinical time and upsets. However, on occasion, an instrument will break and the treating dentist

must decide on the best treatment option.⁶⁵ Weighing risk versus benefit, certain broken file segments may not be able to be retrieved. In these instances, and in the presence of clinical symptoms and/or radiographic pathology, surgery or extraction may be the best treatment option.

FUTURE

The future of endodontics is bright and the demand for initial treatment and retreatment will grow significantly in the years immediately ahead. As we have seen in this article, a variety of techniques exist to address endodontically failing teeth. However, not all failures are amenable to successful nonsurgical retreatment. Clinicians need to weigh risk versus benefit and recognize that, at times, a referral, surgery or extraction might be in the patient's best interest. Interdisciplinary excellence is the foundation for professional fulfillment, patient satisfaction and longterm success. As the health of the attachment apparatus around endodontically treated teeth becomes fully appreciated, the naturally retained root will be recognized as the ultimate dental implant. Properly performed, endodontic treatment is the cornerstone of restorative and reconstructive dentistry. ▲

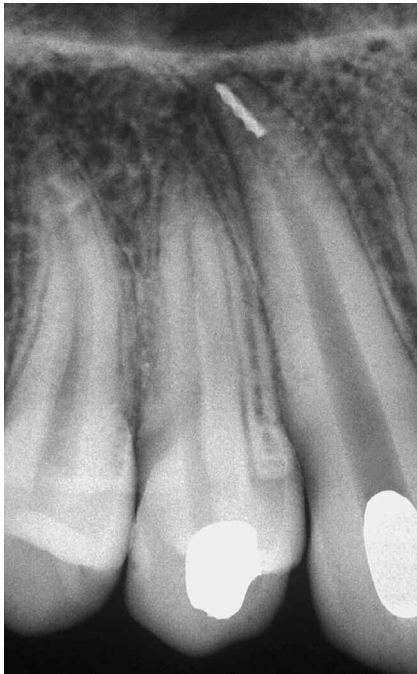

Figure 22a. A pre-operative radiograph of a maxillary canine demonstrates a temporized canal with an instrument broken deep in the apical one-third.

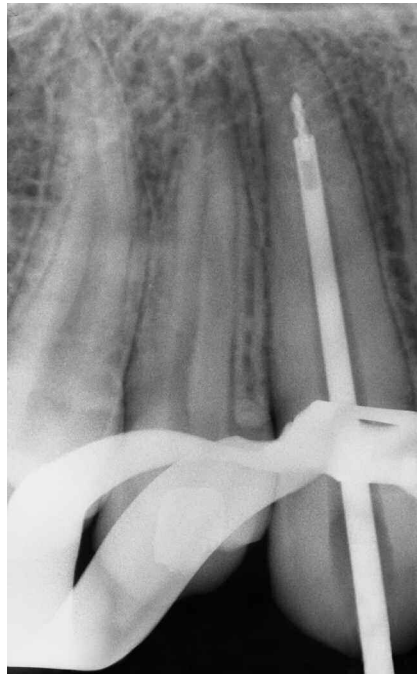


Figure 22b. A working film shows that the iRS has successfully engaged and partially elevated the deeply positioned file segment.

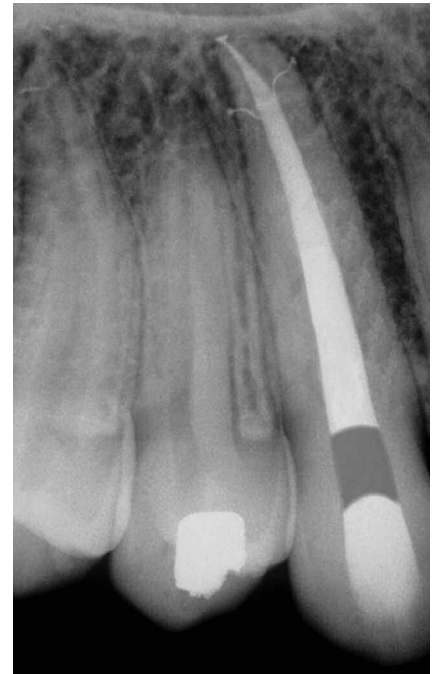

Figure 22c. A post-operative film demonstrates the retreatment steps and a densely packed system that exhibits three apical portals of exit.

REFERENCES

1. Ruddle CJ. Nonsurgical endodontic retreatment. *J Calif Dent Assoc* 2004;32(6):474-84.
2. Friedman S, Stabholz A. Endodontic retreatment: case selection and technique. Part 1: criteria for case selection. *J Endodon* 1986;12:28-33.
3. Stabholz A, Friedman S. Endodontic retreatment: case selection and technique. Part 2: treatment planning for retreatment. *J Endodon* 1988;14(12):607-14.
4. Friedman S, Stabholz A, Tamse A. Endodontic retreatment: case selection and technique. Part 3: retreatment techniques. *J Endodon* 1990;16:543-9.
5. Ruddle CJ. Ch. 25: nonsurgical endodontic retreatment. In: *Pathways of the Pulp*, 8th ed. Cohen S, Burns RC, eds. St. Louis: Mosby, 2002:875-929.
6. Hoen MM, Pink FE. Contemporary endodontic retreatments: an analysis based on clinical treatment findings. *J Endodon* 2002;28(12):834-6.
7. Machtou P. Ch. 8: la cavité d'accès. In: *Endodontie - guide clinique*. Machtou P, ed. Paris: Editions CdP, 1993:125-137.
8. Wolcott J, Ishley D, Kennedy W, Johnson S, Minnich S. Clinical investigation of second mesiobuccal canals in endodontically treated and retreated maxillary molars. *J Endodon* 2002;28(6):477-9.
9. Ruddle CJ. Microendodontic nonsurgical retreatment. In: *Microscopes in Endodontics*, *Dent Clin North Am*. Philadelphia: W.B. Saunders, 1997:41(3):429-54.
10. Schilder H. Cleaning and shaping the root canal system. *Dent Clin North Am* 1974;18(2):269-96.
11. Schilder H. Filling root canals in three dimensions. *Dent Clin North Am* 1967;7:723-744.
12. Stamos DE, Gutmann JL. Survey of endodontic retreatment methods used to remove intraradicular posts. *J Endodon* 1993;19(7):366-9.
13. Machtou P, Sarfati P, Cohen AG. Post removal prior to retreatment. *J Endodon* 1989;15(11):552-4.
14. Masserann J. The extraction of posts broken deeply in the roots. *Acta Odont Stomatol* 1966;75:329-42.
15. Goon WWY. Managing the obstructed root canal space: rationale and techniques. *J Calif Dent Assoc* 1991;19(5):51-7.
16. Hess W. *Anatomy of the Root Canals of the Teeth of the Permanent Dentition*. New York: William Wood & Co, 1925.
17. Smith BJ. Removal of fractured posts using ultrasonic vibration: an in vivo study. *J Endodon* 2001;27:632-4.
18. Yoshida T, Gomyo S, Itoh T, Shibata T, Sekine I. An experimental study of the removal of cemented dowel-retained cast cores by ultrasonic vibration. *J Endodon* 1997;23(4):239-41.
19. Bergeron BE, Murchison DF, Schindler WG, Walker WA 3rd. Effect of ultrasonic vibration and various sealer and cement combinations on titanium post removal. *J Endodon* 2001;27(1):13-7.
20. Gluskin AH, Ahmad I, Herrero DB. The aesthetic post and core: unifying radicular form and structure. *Practical Procedures & Aesthetic Dentistry* 2002;14(4):313-22.
21. Gomes APM, Kubo CH, Santos RAB, Santos DR, Padilha RQ. The influence of ultrasound on the retention of cast posts cemented with different agents. *Int Endod J* 2001;34:93-9.
22. Abbott PV. Incidence of root fractures and methods used for post removal. *Int Endod J* 2001;35:63-7.
23. Kleier DJ, Shibilski K, Averbach RE. Radiographic appearance of titanium posts in endodontically treated teeth. *J Endodon* 1999;25(2):128-31.
24. Ruddle CJ. Nonsurgical endodontic retreatment. *J Calif Dent Assoc* 1997;25(11):765-800.
25. Satterthwaite JD, Stokes AN, Frankel NT. Potential for temperature change during application of ultrasonic vibration to intra-radicular posts. *Eur J Prosthodont Restor Dent* 2003;11(2):51-6.
26. Romero AD, Green DB, Wucherpfennig AL. Heat transfer to the periodontal ligament during root obturation procedures using an in vitro model. *J Endodon* 2000;26(2):85-7.
27. Sweatman TL, Baumgartner JC, Sakaguchi RL. Radicular temperatures associated with thermoplasticized gutta percha. *J Endodon* 2001;27(8):512-5.
28. Johnson WT, Leary JM, Boyer DB. Effect of ultrasonic vibration on post removal in extracted human premolar teeth. *J Endodon* 1996;22:487-8.
29. Gesi A, Magnolfi S, Goracci C, Ferrari M. Comparison of two techniques for removing fiber posts. *J Endodon* 2003;29(9):580-2.
30. Gettleman BH, Spriggs KA, ElDeeb ME, Messer HH. Removal of canal obstructions with the endo extractor. *J Endodon* 1991;17(12):608-11.
31. Dixon, EB, Kaczowski PJ, Nicholls JI, Harrington GW. Comparison of two ultrasonic instruments for post removal. *J Endodon* 2002;28(2):111-5.
32. Buoncristiani J, Seto BG, Caputo AA. Evaluation of ultrasonic and sonic instruments for intraradicular post removal. *J Endodon* 1994;20(10):486-9.
33. Altshul JH, Marshall G, Morgan LA, Baumgartner JC. Comparison of dentinal crack incidence and of post removal time resulting from post removal by ultrasonic or mechanical force. *J Endodon* 1997;23(11):683-6.
34. Frank AL. The dilemma of the fractured instrument. *J Endodon* 1983;9(12):515-6.
35. Fors UG, Berg JO. Endodontic treatment of root canals obstructed by foreign objects. *Int Endod J* 1986;19(2).
36. Chenail BL, Teplitsky PE. Orthograde ultrasonic retrieval of root canal obstructions. *J Endodon* 1987;13:186-90.
37. Berutti E, Chiandussi G, Gaviglio I, Ibba A. Comparative analysis of torsional and bending stresses in two mathematical models of nickel-titanium rotary instruments: protaper versus profile. *J Endodon* 2003;29(1):15-9.

38. Wong R, Cho F. Microscopic management of procedural errors. In: *Microscopes in Endodontics, Dent Clin North Am*. Philadelphia: W.B. Saunders, 1997;41(3):455-79.
39. Gorni FGM, Gagliani MM. The outcome of endodontic retreatment: a 2-year follow-up. *J Endodon* 2004;30(1):1-4.
40. Crump MC, Natkin E. Relationship of broken root canal instruments to endodontic case prognosis: a clinical investigation. *JADA* 1970;80:1341-7.
41. Nagai O, Tani N, Kayaba Y, Kodama S, Osada T. Ultrasonic removal of broken instruments in root canals. *Int Endod J* 1986;19:298-304.
42. Hulsmann M. Removal of fractured instruments using a combined automated/ultrasonic technique. *J Endodon* 1994;20(3):144-6.
43. Masserann J. The extraction of instruments broken in the radicular canal: a new technique. *Acta Odont Stomatol* 1959;47:265-74.
44. Ruddle CJ. Ruddle on retreatment, 4-part dvd series. James Lowe Productions / Studio 2050, producers. Santa Barbara: *Advanced Endodontics*, 2004.
45. Baumgartner C. Advanced endodontics: ruddle on retreatment. *J Endodon* 2002;28(5):413.
46. Mines P, Loushine RJ, West LA, Liewehr FR, Zadinsky JR. Use of the microscope in endodontics: a report based on a questionnaire. *J Endodon* 1999;25(11):755-8.
47. Ward JR, Parashos P, Messer HH. Evaluation of an ultrasonic technique to remove fractured rotary nickel-titanium endodontic instruments from root canals: an experimental study. *J Endodon* 2003;29(11):756-63.
48. Ward JR, Parashos P, Messer HH. Evaluation of an ultrasonic technique to remove fractured rotary nickel-titanium endodontic instruments from root canals: clinical cases. *J Endodon* 2003;29(11):764-7.
49. Ruddle CJ. Broken instrument removal. *Endodontic Practice* 2003;6(1):13-22.
50. Hulsmann M, Schinkel I. Influence of several factors on the success or failure of removal of fractured instruments from the root canal. *Endod Dent Traumatol* 1999;15:252-8.
51. Peters OA, Laib A, Rügsegger P, Barbakow F. Three dimensional analysis of root canal geometry using high resolution computed tomography. *J Dent Res* 2000;79:1405-9.
52. Rhodes JS, Pitt Ford TR, Lynch PJ, Liepins PJ, Curtis RV. Micro-computed tomography: a new tool for experimental endodontology. *Int Endod J* 1999;32:165-70.
53. Gorni FGM. The removal of broken instruments. *Endodontic Practice* 2001;4(3):21-6.
54. Carr GB. Ch. 24: retreatment. In: *Pathways of the Pulp*, 7th ed. Cohen S, Burns RC, eds. St. Louis: Mosby, 1998:791-834.
55. Ruddle CJ. Ch. 8: cleaning and shaping root canal systems. In: *Pathways of the Pulp*, 8th ed. Cohen S, Burns RC, eds. St. Louis: Mosby, 2002:231-91.
56. Ruddle CJ. Ruddle on clean•shape•pack, 2-part video set/dvd. Studio 2050, producer. Santa Barbara: *Advanced Endodontics*, 2002.
57. Nehme WB. Elimination of intracanal metallic obstructions by abrasion using an operational micro-scope and ultrasonics. *J Endodon* 2001;27(5):365-7.
58. Fors UGH, Berg JO. A method for the removal of broken endodontic instruments from root canals. *J Endodon* 1983;9(4):156-9.
59. Hulsmann M. Removal of silver cones and fractured instruments using the canal finder system. *J Endodon* 1990;16(12):596-600.
60. Ruddle CJ. Finishing the apical one-third. *Endodontic Practice* 2002;5(3):15-26.
61. Eleazer PD, O'Connor RP. Innovative uses for hypodermic needles in endodontics. *J Endodon* 1999;25(3):190-1.
62. D'Arcangelo C, Varvara G, De Fazio P. Broken instrument removal – two cases. *J Endodon* 2000;26(6):368-70.
63. Roig-Greene JL. The retrieval of foreign objects from root canals: a simple aid. *J Endodon* 1983;9(9):394-7.
64. Suter B. A new method for retrieving silver points and separated instruments from root canals. *J Endodon* 1998;24(6):446-8.
65. Kvist T, Reit C. Results of endodontic retreatment: a randomized clinical study comparing surgical and nonsurgical procedures. *J Endodon* 1999;25(12):814-7.
66. Schwartz RS, Robbins JW. Post placement and restoration of endodontically treated teeth: a literature review. *J Endodon* 2004;30:289-301.