

SHAPING FOR SUCCESS EVERYTHING OLD IS NEW AGAIN

by Clifford J. Ruddle, DDS

There are enormous differences in opinion regarding the best methods for shaping root canals and cleaning the root canal system. A review of the literature reveals virtually no agreement on a variety of fundamental clinical issues. There is ongoing controversy regarding the sequence of canal preparation, working length, and the use of patency files. Ignorance abounds related to the question of how large to prepare the apical foramen and what is the appropriate percentage taper of a canal that ensures a root canal system can be both three-dimensionally cleaned and filled. There is heightened confusion trying to identify, assimilate, and integrate the best technologies and instruments. There is no international agreement regarding the most effective strength, temperature, and volume of an irrigant, nor the potential for any given reagent to clean. Major disagreements exist pertaining to the importance of deep lateral debridement, smear layer management, and biofilms, and how these factors influence success. In the final analysis, science and basic research can illuminate our clinical

endeavors, but ultimately, it is by our clinical actions that our success as a healing profession is measured. Fortuitously, Dr. Herbert Schilder described the most predictably successful concepts and strategies for shaping canals and cleaning root canal systems. Schilderian endodontics continues to serve as a powerful beacon of light to guide any clinician on the journey toward greater clinical confidence and success.

More than thirty years ago, Schilder's article, entitled "Cleaning and Shaping the Root Canal," was published.¹ In what has become a classic article, he presents brilliant concepts and defines the five mechanical objectives for shaping canals and cleaning root canal systems. Schilder completely understood that, logically, the dimensions of these smooth flowing funneled preparations would necessarily and appropriately vary relative to the anatomy of any given root (*Figure 1*). Schilder fully appreciated that well-shaped canals would exhibit "the look", improve the potential for three-dimensionally cleaning and filling root canal

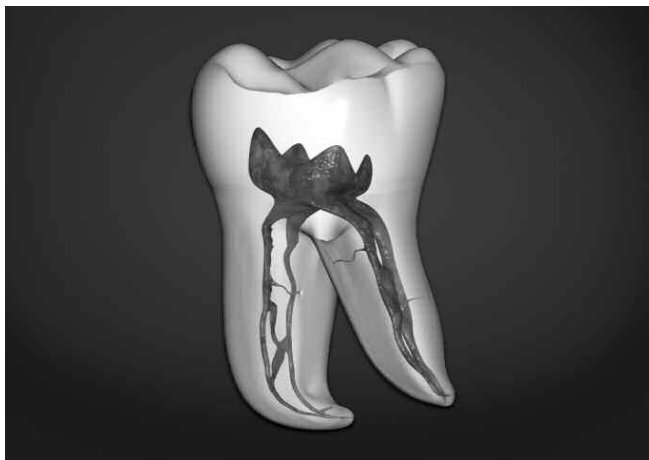

Figure 1a. This image serves to emphasize root curvatures, external root concavities, and root canal system anatomy.

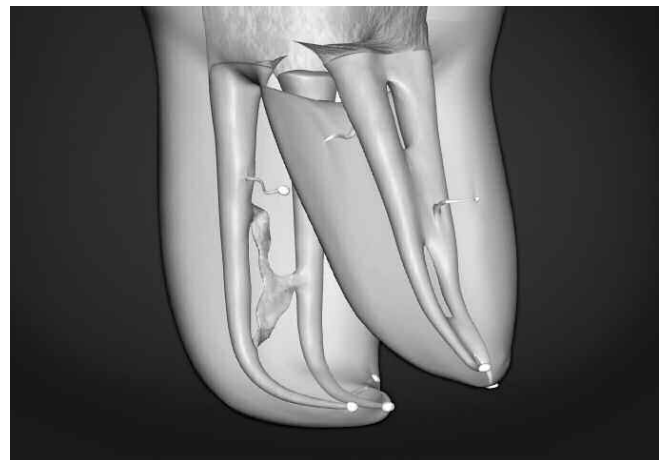

Figure 1b. At a higher magnification, this image demonstrates that shaping facilitates three-dimensional cleaning, and shaping facilitates filling root canal systems.

systems, and fulfill the biological objectives for the retention of critically essential teeth (*Figure 2*).

Schilder's genius was the innovative motion he used with a series of instruments to carve the shape and sequence the preparation. There are strategic advantages to removing restrictive dentin from the coronal two-thirds of the canal before initiating procedures in the deeper and typically more complicated apical region of the canal (*Figure 3*).² Schilder's shaping objectives are the standard against which all other preparation techniques are measured. This strategy of pre-enlargement is very different from the frequently used step-back and crown-down techniques. Each technique has been described in different ways, has something to offer, and was developed to advance canal preparation methods. Although each technique can theoretically produce the same final shape, each method is very different and has been designed to prepare a general region within the canal in a precise sequence. The following will briefly review the *step-back*, *crown-down*, and *pre-enlargement techniques*.

SHAPING TECHNIQUES

In the *step-back technique*, small-sized ISO hand files are initially used to negotiate the full length of canal. Larger files are then carried into the apical one-third until the desired master file reaches the chosen working length. The apical one-third of the preparation is deemed complete when the master file is snug at length and each consecutive larger file in the series is observed to uniformly step-back from the most apical extent of the preparation. When the apical one-third of the preparation has been completed, then the coronal two-thirds of the canal is flared and the overall length of the preparation smoothly blended. Although this preparation method can be successful and is performed with slight variations, the technique has regrettably resulted in countless canals that have been blocked, ledged, transported, or perforated. These iatrogenic events frequently require additional procedures, such as nonsurgical retreatments, surgeries, and extractions.³

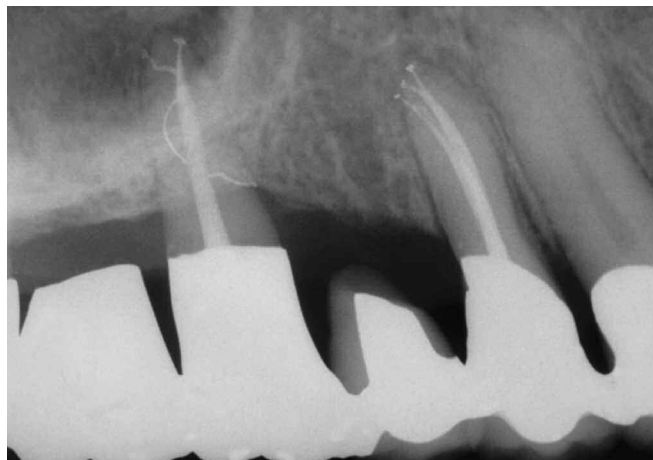

Figure 2. Sequencing the preparation facilitates shaping canals and cleaning root canal systems. Complete endodontic treatment is the foundation of perio-prosthetics.

In the *crown-down technique*, ISO instruments with varying D₀ diameters are generally selected and utilized from the bigger to smaller sizes. In general, the preparation is initiated at the orifice, continued through the body of the canal, and then terminated at the canal's most apical extent. As such, dentin is sequentially removed from the coronal, then the middle, and finally from the apical one-third of a canal. Although the crown-down technique overcame many of the frustrations associated with the step-back technique, the paradox is threefold. First, although the instruments initially selected aggressively plow away dentin with their bigger, stronger, and stiffer tips, it must be recognized that a large spinning file will over-simplistically cut a round hole. Preparing a round hole through an anatomical cross-section which commonly exhibits an irregular configuration compromises debridement and disinfection. Second, the taper of the ever-expanding preparation quickly duplicates the taper of the file used, especially in longer, smaller-diameter, and more curved canals. When a file has a long engagement over its active length, then dangerous taper lock results and the potential for breakage significantly increases.⁴ Third, the potential for file breakage increases as the smaller-sized files, utilized in the apical one-third, tend to engage and cut dentin toward their smaller, weaker, and less efficient blades.

In the *pre-enlargement technique*, a series of ISO instruments with varying D₀ diameters are selected, appropriately precurved, and utilized from the smaller to bigger sizes. Especially in longer, smaller-diameter, and more curved canals, the shaping instruments are initially restricted to the coronal two-thirds of the canal. Each consecutive larger instrument will generally work short of the previously used smaller files, progressively carve away restrictive dentin, and serve to funnel the coronal and middle two-thirds of the canal. However, since these instruments are used from small to big, their more flexible tips are typically loose and safely follow the secured portion of the canal. Importantly, depending on the extent of curvature, any given ISO instrument will cut a shape larger than its taper would suggest.

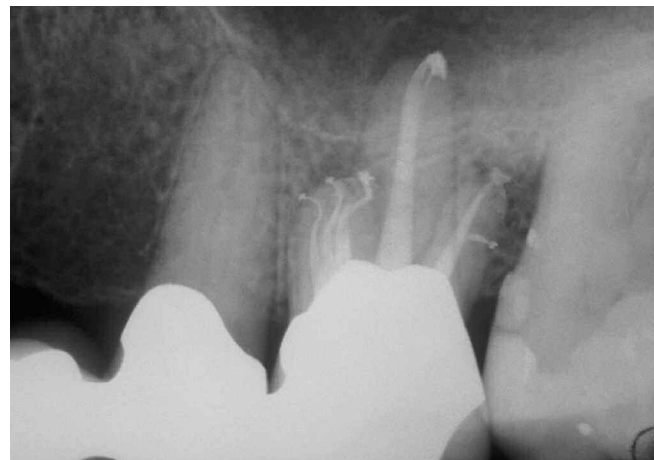

Figure 3. An endodontically treated maxillary first molar demonstrates five treated canals and that each system exhibits various anatomical configurations.

Specifically, when the Envelope of Motion (EOM) technique is employed, each instrument will randomly cut dentin on the outstroke toward its larger, stronger and more active blades.¹ Properly performed, pre-enlargement procedures improve access to the typically more challenging anatomy in the apical one-third of the canal. Fortuitously, following pre-enlargement procedures, finishing files are completely loose within the body of the canal and can be more predictably directed apically. In this technique, emphasis is placed on shaping and blending the apical one-third of the preparation into the body of the canal. Finishing the canal is the *sine quo non* of preparation excellence (*Figure 4*).

Over many years, the pre-enlargement technique has grown in popularity as this method for shaping canals has proven to be predictably successful. However, this method for preparing canals frequently requires many instruments, several recapitulations through a series of files and reamers, and as such, is perceived to be difficult and time-consuming. Hence, the ProTaper variably tapered design was developed to provide a 6 instrument set, comprised of 3 Shaping and 3 Finishing files, that would both duplicate and simplify the Schilder technique. Each Shaping file would have increasing percentage tapers over the length of its cutting blades. Each Finishing file would have a fixed taper in its apical extent, then importantly, decreasing percentage tapers over the coronal two-thirds length of its blades. When sequenced and used correctly, the ProTaper files afford extraordinary flexibility, efficiency, safety, and simplicity (*Figure 5*).⁵⁻⁷

The ProTaper method of use precisely duplicates the Schilder technique where precurved reamers were sequentially selected, rotated in an “envelope of motion,” and cut dentin on the withdrawal stroke.^{8,9} The ProTaper Shaping files’ small-sized tips act as guides to passively follow the path of the canal previously secured with hand files.¹⁰ Increasingly larger percentage tapers over the active length of each Shaping file ensures each sequential instrument works away from its apical extent. Importantly, an increasing percentage tapered file selectively cuts dentin toward its larger, stronger, and more efficient blades.¹¹ The unique

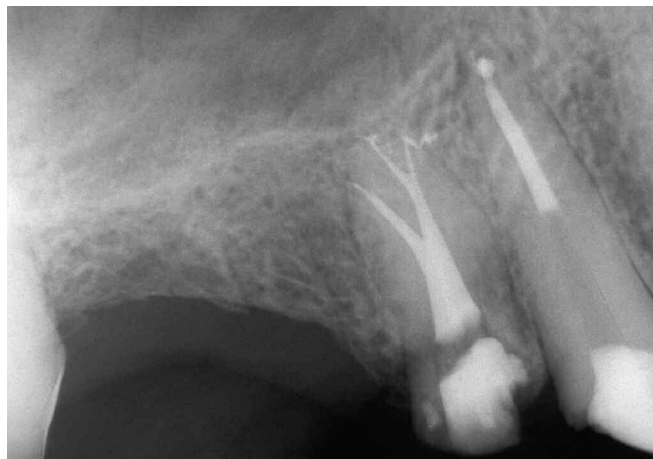

Figure 4. An endodontically treated maxillary first bicuspid exhibits branching systems that terminate into three apical portals of exit.

geometries of each ProTaper NiTi file unite the most enduring shaping method from the past with the newest technological advancements in machining today. As such, ProTaper files fulfill the age-old adage, “Everything old is new again.”

THE PROTAPER SHAPING TECHNIQUE

Endodontic outcomes are improved when instruments pass through the access opening, effortlessly slide down smooth axial walls and are easily inserted into the orifice (*Figure 6*). The potential to consistently shape canals and clean root canal systems is significantly enhanced when the coronal two-thirds of the canal is first pre-enlarged followed by preparing its apical one-third.²

SCOUT THE CORONAL TWO-THIRDS

When straightline access is completed, the pulp chamber may be filled brimful with a viscous chelator. Based on the pre-operative radiographs, ISO 0.02 tapered sizes 10 and 15 hand files are measured and precurved to match the anticipated full length and curvature of the root canal. However, in this method of canal preparation, these instruments are initially limited to the coronal two-thirds of a root canal. The 10 and 15 hand files are utilized within any portion of the canal until they are loose and a smooth reproducible glide path is confirmed. The loose depth of the 15 file is measured and this length transferred to the ProTaper S1 and S2 files.

SHAPE THE CORONAL TWO-THIRDS

The secured portion of the canal can be optimally pre-enlarged by first utilizing S1 then S2. Prior to initiating shaping procedures, the pulp chamber is filled with a full strength solution of NaOCl. Without pressure, and in one or more passes, the ProTaper Shaping files are allowed to passively “float” into the canal and “follow” the glide path. To optimize safety and efficiency, the Shaping files are used, like a “brush”, to laterally and selectively cut dentin on the outstroke. A brush-cutting action creates lateral space which

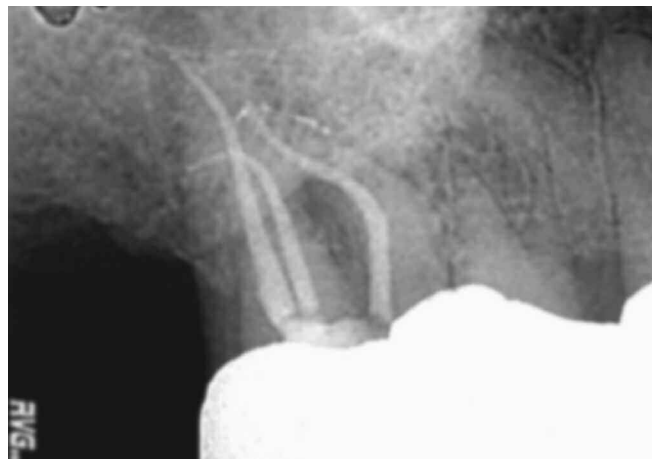

Figure 5. The canals of this maxillary molar were prepared with ProTaper files. Note that the ProTaper files perfectly follow significant curvatures and carve smooth flowing shapes. (Courtesy of Dr. John West, Tacoma, Washington)

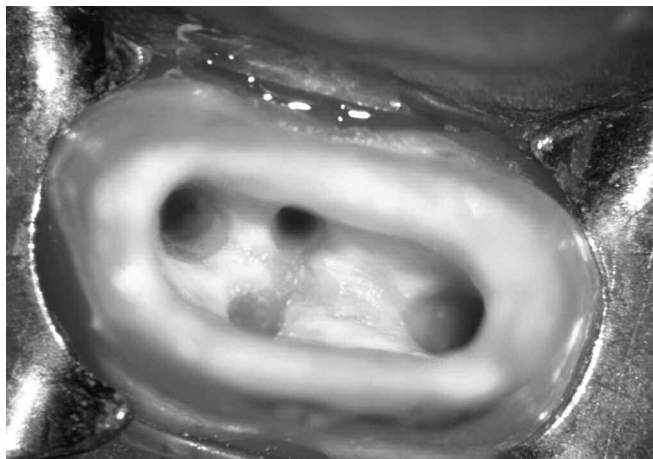

Figure 6. A photograph demonstrates an access cavity through a prosthetically prepared crown. Note the outline pattern, smooth axial walls, and four orifices

will facilitate the shaping file's larger, stronger and more active cutting blades to safely and progressively move deeper into the canal. Strategically, this brush-cutting action can be used to more effectively shape into fins, isthmuses, and canal irregularities or to relocate the coronal aspect of a canal away from furcal danger. If any ProTaper file ceases to easily advance within the secured portion of a canal, withdraw it, and recognize that intrablade debris has deactivated and pushed the instrument off the wall of the canal. Upon removing each Shaping file, visualize where the debris is located along its cutting blades to better appreciate the region within the canal that is being prepared. Following the use of each Shaping file, irrigate, recapitulate with a 10 file to break up debris and move it into solution, then re-irrigate. Without pressure, and in one or more passes, S1, then S2, is used in this manner until the depth of the 15 hand file is reached.

SCOUT THE APICAL ONE-THIRD

When the coronal two-thirds of the canal is shaped, then attention can focus on apical one-third procedures. With the pulp chamber filled brimful with a viscous chelator, the apical one-third of the canal is fully negotiated and enlarged to at least a size 15 hand file, working length confirmed and patency established.¹² At this time, a decision must be made between whether to finish the apical one-third with rotary or hand instruments. If a new and straight 15 file can gently "slide" and passively "glide" to length, then rotary instruments will generally follow this confirmed and "reproducible glide path".² However, certain canals exhibit anatomical challenges that necessitate a reciprocating handle motion in order to move precurved 10 and 15 files to length. When there is an "irregular glide path" then the apical one-third of a canal may be advantageously finished with precurved manual ProTaper instruments.

SHAPE THE APICAL ONE-THIRD

When the apical one-third of the canal has been secured, then the pulp chamber is filled brimful with NaOCl. The ProTaper sequence is to carry the S1, then the S2, to the full working length. Float, follow and brush as previously described until the terminus of the canal is reached. S1,

then S2, will typically move to length in one or more passes depending on the length, diameter and curvature of the canal. Following each ProTaper file, irrigate, recapitulate with a 10 file, then re-irrigate. After using the Shaping files, particularly in more curved canals, working length should be reconfirmed, as a more direct path to the terminus has been established. At this stage of treatment, the preparation can be finished using one or more of the ProTaper Finishing files in a "non-brushing" manner. The F1 is selected and passively allowed to move deeper into the canal, in one or more passes, until the terminus is reached. When the F1 achieves length, the instrument is removed, its apical flutes are inspected and if they are loaded with dentin, then visual evidence supports the shape is cut. Following the use of F1, flood the canal with irrigant, recapitulate and confirm patency, then re-irrigate to liberate debris from the canal.

PROTAPER FINISHING CRITERIA

Following the use of the 20/07 F1, the "ProTaper Finishing Criteria" is to gauge the size of the foramen with a 20/02 tapered hand file to determine if this instrument is snug or loose at length. If the 20 hand file is snug at length then the canal is fully shaped and, if irrigation protocols have been followed, ready to pack. Following the use of F1, if the 20 hand file is loose at length, then gauge the size of the foramen with a 25/02 tapered hand file. If the 25 file is snug at length, then the canal is fully shaped and ready to pack. If the 25 file is short of length, proceed to the 25/08 F2 and, when necessary, the 30/09 F3, gauging after each Finisher with the appropriately sized hand files. If the 30 file is loose at length, then use an alternative NiTi rotary line or manual files to finish the apical extent of these larger, easier and more straightforward canals. ProTaper shapes are easy to fill utilizing a ProTaper matching gutta percha master cone in conjunction with a warm vertical condensation technique (*Figure 7*). As an alternative, a well-shaped canal can be filled with a ProTaper carrier-based obturator. The ProTaper sequence is always the same regardless of the tooth or anatomical configuration of the canal being treated. In many cases, it's as easy as one, two, three, or in endodontic language, purple, white, yellow (*Figure 8*).

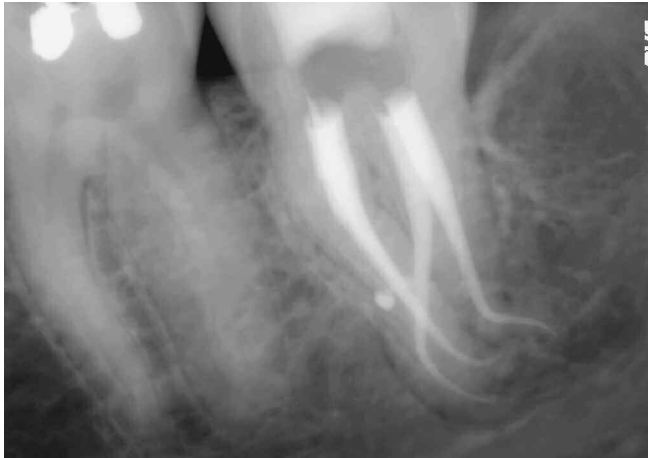

Figure 7a. The canals of this mandibular molar were shaped with ProTaper files and three-dimensionally filled. Note the flowing shapes, apical one-third curvatures and multiple portals of exit. (Courtesy of Dr. Jason West, Tacoma, Washington)

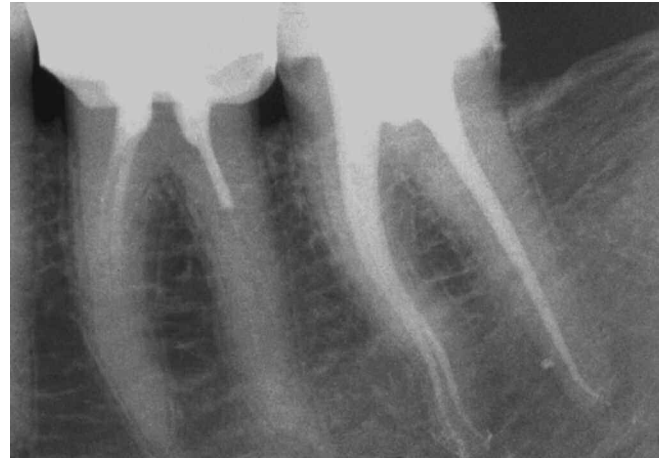

Figure 7b. The canals of this endodontically treated mandibular second molar were shaped with ProTaper files and demonstrate smooth flowing, multi-planar curvatures. (Courtesy of Dr. Dominique Martin; Paris, France)

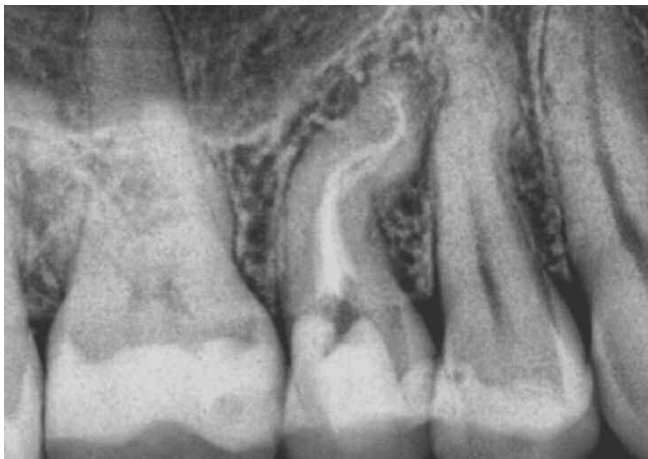

Figure 7c. This maxillary bicuspid was endodontically prepared with ProTaper files. The shapes perfectly follow the original canal pathways. (Courtesy of Dr. Michael Ribera; Washington, DC)

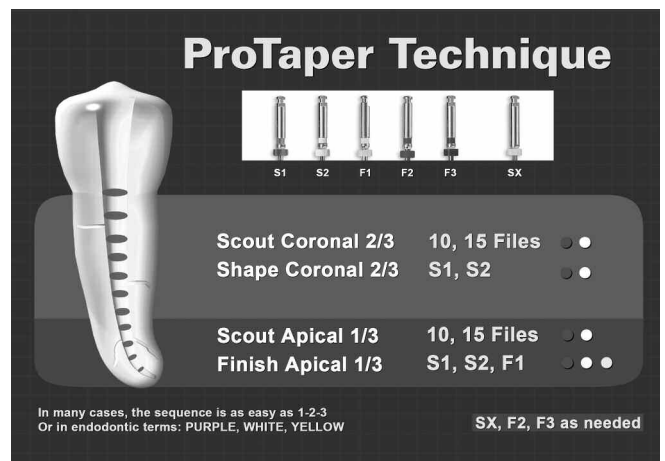


Figure 8. This chart summarizes the ProTaper shaping technique. The ProTaper sequence is always the same regardless of the length, diameter or curvature of the canal.

EVIDENCE FOR CLINICAL SUCCESS

A clinical investigation of the ProTaper technique, emphasizing method of use, was conducted on mesial canals of extracted mandibular molar teeth using μ CT-Analysis.¹³ In this particular study, horizontal sections from different radicular levels were analyzed using μ CT slices and volume renderings. The green color represented the anatomical contours before instrumentation whereas the red color indicated the shape after instrumentation. The results from this investigation are clinically relevant and a portion of the data is available for review in (Figure 9). The advantages of the Shaping files to brush laterally and selectively cut dentin on the outstroke are summarized as follows:

- 1) The Shaping files were essentially loose within a canal during the majority of their work.
- 2) The coronal aspect of the canals were safely relocated away from an external root concavity.
- 3) A brush-cutting action achieved a centered preparation and maximized remaining dentin.
- 4) The Shaping files physically contacted over 90% of the internal walls of the canals.

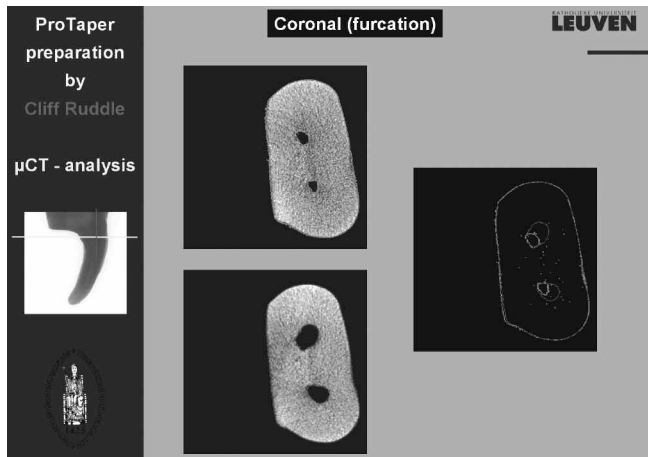


Figure 9a. This figure shows horizontal μ CT sections through the “coronal” one-third of the root. Note the successful relocation of the canals at this level.

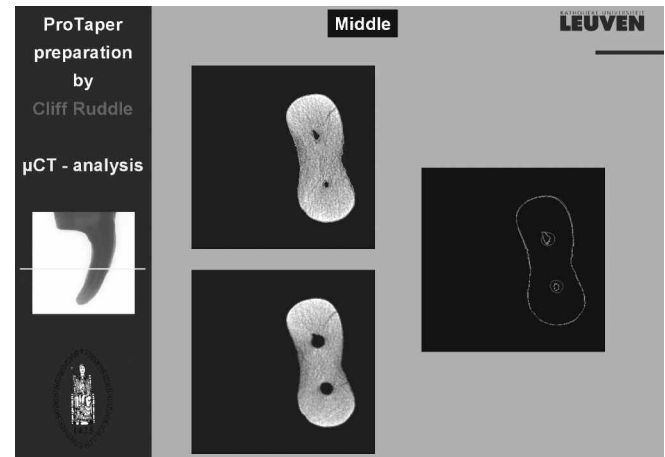


Figure 9b. This figure reveals horizontal μ CT sections through the “middle” one-third of the root. Note the ProTaper shapes are round and centered within the root.

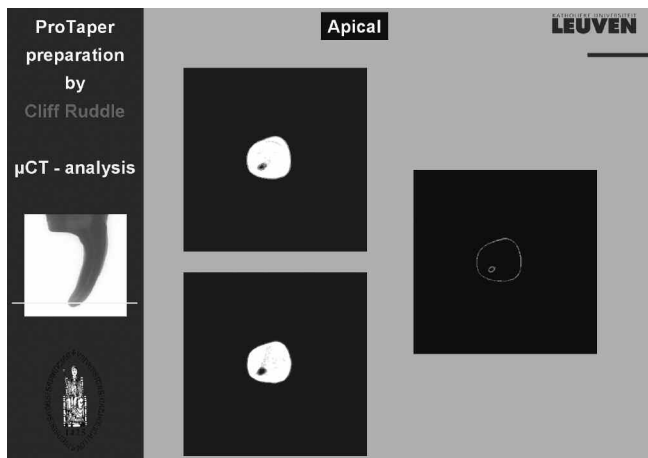


Figure 9c. This figure shows horizontal μ CT sections through the “apical” one-third of the root. Note the ProTaper shape perfectly includes the original canal diameter.

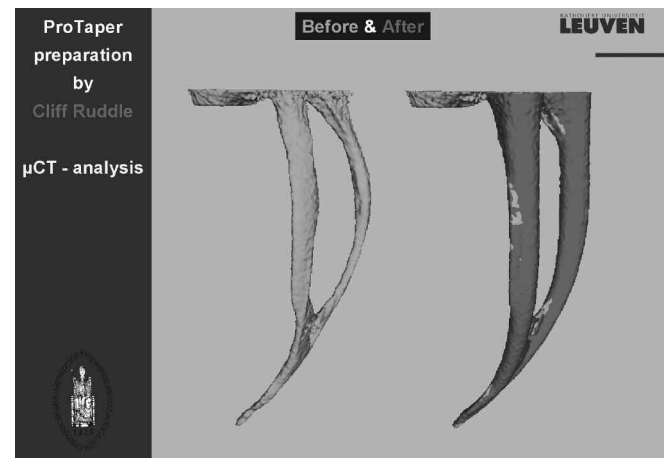


Figure 9d. This figure compares before and after instrumentation with the S1, S2, and F1 files. Note the shapes are full, smooth flowing and centered, and the files have physically contacted virtually all the internal anatomy.

(Figures 9a-9d courtesy of Dr. Lars Bergmans and BIOMAT Research Cluster, Catholic University of Leuven, Belgium)

PROTAPER UNIVERSAL

Even though the ProTaper line has experienced 5 years of explosive growth in the international market, several changes have recently been made to improve the existing market version. Although any particular change may seem unimportant, the changes in concert are synergistic and together represent a significant step forward. The most noticeable change will be the addition of two larger ProTaper Finishing files, namely F4 (40/06) and F5 (50/05). These two files may be used in anatomically larger canals or by those dentists who philosophically subscribe to making anatomically smaller-sized canals larger. Other improvements include removing the transition angle between the safe-end of the

file and the first cutting blade, balancing the work more evenly from file to file within the series, electropolishing, providing ProTaper in 31 mm lengths, and increasing the flexibility of the larger-sized Finishing files. Regarding flexibility, if one compares the D_0 diameter and taper of any given ProTaper file against any comparably-sized instrument of another brand-line, ProTaper will be judged to be significantly more flexible. Together, these improvements will enable ProTaper to address a greater variety of anatomical situations. Importantly, these instruments will decrease the perceived need for dentists to use hybrid file techniques.

ProTaper files will be relaunched this year and will be termed ProTaper Universal (*Figure 10*). It is an exciting time in dentistry as new technologies potentially drive new practice-building techniques and the expectation for greater clinical efficiency and success. In this time of unrelenting change, it would be wise to pause and remember the early pioneers of modern dentistry and reflect on the enormous contributions they made to create the biological and clinical foundations on which we stand. Dr. Herbert Schilder is one of these pioneers and his innovative concepts have remained enduring and relevant over the decades. For new technologies to be meaningful, clinical results must hold up to scientific scrutiny and compliment time-honored principles. The ProTaper concept for shaping canals has enabled both inexperienced and experienced dentists to consistently duplicate the most predictably successful concept ever described for preparing a canal. With this philosophy at its core, ProTaper continually moves forward. The message regarding ProTaper is "Whatever you thought, think again!" ProTaper Universal promises to raise the bar even higher. ▲

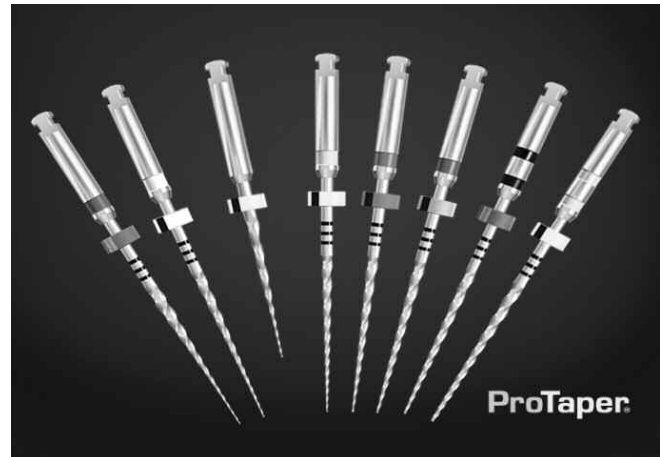

Figure 10. ProTaper files represent a revolutionary progression in efficiency and safety when preparing root canals. The ProTaper rotary files may be easily converted to manual files using color-coded, snap-on handles.

REFERENCES

- Schilder H: Cleaning and shaping the root canal, *Dent Clin North Am* 18:2, pp. 269-296, 1974.
- Ruddle CJ: Ch. 8, Cleaning and shaping root canal systems. In *Pathways of the Pulp*, 8th ed., Cohen S, Burns RC, eds. St. Louis: Mosby, pp. 231-291, 2002.
- Ruddle CJ: Ch. 25, Nonsurgical endodontic retreatment. In *Pathways of the Pulp*, 8th ed., Cohen S, Burns RC, eds., St. Louis: Mosby, pp. 875-929, 2002.
- Ruddle CJ: Nonsurgical retreatment, *J Endod* 30:12, pp. 827-845, 2004.
- Martin D, Amor J, Machtou P: Mechanized endodontics: the protaper system, principles and clinical protocol, *Revue d'Odonto Stomatologie* 31:1, pp. 33-42, 2002.
- Veltri M, Mollo A, Pini PP, Ghelli LF, Balleri P: In vitro comparison of shaping abilities of protaper and GT rotary files, *J Endod* 30:3, pp. 163-166, 2004.
- Blum JY, Machtou P, Ruddle CJ, Micallef JP: The analysis of mechanical preparations in extracted teeth using protaper rotary instruments: value of the safety quotient, *J Endod* 29:9, pp. 567-575, 2003.
- Ruddle CJ: The protaper endodontic system, *Endodontic Practice* 5:1, pp. 34-44, 2002.
- Machtou, P, Ruddle CJ: Advancements in the design of endodontic instruments for root canal preparation, *Alpha Omegan* 97:4, pp. 8-15, 2004.
- Berutti E, Negro AR, Lendini M, Pasqualini D: Influence of manual preflaring and torque on the failure rate of protaper rotary instruments, *J Endod* 30:4, pp. 228-230, 2004.
- Berutti E, Chiandussi G, Gaviglio I, Ibba A: Comparative analysis of torsional and bending stresses in two mathematical models of nickel-titanium rotary instruments: protaper versus profile, *J Endod* 29:1, pp. 15-19, 2003.
- Shabahang S, Goon WWY, Gluskin AH: An in vitro evaluation of Root ZX electronic apex locator, *J Endod* 22:11, pp. 616-618, 1996.
- Ruddle CJ: The protaper technique, *Endodontic Topics* 10:187-190, 2005.