



MICROENDODONTIC NONSURGICAL RETREATMENT: SILVER POINT REMOVAL

by Clifford J. Ruddle, D.D.S.

Endodontic obturation with silver points was introduced during the 1930's. For decades many dental schools taught the silver point technique and, as a result, thousands of clinicians obturated millions of root canals in this manner. To be successful utilizing this specific method of obturation canal preparation was specific, cone-fit technique was essential, and laterally condensed gutta percha was desirable. Properly performed, clinicians achieved good results, and this was observed and reported.

Initially, our profession was impressed at how radiopaque these obturated cases appeared radiographically. Often, a false sense of security prevailed when observing radiodense silver wires moving through millimeters of underprepared canals. Regretfully, the apparent density of the pack did not confirm the thoroughness of the cleaning and shaping, and optimistically, round wires were expected to seal irregularly shaped root canal systems. Sadly, a great number of cases obturated in this manner were underfilled, leaked, and failed.¹

Historically, and still too often, endodontic surgery is selected in efforts toward resolving failures. Even with the vast improvements achieved in surgical endodontics in recent years,^{2,3} surgical techniques are restricted in predictably eliminating pulp, bacteria, and related irritants from root canal systems. Importantly, disassembled root canals can usually be repaired,^{4,6} if necessary, and three-dimensionally cleaned, shaped, and packed providing a superior seal compared to surgical correction alone.^{9,10}

Today, clinicians frequently encounter silver point cases that are failing. Many possibilities exist for successful removal of silver points.^{5,7} The clinician is encouraged to be familiar with the concepts, strategies, and techniques associated with the various removal techniques. A comprehensive, but inconclusive, list would include the need for lighting and magnification, proper access, a variety of appropriate burs, ultrasonic instruments in direct and indirect contact, specially designed or modified pliers with tungsten carbide inserts, peripheral filing techniques in the presence of solvents, chelators or irrigants, hedstroem displacement techniques, fulcrum mechanics and

leverage schemes, microtube delivery using mechanical, adhesion, tap and thread, and lasso and anchor techniques. Fortunately, most endodontically failing silver point cases can be successfully retreated using just one, two, or perhaps three techniques.

The ease noted in removing most silver points is based on the fact that chronic leakage greatly reduces the seal and, hence, lateral retention. Before selecting a silver point retrieval technique, it is useful to recall the canal preparation ideally prescribed for this method of obturation. Typically, the apical 2 to 3 mm of the canal was prepared relatively parallel and then flared coronal to this zone. When evaluating a silver point failure, recognize the silver point is parallel over length, hope for a coronally shaped canal, and take advantage of this space discrepancy when approaching retreatment. The reason many techniques have been developed to remove silver points is essentially related to their diameter, length, retention, and position. Certain techniques evolved to address unshaped canals that hold silver points that bind against dentin over distance. Other techniques arose to remove silver points that are large in cross-sectional diameter approaching the size of posts. Finally, techniques were necessary to remove the split cone or intentionally sectioned silver points lying deep within the root canal space.

The following case explains the rationale for nonsurgical endodontic retreatment, illustrates certain silver point removal techniques, and emphasizes the clinical benefits of treating root canal systems.

CLINICAL CASE

A middle-aged patient was referred for endodontic retreatment of the maxillary left central incisor, tooth #9. The clinical exam revealed a three-unit bridge, normal attachment, and a parulis in the lingual rugae. A radiograph confirmed the anterior bridge abutment had silver point endodontics and demonstrates a gutta percha point tracing the fistulous tract to a large lateral root lesion (*Figure 1*).

Nonsurgical endodontic retreatment was recommended and commenced using an operating microscope (*Figure 2*). The endodontic access cavity is generally prepared through a restoration if it is judged to be functionally designed, well-fitting, and esthetically pleasing. If the existing dentistry meets the restorative criteria for excellence, the decision to remove any restoration is primarily based on the access required to facilitate endodontic disassembly.

In this particular case, the access cavity was prepared through the porcelain-fused-to-metal crown, being careful not to compromise retreatment by inadvertently foreshortening the most coronal aspect of the silver point entombed within the underlying build-up. The microscope provides unsurpassed vision and enhances safe excavation of restoratives circumferential to the silver point (*Figure 3*). To safely and progressively gain deeper access, clinicians are encouraged to select piezoelectric ultrasonic systems (*Satelec P5, Dentsply Tulsa Dental*) because of reliability, power, and versatility (*Figure 4*). Innovative ultrasonic instruments (*ProUltra ENDO Tips, Dentsply Tulsa Dental*) incorporate design elements which dramatically improve performance, clinical possibility, and access to anterior and posterior teeth (*Figure 5*).

There are five ProUltra ENDO ultrasonic instruments used in nonsurgical treatment, each designed to perform specific tasks. The ENDO-1 is contra-angled proximally, and its working end improves energy transfer during the clinical applications of removing crowns, bridges, posts, and restorative materials. The ENDO-2 is contra-angled and its redesigned shape provides enhanced energy for the successful removal of build-ups and pulp chamber cores. This instrument is also excellent for eliminating pulp stones, uncovering hidden orifices, chasing calcified canals, troughing around

obstructions within the pulp chamber, or contacting a specific grasping instrument when performing indirect ultrasonic procedures. The ENDO-3, 4, and 5 instruments have variable lengths and are designed with parallel sides to significantly enhance their use within root canals.

These instruments supply unsurpassed energy and their small profiles and contra-angle shape provide significant visual advantages in the coronal, middle, and apical one-third of all roots of all teeth. The suborifice instruments are used to trough around obstructions, chase deeply receded calcified canals, negotiate iatrogenic blocks, eliminate obstructions, such as broken instruments, silver points, and brick-hard resin pastes, and vibrate cements into preparations during repair or filling procedures. The three sizes allow the clinician greater control as instruments are selected, according to available canal diameter and their depth of use.

Caution should be exercised not to use ultrasonic instruments directly on silver points because elemental silver is soft and rapidly erodes during mechanical manipulation. Experience shows that ultrasonic instruments work best when used lightly circumferential to the silver point (*Figure 6*). The appropriately selected ultrasonic instrument trephines around the silver point, breaking up cements, until its coronal-most aspect is free (*Figure 7*). The clinician must confirm the looseness of the silver point coronally to formulate the best removal strategy. Specially designed pliers (*Stieglitz pliers, Henry Schein*) are selected to grasp and remove the partially exposed silver point. Ultrasonic energy transmitted directly on these pliers synergistically enhances retrieval efforts. However, on occasion, one or more of the previously identified silver point removal techniques may be necessary to encourage efficient and successful removal.

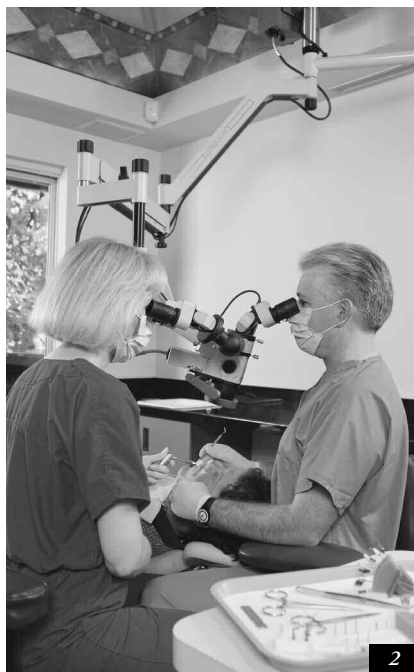
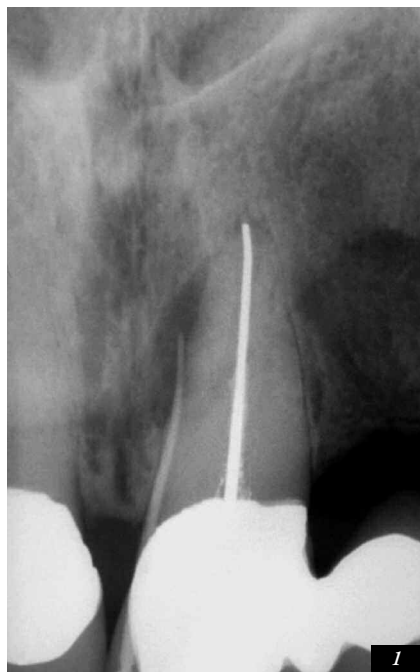
Figure 1. A pre-operative film depicting an endodontically failing maxillary central incisor bridge abutment. A gutta percha point traces a fistulous tract to a lateral root lesion.

Figure 2. This microscope is designed specifically for dentistry by Global Surgical Corp. A variety of options exist including documentation packages.

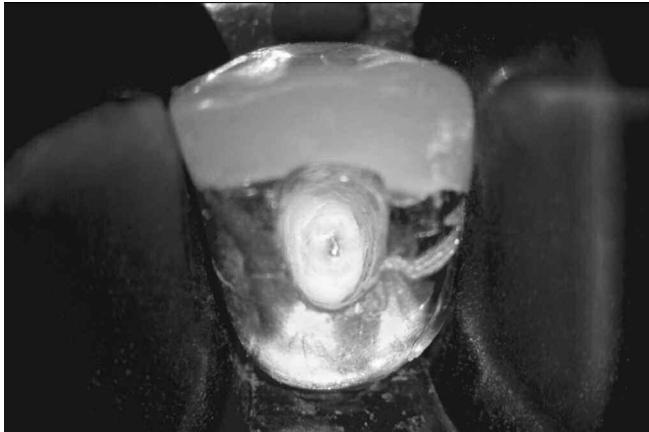


Figure 3. Microscopic view at 15X reveals lingual access and restorative build-up around the coronal-most aspect of the just exposed silver point.

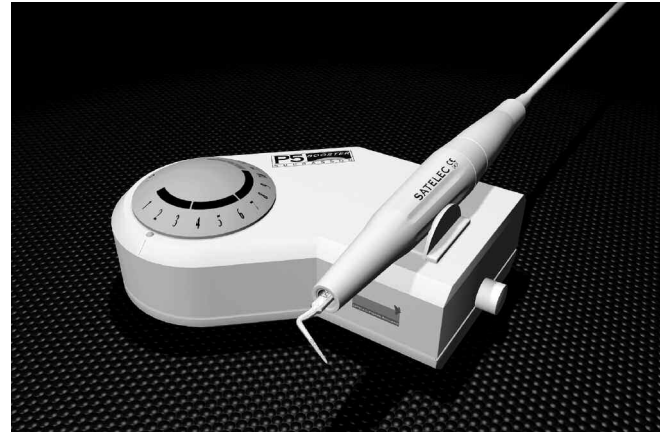


Figure 4. The Satelec P5 piezoelectric ultrasonic unit is the unit of choice due to its reliability, unsurpassed power, and clinical options.

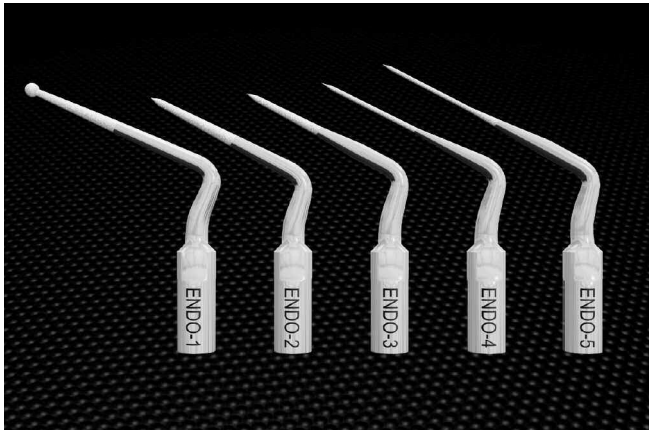

Figure 5. The ProUltra ENDO ultrasonic instruments provide significant advantages in successful endodontic treatment.

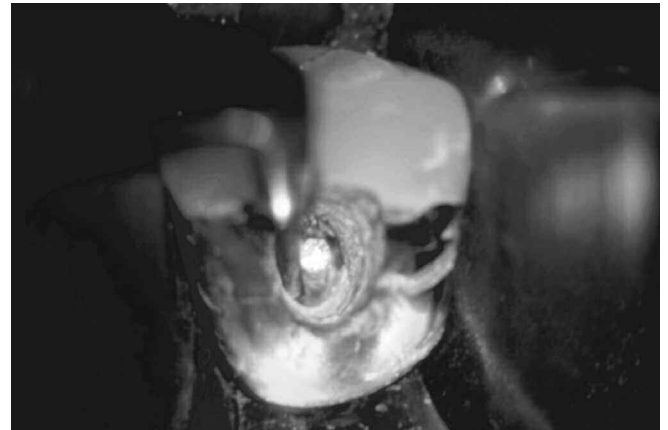


Figure 6. An ENDO-3 ultrasonic instrument works lateral to the silver point, breaking up cement and creating circumferential space.



Figure 7. Magnification at 15X reveals lingual and radicular access and an exposed silver point ready for retrieval procedures.

Occasionally, the clinician may persevere through the various removal techniques before achieving success. In good endodontics and, in particular, retreatment procedures, patience usually pays off. The liberated root canal system can be cleaned and shaped while bathed in sodium hypochlorite in preparation for three-dimensional obturation. A thermohydraulic wave of warm gutta percha and sealer accelerates, moves, and three-dimensionally fills into the root canal system (*Figure 8*). A post-operative film confirms the endodontic effort (*Figure 9*) and will serve as a baseline for comparison of future recall films (*Figure 10*). It is suggested that endodontic recall examinations continue, on an intelligent time interval, over the life of the patient.

CONCLUSION

Training, practice, and technology allow clinicians to expand their abilities in endodontic treatment and retreatment. Disassembled teeth create an opening for predictable repairs, if necessary, and three-dimensional cleaning, shaping, and obturation of root canal system anatomy. Retreatments offers phenomenal possibilities and establishes you and your practice as a center where successful outcomes are created. ▲

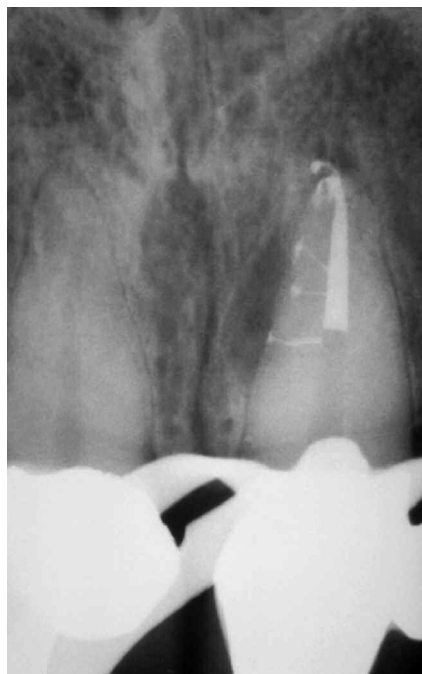

Figure 8. A working film during the down-pack reveals apical and lateral corkage. Note the mass of gutta percha apical to the most coronally positioned lateral canal.

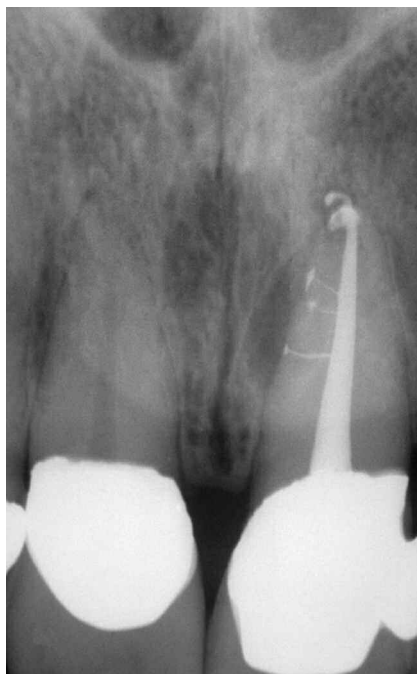

Figure 9. Following the backpack a post-operative film reveals a densely packed root canal system with surplus after filling.

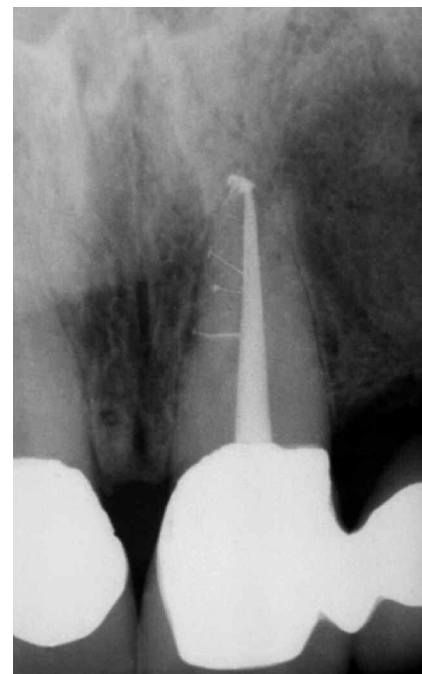

Figure 10. Five-year review demonstrates the importance of three-dimensional endodontic treatment and excellent progressive healing.

REFERENCES

1. West JD: Endodontic failures marked by lack of three-dimensional seal, *The Endodontic Report*, Fall/Winter, p. 9, 1987.
2. Ruddle CJ: Endodontic failures: the rationale and application of surgical retreatment, *Revue D'Odonto Stomatologie* 17:6, pp. 511-569, 1988.
3. Ruddle CJ: Surgical endodontic retreatment, *J Calif Dent Assoc* 19:5, pp. 61-67, 1991.
4. Machtou P, Sarfati P and Cohen AG: Post removal prior to retreatment, *J Endod* 15:552, 1989.
5. Scianamblo MJ: Endodontic failures: the retreatment of previously endodontically treated teeth, *Revue D'Odonto Stomatologie* 17:5, pp. 409-423, 1988.
6. Ruddle CJ: Microendodontics: eliminating intracanal obstructions, *Dentistry Today* 15:5, pp. 44-49, 1996.
7. Goon WWY: Managing the obstructed root canal space: rationale and technique. *J Calif Dent Assoc* 19:5, May 1991.
8. Ruddle CJ: Endodontic perforation repair: using the surgical operating microscope, *Dentistry Today* 13:5, pp. 48-53, 1994.
9. Ruddle CJ: Endodontic canal preparation: breakthrough cleaning and shaping strategies, *Dentistry Today* 13:2, pp. 44-49, 1994.
10. Ruddle CJ: Ch. 9, Three-dimensional obturation: the rationale and application of warm gutta percha with vertical condensation, In Cohen S, Burns RC, editors: *Pathways of the Pulp*, 6th ed., Mosby Yearbook Co, St. Louis, 1994.