

PREDICTABLY SUCCESSFUL ENDODONTICS

by Dr. Clifford J. Ruddle, DDS

Dr. Herbert Schilder used the title, "Predictably Successful Endodontics," to describe many of the lectures he gave over about a 40-year timeline. In the most simple and direct way, these words promise longterm treatment success that is not only possible, but attainable. Central to predictably successful treatment are those factors that serve to influence the retention of critically essential teeth. In the present state of endodontic development, the mechanical steps to achieve predictably successful results include access preparation, glide path management, shaping canals, 3D disinfection, and filling root canal systems (*Figure 1*).

Perhaps the most important factor that serves to influence clinical treatment success is to recognize that pulpal degeneration occurs within an oftentimes complex anatomical

space. Pulpal breakdown and disease flow occur along anatomical pathways and generally move in a coronal to apical direction. Secondary to pulpal breakdown, a lesion of endodontic origin (LEO) forms in the bone adjacent to a portal of exit (POE).¹ In virtually all instances, LEOs will heal following endodontics because, like the extraction, clinical treatment is directed toward eliminating all the pulp, bacteria when present, and their related irritants.

Another factor influencing success is the often misunderstood concept of minimally invasive endodontics (MIE).² Specifically, there has been a one-sided clarion call for dentists to cut small-sized access cavities, or to minimally shape canals, or to not shape canals whatsoever. Yet, the quintessential goals of clinical endodontics are to eliminate all

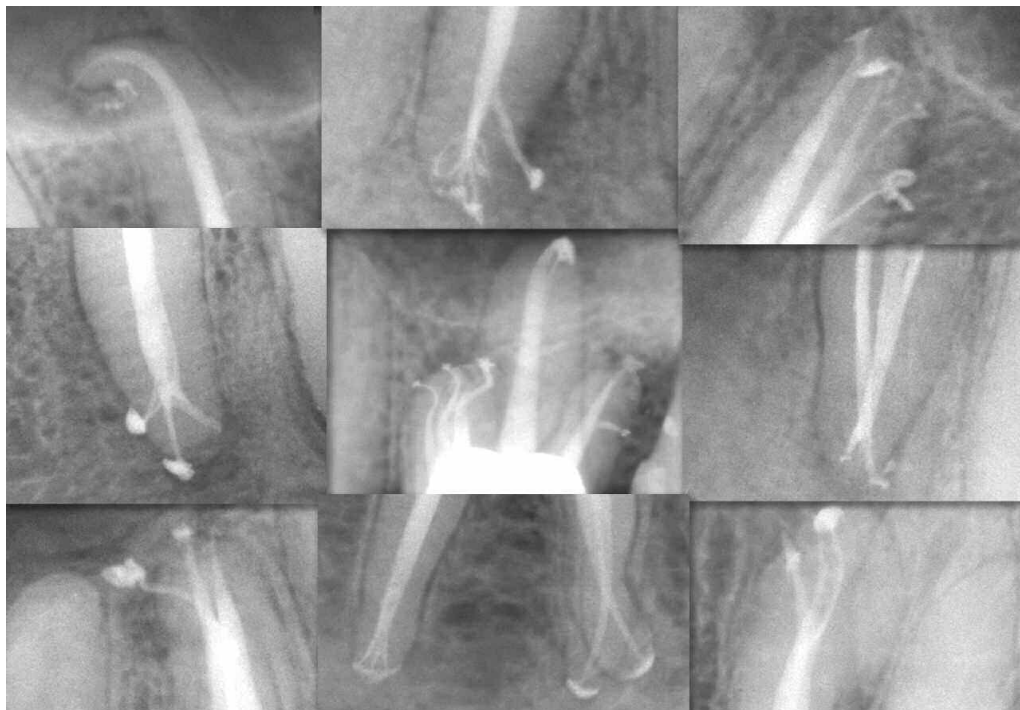

Figure 1.
This collage of post-treatment endodontic images show the results and importance of treating root canal systems.

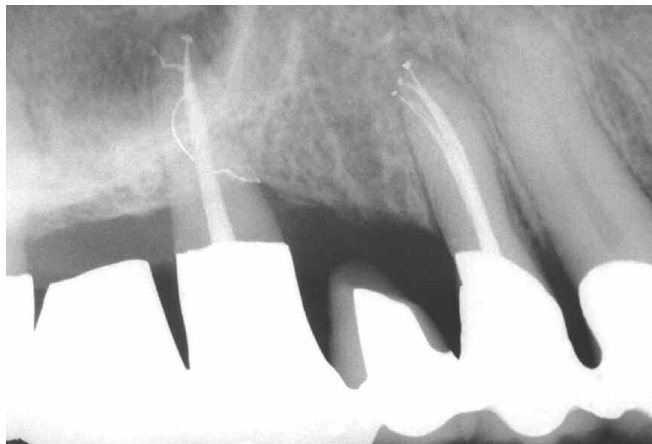

Figure 2. A 30-year recall image of teeth numbers 12 and 14 (palatal root) reveals predictably successful interdisciplinary treatment results.

organic substrate and fill root canal systems. With the current technology available, these essential goals require preparing well-shaped canals that, in turn, promote 3D cleaning and filling root canal systems (**Figure 2**). This article will focus on the current concepts for cutting access cavities and shaping canals in the context of balancing the endodontic objectives with the concept of MIE.

ENDODONTIC ACCESS

The goal of the endodontic cavity preparation is to gain access to the pulp chamber and the underlying root canal system.³ Endodontic access is the first mechanical step that will significantly influence a series of subsequent steps that serve to guide each case to a successful conclusion. With a thoughtful plan, the mechanical objectives are to penetrate, funnel, and create straightline access to any given orifice. Upon identifying an orifice, the internal axial walls should be flared, flattened, and finished. Importantly, coronal interferences are eliminated to improve radicular access.

An effective access preparation allows files to be easily inserted directly into orifices, reagents to be strategically dispensed, and, regardless of the obturation method, root canal systems to be filled. In furcated teeth, the access prepara-

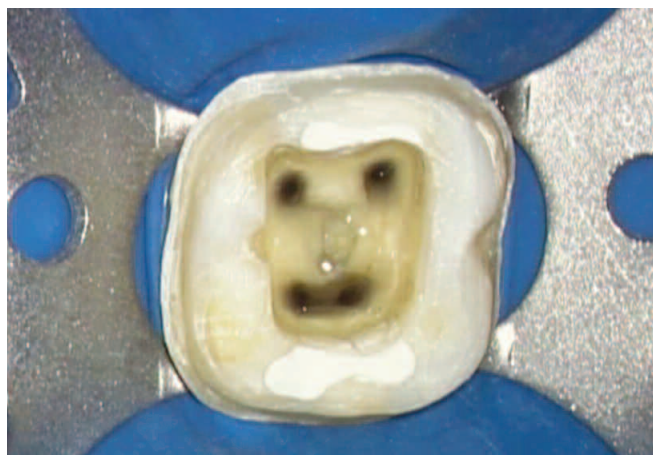

Figure 3a. A clinical photograph shows the orifices of these shaped canals smoothly blend into the axial walls of this funneled and finished access preparation.

tion is widest on the cavo surface of a tooth and progressively funnels toward the pulpal floor. All unsupported dentin and enamel should be removed, as leaving this hard tissue has not been shown to strengthen teeth. Leaving trapped tissue, debris, or residual sealer within the access preparation is well-known to contribute to staining and discoloration of the clinical crown following treatment.⁴

The goals of endodontic access and the concept of MIE are compatible and should coexist. Namely, access cavities should not be needlessly restrictive or excessively large; rather, the outline form and preparation should be just right. Ideally, access objectives are confirmed when all the orifices in furcated teeth can be visualized without moving the mouth mirror (**Figure 3**). The concept of MIE encourages maximizing healthy tissue, but, and this is most important, MIE does not mean compromising the endodontic treatment goals. To use a car engine analogy, it is illogical to repair the engine through the tailpipe, rather than simply lifting the hood.

A restrictive access preparation compromises finding orifices and effectively treating underlying root canal systems. Further, when the access preparation is too small, it becomes needlessly difficult to place files, instruments, and devices into underlying canals, or to visualize internal fractures and their extent of propagation. Histological evidence demonstrates that eliminating coronal interferences serves to protect dentin on the furcal side of multi-rooted teeth.⁵ Working through a restrictive access preparation elevates frustration and serves to compromise each and every subsequent step that comprises start-to-finish endodontics.

On the other hand, access cavities that are prepared too big structurally weaken natural or restoratively revised crowns and contribute to fractures and the premature loss of teeth. Over-prepared access cavities, with or without internally gouged axial walls, weaken tooth structure. Irregular axial walls compromise vision and frequently make it more difficult to insert instruments into any given orifice because of an iatrogenic ledge within the access cavity, itself. In the instance of multi-visit endodontics, provisionalization may become compromised in access preparations that exhibit reverse funnels.

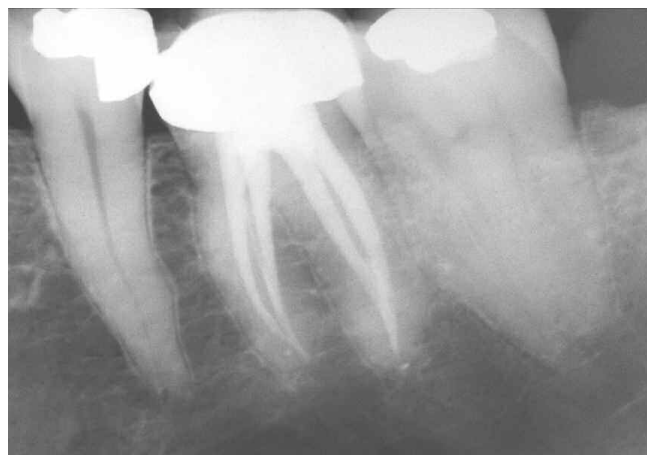

Figure 3b. A 20-year recall image demonstrates 3D endodontics and a protective restoration promote long-term success.

Neither modern-day endodontic practice nor the concept of MIE dictate which rotary cutting bur, diamond, or ultrasonically-driven instrument should be used to initiate, rough-in, or competently finish any given access preparation. When preparing the access cavity, serious clinicians recognize that it is not the type of bur that is most important. What is most important is for the clinician to understand the access concept, recognize the orientation between the crown and root, and appreciate the relative position of the pulp chamber from tooth to tooth (*Figure 4*).⁶

Anatomical examination of the coronal-most aspect of virtually all canals in furcated teeth consistently reveals they are not centered within the mesiodistal dimensions of roots. Rather, the coronal-most aspect of these canals are positioned closer to the furcal-side concavity of the root. Clinicians should deliberately use a brushing motion, on the outstroke, to eliminate triangles of dentin and intentionally relocate this aspect of the canal away from external root concavities (*Figure 5*). Histological evidence demonstrates that removing triangles of dentin results in more radicularly centered final preparations, which, in turn, makes teeth more fracture resistant.^{5,7}

Protecting furcal-side dentin comes at the expense of selectively removing cervical dentin. Restorative dentistry has identified the biological, mechanical, and esthetic guidelines required for any coronal preparation, which are based on the material utilized. Experienced dentists appreciate that, in the instance of full coverage, the buccal and lingual aspects of a circumferential ferrule are superior at resisting vertical and lateral occlusal loading than the mesial and distal aspects of the ferrule. The concept of MIE recognizes the importance of maximizing furcal side dentin, which protects against weakening roots, strip perforations, and longitudinal fractures.

ENDODONTIC CANAL PREPARATION

The mechanical necessity for preparing or shaping canals has long been recognized as an essential step in endodontic treatment. Yet, the concepts concerning the role of canal preparation have differed markedly based on the develop-

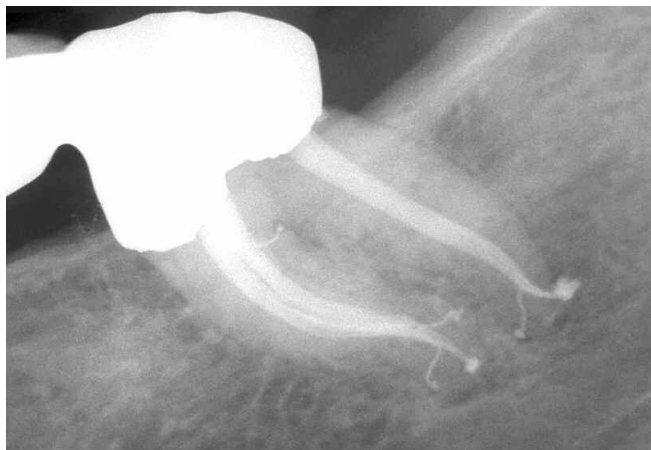

Figure 4. This post-treatment film reveals flowing multi-planar shapes to length. Note the 6 filled furcal and apical POEs.

ment of endodontics at any given period of time. Over the past decades, root canal preparation has been described in different ways, including instrumentation, biomechanical instrumentation, and chemomechanical instrumentation. Each has something to offer, has been described in its own way, and is intended to forward the thinking and actual manner in which root canals are prepared. However, none of these instrumentation concepts conveys the actual objectives of root canal preparation.

In 1974, Dr. Herb Schilder precisely described the mechanical objectives for preparing a canal that, when fulfilled, would ensure the biological goals for longterm success.⁸ It is noteworthy that these objectives were published long before any proposal of the more contemporary concepts of minimally invasive dentistry and, more recently, MIE. The paradox for dentists is, whereas the Schilderian objectives have undergone rigorous scientific and clinical scrutiny for over 40 years, MIE is a concept that has yet to be defined, has no clinical guidelines, and is currently being exploited with virtually no published scientific evidence.

Shaping refers to the conscious development of a preparation that is unique, specific, and appropriate for any given root canal and its corresponding root. Schilder used the expression, "the look," to describe any well-shaped canal that appropriately enlarges, mechanically reproduces, and flows with the original anatomy of the root canal (*Figure 4*). Shaping canals creates sufficient space to hold an effective reservoir of irrigant that, upon activation, can penetrate, circulate, and digest tissue from the uninstrumentable portions of a root canal system.⁹ Histological μ CT images emphasize the importance of shaping canals, which, in turn, facilitates the exchange of irrigants, 3D cleaning, and filling root canal systems (*Figure 6*).¹⁰

Just like the endodontic access preparation, any given canal can be underprepared, overprepared, or prepared just right in accordance with Schilderian principles. Histological examination of endodontic failures routinely demonstrates that underprepared canals, although instrumented, are neither shaped nor cleaned (*Figure 7*).¹¹ Underprepared canals limit the effective exchange of irrigant into all aspects of the root

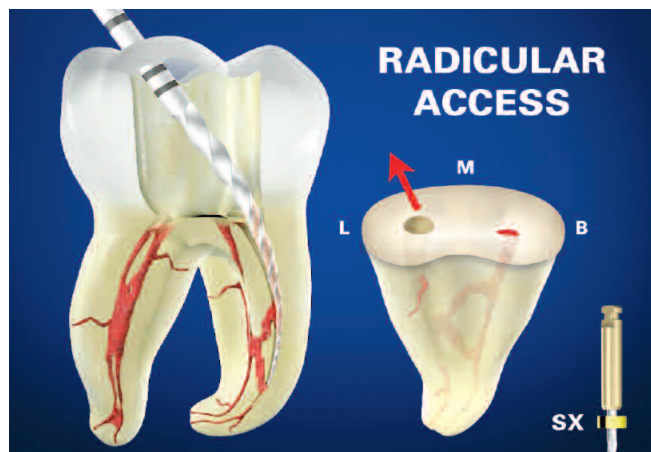


Figure 5. This animation shows the ProTaper Sx file brush-cutting on the outstroke. The inset image emphasizes relocating the ML canal away from furcal danger.

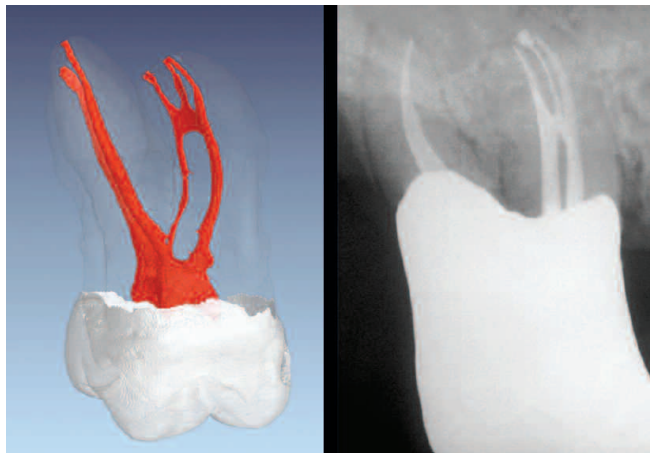


Figure 6. This μ CT image reveals a third system originating off the anastomosis between the MB1 and MB2 canals (Courtesy of Dr. Frank Paqué; Zurich, Switzerland). My 25-year recall of the buccal roots of tooth #3 depicts similar MB root anatomy and the longterm outcome of interdisciplinary treatment.

canal system. Certainly, underprepared canals harbor residual pulpal remnants, oftentimes bacteria and debris that continue to be a major cause of post-treatment disease. Universally, underprepared canals rarely exhibit filled root canal systems.

On the contrary, overprepared canals violate both the mechanical objectives of canal preparation and the concept of MIE. Coronally overprepared canals weaken roots, predispose to hopeless fractures, and invite strip perforations. Contrary to what has been reported, the Schilderian shaping objectives do NOT obligate dentists to make round canals in irregular cross-sections, nor command dentists to shape canals to the radiographic apex, a frequently misused term. Further, there is a misunderstanding regarding preparing a canal to a continuous taper.

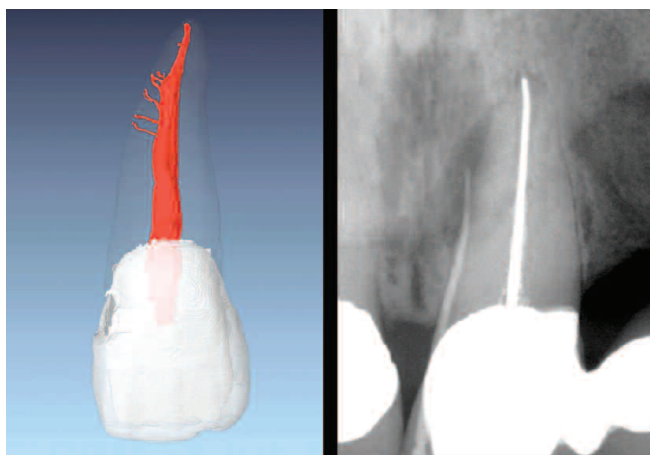


Figure 7a. This μ CT image shows a maxillary central incisor root canal system (Courtesy of Dr. Frank Paqué; Zurich, Switzerland). My pre-op film reveals an endodontically failing anterior bridge abutment. Note a gutta percha point tracing a sinus tract to a laterally-positioned LEO.

Virtually all non-manipulated canals exhibit natural taper over their length. As such, good shaping techniques reproduce this original anatomical form, emphasize deep shape, and consciously focus on a more conservative tapered shape in the body of the root. More than a decade ago and long before the concept of MIE was introduced, the ProTaper system's Finishing files (*Dentsply Tulsa Dental Specialties*) were designed with fixed tapers from D1-D3, then decreasing percentage tapers from D4-D16 to conserve dentin in the body of the canal.¹² For example, a regressively tapered ProTaper 25/08 Finishing file has a D16 diameter of 1.05 mm, whereas a fixed tapered 25/08 file would have a D16 diameter of 1.53 mm.

Another misunderstanding that continues to sabotage success is over-enlarging the terminal extent of canals.¹¹ Histological evidence demonstrates the importance of deep shape by showing a 40/06 preparation is no cleaner than a 20/10 preparation.¹³ It is interesting to note that the 20/10 file utilized in this study has a maximum flute diameter of 1.00 mm vs. the 1.80 mm that would be expected if the fixed taper extended over 16 mm of cutting blades. Importantly, overpreparing the foramen leads to wet canals, post-treatment flare-ups, surgeries, and extractions. Evidence is readily available that demonstrates that well-shaped canals that emphasize keeping the foramen *as small as practical* readily exchange irrigants throughout the root canal system.^{14,15} Overprepared canals, or what have been termed "freeways to length," are the antithesis to Schilder's mechanical shaping objectives.

MISFORMATION

In the 40 years I have been practicing endodontics, I have not seen what has been termed as "an epidemic of fractured teeth," even after routinely utilizing a microscope since 1988. What I have seen is a number of post-treatment failures resulting from not placing an effective coronal restora-

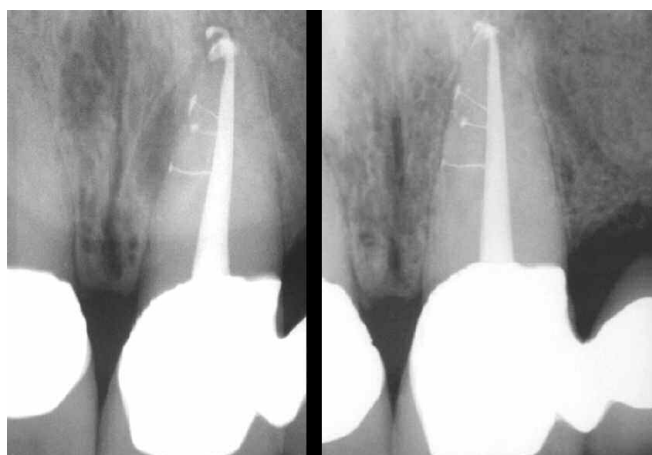


Figure 7b. The left post-treatment image shows the importance of treating root canal systems. The right image is a 22-year recall showing the inevitable potential for healing following complete treatment.

tion. However, the article entitled, "Fracture Resistant Endodontic and Restorative Preparations," in the February 2013 issue of *Dentistry Today*, attributes an endodontic failure to over-funneling the coronal two-thirds of a canal. Yet, multiple photographs of this same extracted tooth show a large invasive Class II composite restoration with no protective cuspal coverage. Certainly, overprepared canals weaken roots, but it is undeniable that unrestored, endodontically treated posterior teeth, left to occlusal loads, frequently and hopelessly fracture.¹⁶

In the above referenced article, the author states that "intentional shaping directed toward achieving some kind of 'look' may result in a tooth that exhibits what many might characterize as 'endodontic excellence' yet is crippled in the process, even before the restorative needs are considered (Figure 19)." This statement is arrogant and represents both misinformation and scientific misconduct. The referenced figure shows a tooth I endodontically treated, but my post-treatment image was published without my knowledge or permission. For the record, following my endodontic treatment, the prosthesis was fabricated, placed, and a recall

radiograph at 27 years demonstrates the interdisciplinary result (**Figure 8**). It is my hope that members of the dental profession, authors in particular, would perform necessary due diligence prior to publishing.

FUTURE

Predictably successful endodontics is currently dependent on preparing the access cavity, shaping canals, and cleaning and filling root canal systems. Going forward, the question that must be scientifically answered is, how restrictive can any given access cavity or root canal be prepared, and - this is most important - still enable the root canal system to be both 3D cleaned and filled? Until this question is universally answered in collaborative research, it would be wise to continue to practice utilizing the best evidence, coupled with the most proven treatment concepts and techniques. There is an old expression, "Model success. Success leaves clues." Longterm endodontic treatment success should integrate respect for the concept of MIE, while concomitantly fulfilling the mechanical and biological treatment objectives. ▲

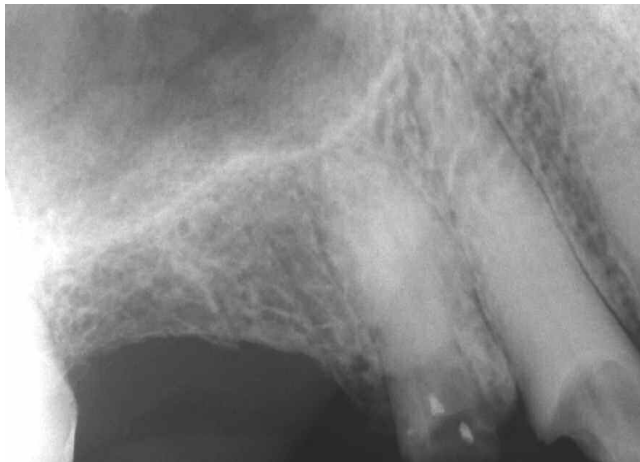

Figure 8a. My 1983 pre-op radiographic image reveals coronally broken down and endodontically involved teeth #s 5 and 6.

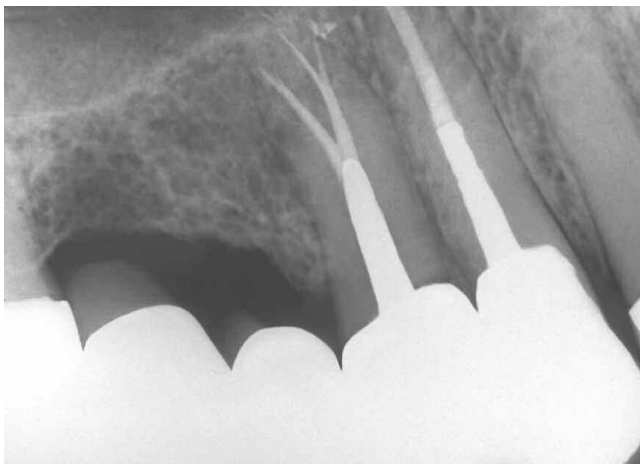


Figure 8c. A 27-year recall film in 2010 demonstrates predictably successful interdisciplinary results.

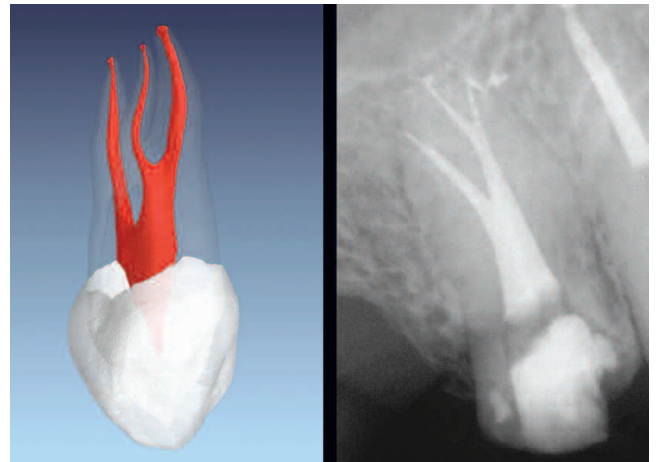


Figure 8b. A μCT image of a maxillary first bicuspid shows 3 systems and an anatomically broad isthmus between the buccal and lingual canals (Courtesy of Dr. Frank Paqué; Zurich, Switzerland). My post-treatment film reveals the buccal and lingual systems are joined by a deep and broad isthmus that extends to mid-root. Note the buccal and lingual canals bifurcate at mid-root and the lingual system bifurcates in its apical one-third.

REFERENCES

1. Schilder H: Ch. 6, Canal debridement and disinfection. In *Pathways of the Pulp*, 1st ed, St. Louis: Mosby Co, 1976.
2. Ruddle CJ: Focus on: Minimally invasive endodontics, *Dent Today* 33:4, 2014.
3. Ruddle CJ: Microdentistry: identification & treatment of MBII systems, *J Calif Dent Assoc* 25:4, 1997.
4. Ahmed HM, Abbott PV: Discolouration potential of endodontic procedures and materials: a review, *Int Endod J* 45:10, pp. 883-897, 2012.
5. Ruddle CJ: The protaper technique, *Endodontic Topics* 10:187-190, 2005.
6. Ruddle CJ: Endodontic access preparation: an opening for success, *Dent Today* 26:2, pp. 114-119, February 2007.
7. Ruddle CJ: Ch. 8, Cleaning and shaping root canal systems. In *Pathways of the Pulp*, 8th ed., Cohen S, Burns RC, eds. St. Louis: Mosby, pp. 231-291, 2002.
8. Schilder H: Cleaning and shaping the root canal, *Dent Clin North Am* 18:2, pp. 269-296, April 1974.
9. Ruddle CJ: Endodontic disinfection: tsunami irrigation, *Endodontic Practice* 11:1, pp. 7-15, 2008.
10. Schilder H: Filling root canals in three dimensions, *Dent Clin North Am* pp. 723-744, November 1967.
11. Ruddle CJ: Ch. 25, Nonsurgical endodontic retreatment. In *Pathways of the Pulp*, 8th ed., Cohen S, Burns RC, eds., St. Louis: Mosby, pp. 875-929, 2002.
12. Ruddle CJ: The protaper endodontic system: geometries, features, and guidelines for use, *Dentistry Today* 20:10, pp. 60-67, 2001.
13. Albrecht LJ, Baumgartner JC, Marshall JG: Evaluation of apical debris removal using various sizes and tapers of profile GT files, *J Endod* 30:6, pp. 425-428, 2004.
14. Caron, G, Nham K, Bronnec F, Machtou P: Effectiveness of different final irrigant protocols on smear layer removal in curved canals, *J Endod* 36:8, pp. 1361-1366, 2010.
15. Kanter V, Weldon E, Nair U, Varella C, Kanter K, Anusavice K, Pileggi R: A quantitative and qualitative analysis of ultra sonic versus sonic endodontic systems on canal cleanliness and obturation, *Oral Surg Oral Med Oral Pathol Oral Radiol Endod* 112:6, pp. 809-813, 2011.
16. Goodacre CJ, Spolnik KJ: The prosthodontic management of endodontically treated teeth: a literature review. Part III. Tooth preparation considerations, *J Prosthodont* 4:2, pp. 122-128, 1995.