

NONSURGICAL ENDODONTIC RETREATMENT

by Clifford J. Ruddle, D.D.S.

There has been massive growth in endodontic treatment in recent years. This increase in clinical activity can be attributable to better-trained dentists and specialists alike. Necessary for this unfolding story is the general public's growing selection for root canal treatment as an alternative to the extraction.¹ Over time, patients have become more confident selecting endodontic treatment because of the changing perception that pain can be managed, techniques have improved and success is achievable. During the last decade, significant procedural refinements have created greater promise for our profession to fulfill the public's growing expectations for longterm success. This article will focus on the concepts, strategies, and techniques that will produce successful results in nonsurgical endodontic retreatment.

RATIONALE FOR RETREATMENT

Root canal system anatomy plays a significant role in endodontic success and failure.^{2,4} These systems contain branches that communicate with the periodontal attachment apparatus furcally, laterally, and often terminate apically into multiple portals of exit.⁵ Consequently, any opening from the root canal system (RCS) to the periodontal ligament space should be thought of as a portal of exit (POE) through which potential endodontic breakdown products may pass.^{6,7}

Improvement in the diagnosis and treatment of lesions of endodontic origin (LEO) occurs with the recognition of the interrelationships between pulpal disease flow and the egress of irritants along these anatomical pathways (*Figure 1*).⁸

Endodontic failures can be attributable to inadequacies in shaping, cleaning and obturation, iatrogenic events, or re-infection of the root canal system when the coronal seal is lost after completion of root canal treatment.⁹⁻¹² Regardless of the etiology, the sum of all causes is leakage and bacterial contamination.^{13,14} Except in rare instances, lesions of endodontic origin will routinely heal following the extraction of pulpally involved teeth because the extraction not only removes the tooth, but more importantly serves to eliminate 100% of the contents of the root canal system. Endodontic treatment can approach 100% success discounting teeth that are nonrestorable, have hopeless periodontal disease or have radicular fractures.⁸

GOALS OF NONSURGICAL ENDODONTIC RETREATMENT

Before commencing with any treatment, it is profoundly important to consider all interdisciplinary treatment options in terms of time, cost, prognosis and potential for patient satisfaction. Endodontic failures must be evaluated so a decision can be made among nonsurgical retreatment, surgical

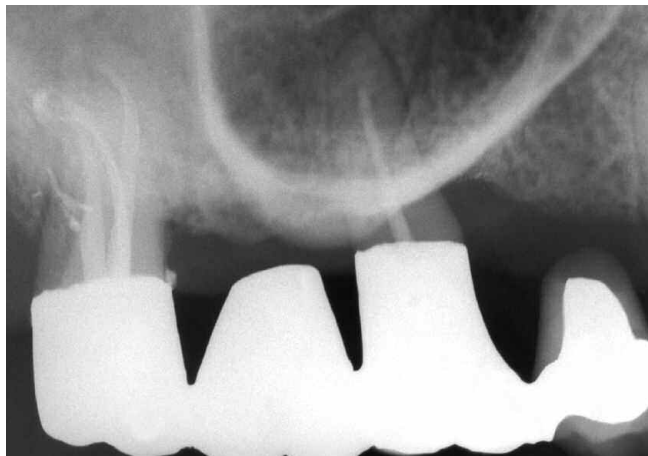

Figure 1a. A pre-operative film shows the maxillary left first molar's remaining palatal root is endodontically failing.

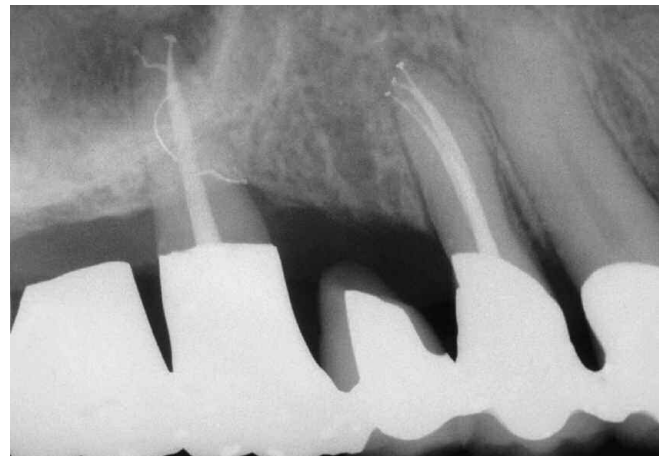


Figure 1b. Nonsurgical retreatment demonstrates a mesiocrestal lateral canal, a loop and an apical bifidity. Three-dimensional endodontics is the foundation of perio-prosthetics.

retreatment, or extraction.¹⁵⁻¹⁷ The goals of nonsurgical retreatment are to remove materials from the root canal space and if present, address deficiencies or repair defects that are pathologic or iatrogenic in origin.¹⁸ Additionally, nonsurgical retreatment procedures confirm mechanical failures, previously missed canals or radicular subcrestal fractures. Importantly, disassembly and corrective procedures allow clinicians to shape canals and three-dimensionally clean and pack root canal systems.^{19,20} Nonsurgical endodontic retreatment procedures have enormous potential for success if the guidelines for case selection are respected and the most relevant technologies, best materials and precise techniques are utilized.²¹⁻²³

CORONAL ACCESS

Clinicians typically access the pulp chamber through an existing restoration if it is judged to be functionally designed, well-fitting and esthetically pleasing.²⁴ If the restoration is deemed inadequate and/or additional access is required, then it should be sacrificed. However, on specific occasions,

it may be desirable to remove the restoration intact so it can be re-cemented following endodontic treatment.¹⁸ Several important technologies exist which facilitate the safe removal of a restorative. Coronal disassembly improves access, vision and the retreatment efforts.

The safe dislodgment of a restoration is dependent on several factors such as the type of preparation, the restorative design and strength, the restorative material(s), the cementing agent and knowing how to use the best removal devices. There are several important removal devices which may be divided into three categories: (1) Grasping instruments, such as K.Y. Pliers (*GC America*) and Wynman Crown Gripper (*Miltex Instrument Company*), (2) Percussive instruments like the Peerless Crown-a-Matic (*Henry Schein*) and the Coronaflex (*KaVo America*), and (3) Passive-active instruments such as the Metalift (*Classic Practice Resources*), the Kline Crown Remover (*Brasseler*) and the Higa Bridge Remover (*Higa Manufacturing*). Clinicians must clearly define the risk versus benefit with patients before commencing with the safe and intact removal of an existing restorative (*Figure 2*).

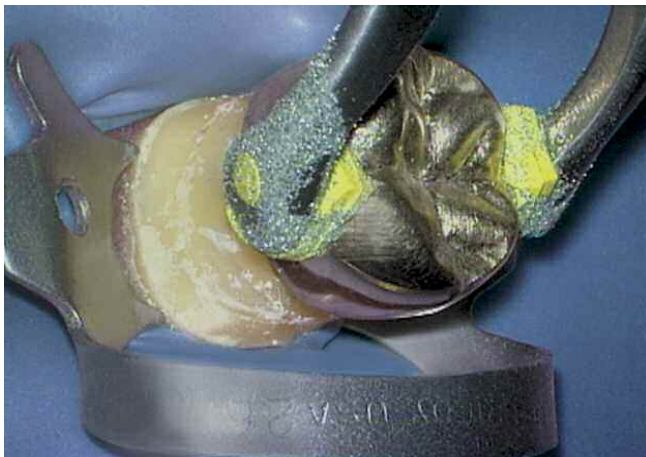


Figure 2a. A photograph demonstrates removal of a crown utilizing the K.Y. Pliers. Note the grasping pads have been dipped in emery powder to reduce slippage.

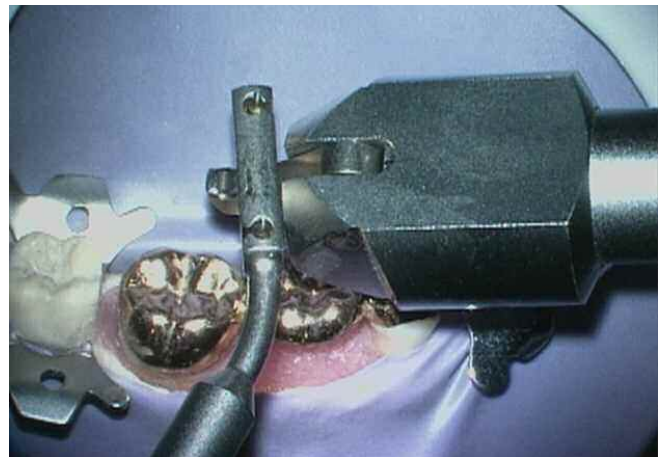


Figure 2b. A photograph demonstrates bridge removal utilizing the Coronaflex. The air driven hammer generates the removal force against various prosthetic attachment devices.

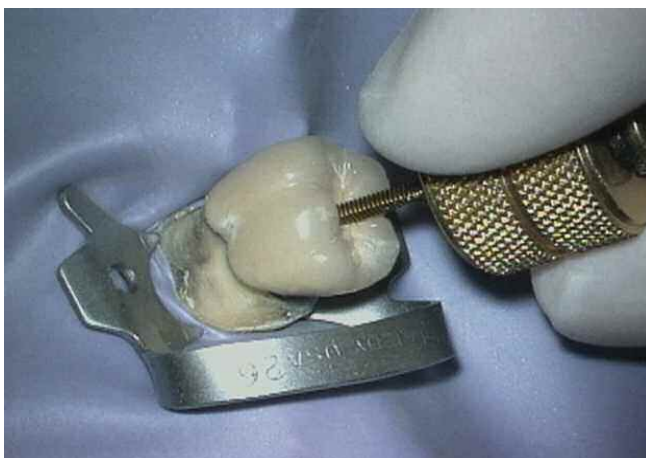


Figure 2c. A photograph demonstrates the removal of a PFM crown utilizing the Metalift. This system applies a force between the crown and the tooth.

MISSED CANALS

Missed canals hold tissue, and at times bacteria and related irritants that inevitably contribute to clinical symptoms and lesions of endodontic origin.⁹ Oftentimes, surgical treatment has been directed towards “corking” the end of the canal with the hopes that the retrograde material will incarcerate biological irritants within the root canal system over the life of the patient.¹⁴ Although this clinical scenario occurs anecdotally, it is not as predictable as nonsurgical retreatment. Endodontic prognosis is maximized in teeth whose root canals are shaped and root canal systems cleaned and packed in *all* their dimensions (*Figure 3*).^{5,8}

There are multiple concepts, armamentarium and techniques that are useful to locate canals. The most reliable method for locating canals is to have knowledge regarding root canal system anatomy and appreciation for the range of variation commonly associated with each type of tooth.³ Frequently used methods for identifying canals include: radiographic analysis, magnification and lighting (microscopes), complete

access, firm explorer pressure, ultrasonics, Micro-Openers (*Dentsply Tulsa Dental*), dyes, sodium hypochlorite, color and texture, removing restorations, and probing the sulcus. However, if a missed canal is suspected but cannot be readily identified and treated, then an endodontic referral may be prudent to avoid complications. Caution should be exercised when contemplating surgery due to the aforementioned concerns, but at times may be necessary to retain the tooth.

OBTURATION MATERIALS

There are four commonly encountered obturation materials found in root canals. These materials are gutta percha, carrier-based obturators, silver points and paste fillers. Generally it is necessary to remove an obturation material to achieve endodontic retreatment success or to facilitate placing a post for restorative reasons. The effective removal of an obturation material requires utilizing the most proven methods from the past in conjunction with the best presently developed techniques.

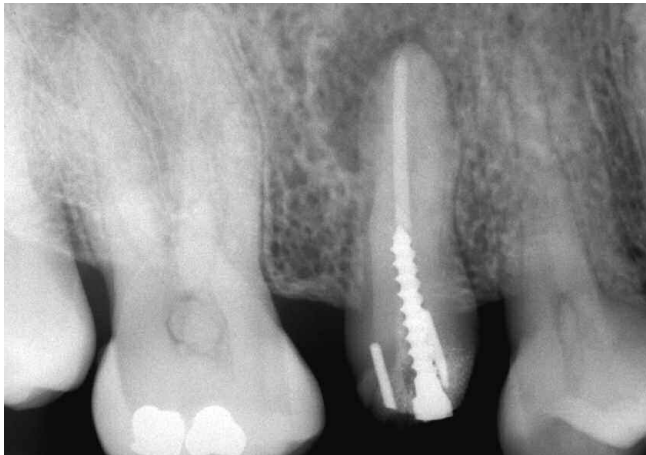

Figure 3a. A radiograph of a maxillary right second bicuspid reveals pins, a post, incomplete endodontics and an asymmetrical lesion.

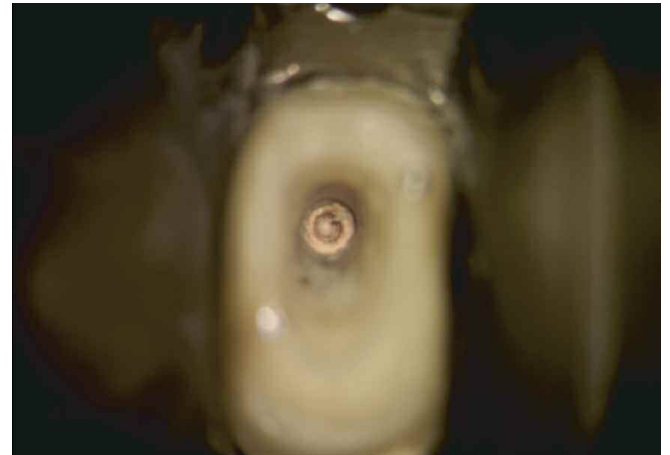


Figure 3b. A photograph at 12x shows the post is out of the buccal canal, thread marks in the gutta percha from the screw post, and evidence of a missed lingual system.

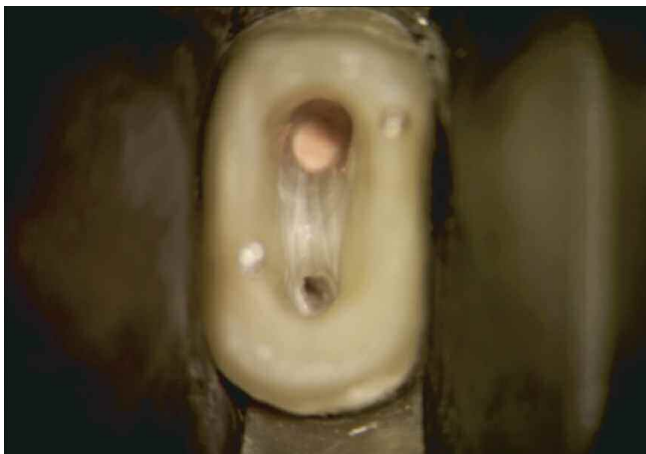

Figure 3c. A photograph at 12x demonstrates complete access and identification of the lingual orificesystem.

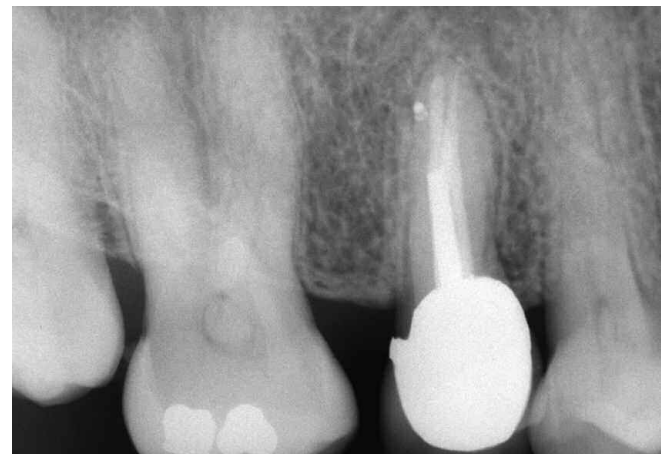

Figure 3d. A 10-year recall radiograph shows excellent osseous repair, the importance of 3-D endodontics, and a well-designed and sealed restorative.

GUTTA PERCHA REMOVAL

The relative difficulty in removing gutta percha varies according to the obturation technique previously employed and further influenced by the canal's length, cross-sectional dimension, curvature and internal configuration. Regardless of technique, gutta percha is best removed from a root canal in a progressive manner to prevent inadvertent displacement of irritants periapically. Dividing the root into thirds, gutta percha may be initially removed from the canal in the coronal one-third, then the middle one-third, and finally eliminated from the apical one-third. At times, single cones in larger and straighter canals can be removed with one instrument

in one motion. For other canals, there are a number of possible gutta percha removal schemes.¹⁸ The removal techniques include rotary files, ultrasonic instruments, heat, hand files with heat or chemicals, and paper points with chemicals.²⁵ Of these options, the best technique(s) for a specific case is selected based on preoperative radiographs, clinically assessing the available diameter of the orifices after re-entering the pulp chamber, and clinical experience. Certainly, a combination of methods are generally required and, in concert, provide safe, efficient and potentially complete elimination of gutta percha and sealer from the internal anatomy of the root canal system (*Figure 4*).

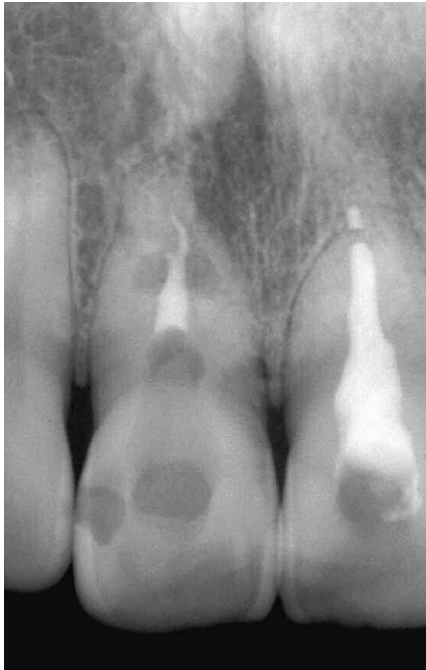

Figure 4a. A pre-operative radiograph of a maxillary central incisor demonstrates inadequate endodontics, resorption and apical one-third pathology.

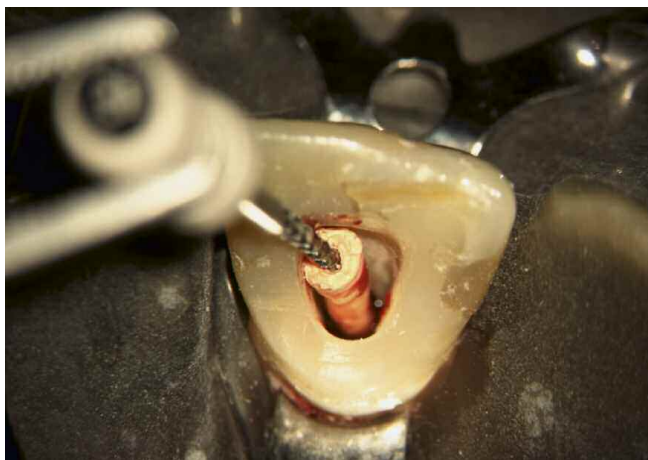


Figure 4b. A photograph at 8x shows a 45 hedstroem mechanically removing the heat softened single cone of gutta percha.

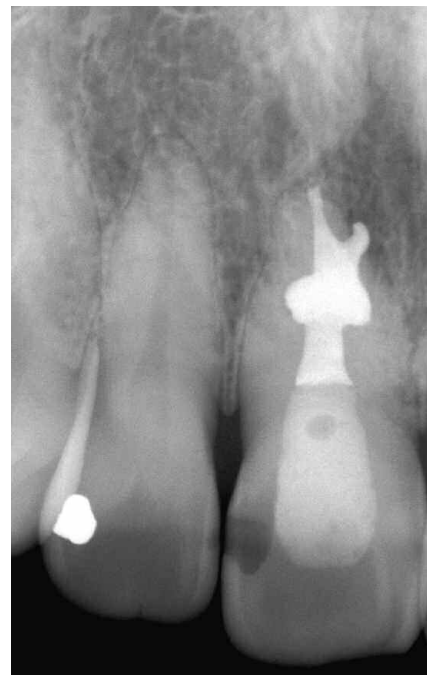


Figure 4c. A post-operative radiograph shows the nonsurgical retreatment result and three-dimensional obturation.

SILVER POINT REMOVAL

The relative ease of removing a silver point is based on the fact that chronic leakage reduces the seal and hence, the lateral retention. Access preparations must be thoughtfully planned and carefully performed to minimize the risk of inadvertently foreshortening any given silver point. Initial access is accomplished with highspeed, surgical length cutting tools, then oftentimes ultrasonic instruments are used to brush-cut away remaining restorative materials and fully expose the silver point.

Different techniques have been developed for removing silver points depending on their lengths, diameters, and positions they occupy within the root canal space (*Figure 5*).^{23,26,27} Certain removal techniques evolved to address silver points that bind in unshaped canals over distance. Other techniques arose to remove silver points with large cross-sectional diameters, approaching the size of smaller posts. Finally, other techniques are necessary to remove intentionally sectioned silver points lying deep within the root canal space. The more effective methods for removing silver points include: grasping pliers utilizing the principles of fulcrum mechanics, indirect

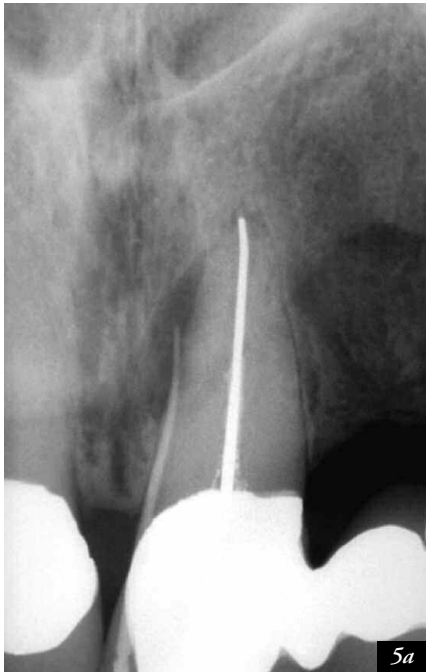

Figure 5a. A pre-operative radiograph depicting an endodontically failing maxillary central incisor bridge abutment, a gutta percha point tracing a fistulous tract to a large lateral root lesion, and a canal underfilled and slightly overextended.

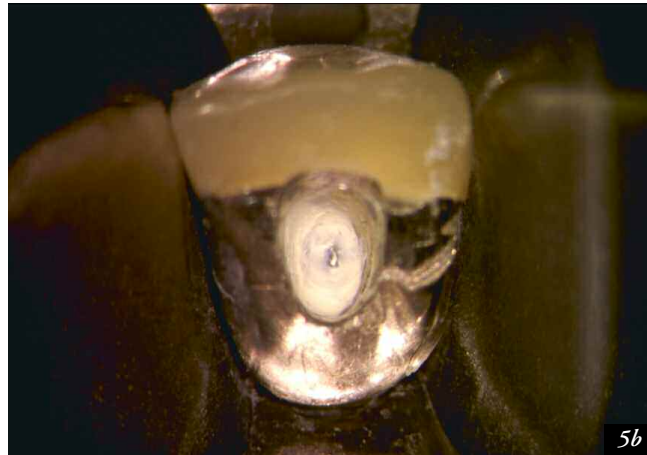


Figure 5b. Magnification at 15x reveals lingual access and restorative build-up around the coronal-most aspect of the exposed silver point.

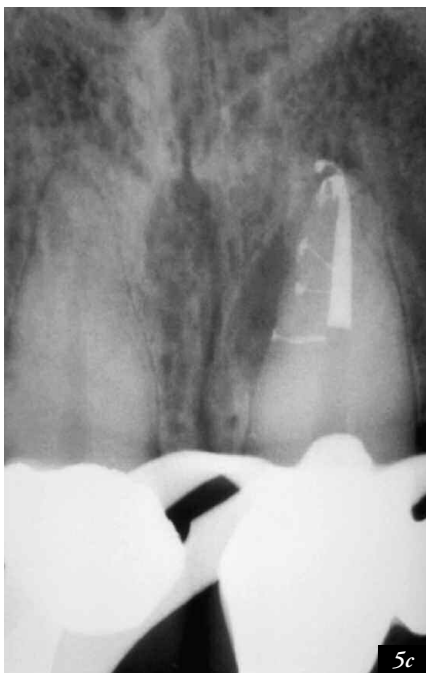

Figure 5c. A working radiograph during the downpack reveals apical and lateral corkage.

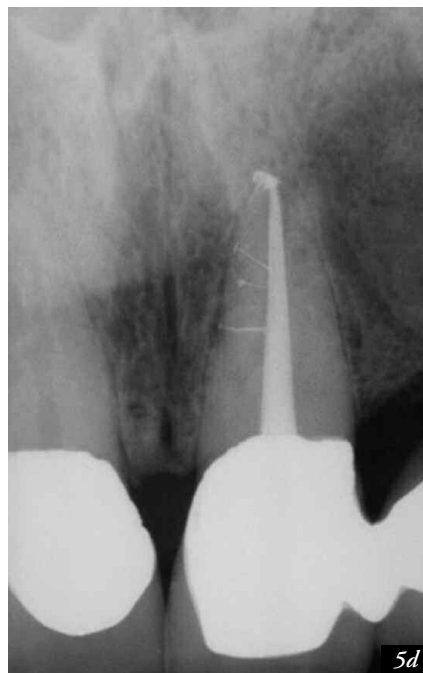

Figure 5d. A 5-year review demonstrates that three-dimensional endodontic treatment promotes healing.

ultrasonics, files, solvents, chelators, the hedstroem displacement technique, tap and thread option using the microtubular taps from the Post Removal System kit (*SybronEndo*), and microtube mechanics such as the Instrument Removal System (*Dentsply Tulsa Dental*).¹⁸

CARRIER REMOVAL

Gutta percha carriers were originally metal and file-like, yet over the past several years they have been manufactured from easier-to-remove plastic carriers that have a longitudinal groove. Metal carriers, although no longer distributed, are occasionally encountered clinically and can be more difficult to remove than silver points because their cutting flutes at times engage lateral dentin.²⁸ Successful removal is enhanced by recognizing that the carrier is frozen in a sea of hardened gutta percha and sealer. The successful removal of carrier-based obturators utilizes the same techniques described for removing gutta percha and silver points.¹⁸ However, successful removal poses additional challenges to the aforementioned obturation techniques in that the clinician must remove *both* the gutta percha *and* the carrier (*Figure 6*). Oftentimes, the biggest secret to remove a carrier is to

appreciate the importance of first removing circumferential gutta percha which will facilitate removing the carrier-based obturator.

PASTE REMOVAL

When evaluating a paste case for retreatment, it is useful to clinically understand that pastes can generally be divided into soft, penetrable and removable versus hard, impenetrable, and at times, unremovable. Fortuitously, the paste is more dense in the coronal portion of the canal and the material is progressively less dense moving apically due to the method of placement (*Figure 7*). Before retreatreating a paste-filled canal, the clinician should anticipate calcifications, resorptions, and the possibility that the removal efforts may be unsuccessful. Importantly, patients should be advised there could be a higher incidence of flare-ups associated with these retreatment cases.

An excellent technique for the safe removal of hard, impenetrable paste from the straightaway portion of a canal utilizes abrasively coated ultrasonic instruments in conjunction with the microscope. To remove paste apical to canal curvature,

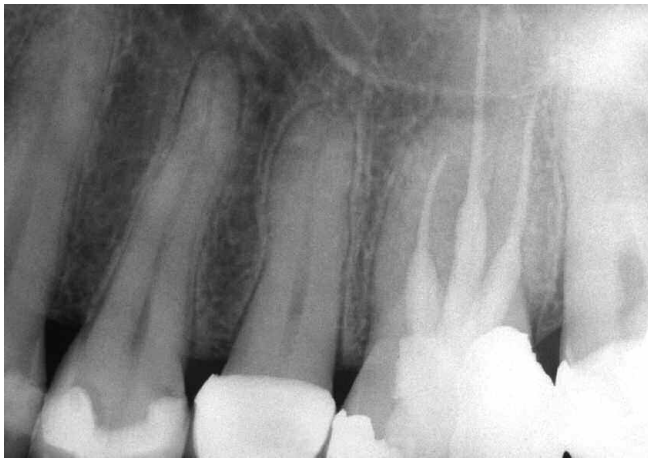

Figure 6a. A radiograph of a maxillary right first molar demonstrates "coke bottle" preparations and carrier-based obturation of three canals.

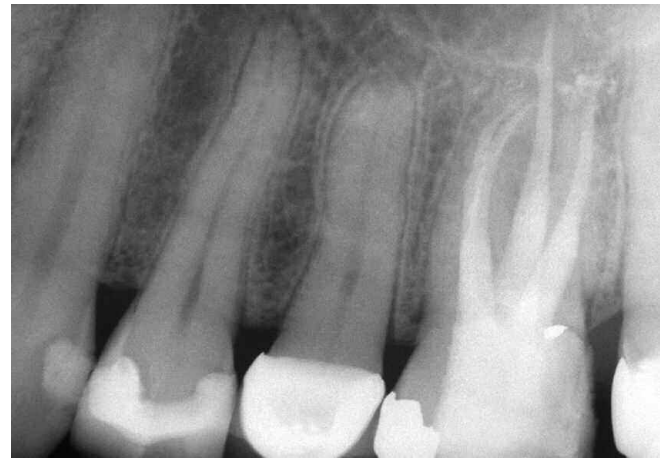

Figure 6b. A post-operative radiograph reveals the retreatment efforts, including the identification and treatment of a second MB root canal system.

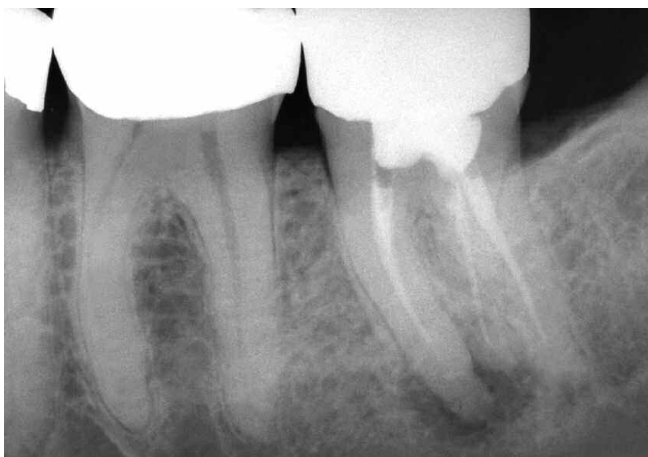

Figure 7a. A pre-operative radiograph of an endodontically failing paste-filled mandibular left second molar. Note the extra DL root.

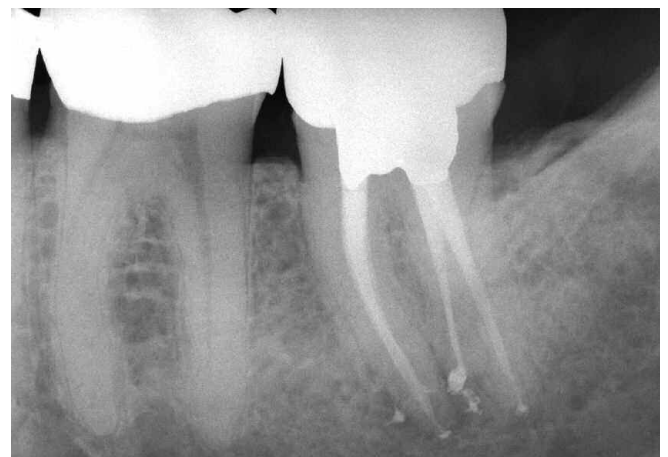

Figure 7b. A 5-year recall film shows the treatment of multiple apical portals of exit and excellent osseous healing.

hand instruments should first be utilized to establish or confirm a safe glide path. Precurved stainless steel hand files may be inserted into this secured region of the canal and when attached to a "file adapter", may be activated utilizing ultrasonic energy.¹⁸ Other removal methods include heat, judicious use of end-cutting rotary NiTi instruments and small sized hand files with solvents such as Endosolv R and Endosolv E (*Endoco*).²⁹ Additionally, Micro-Debriders (*Dentsply Maillefer*) and paper points in conjunction with solvents play an important role in removing paste from canal irregularities.

POST REMOVAL

Endodontically treated teeth frequently contain posts that need to be removed to facilitate successful nonsurgical retreatment.³⁰ Factors that will influence post removal are

post diameter, length and the cementing agent. Other factors that will influence removal are whether the post is parallel versus tapered, stock versus cast, actively engaged versus non-actively retained, metallic versus non-metallic compositions, and the post head configuration. Additionally, other considerations include available interocclusal space, existing restorations and if the post head is supra- or sub-crestal. Over time, many techniques have been advocated for removal of posts.³¹ Before initiating any post removal method, all materials circumferential to the post must be eliminated and the orifice to the canal visualized (*Figure 8*).

ULTRASONIC OPTION

The first line of offense to remove a post is to utilize piezoelectric ultrasonic energy. An ultrasonic generator in conjunction with the correct insert instrument will transfer energy, powerfully vibrate, and dislodge most posts. A frequent

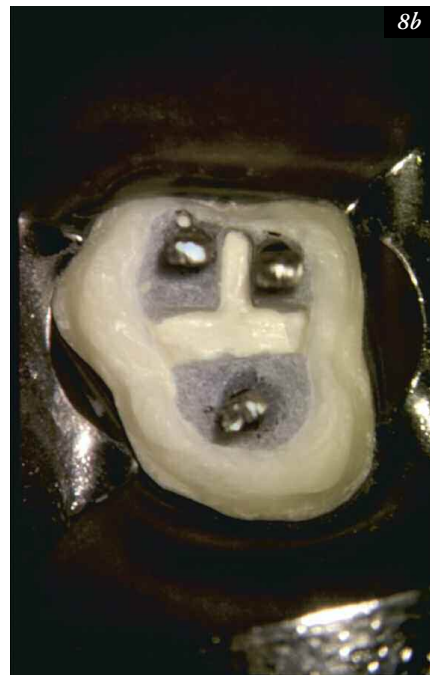
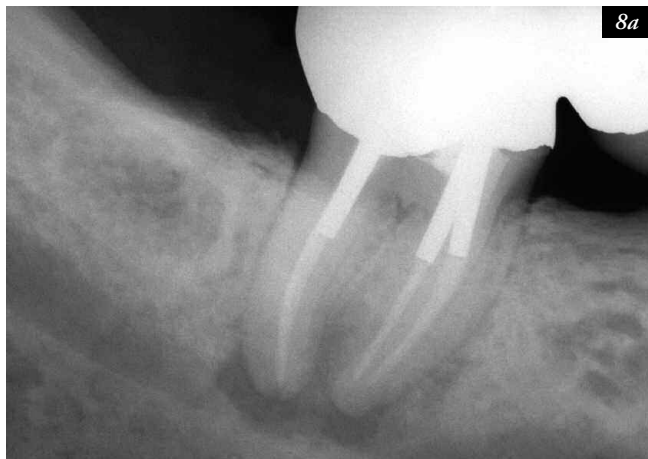
Figure 8a. A pre-operative radiograph of a mandibular right second molar bridge abutment demonstrates three posts, previous endodontics, and apical pathology.

Figure 8b. Following coronal disassembly, the isolated tooth reveals the core sectioned and reduced. Ultrasonics may then be utilized to eliminate all restorative materials circumferential to the posts.

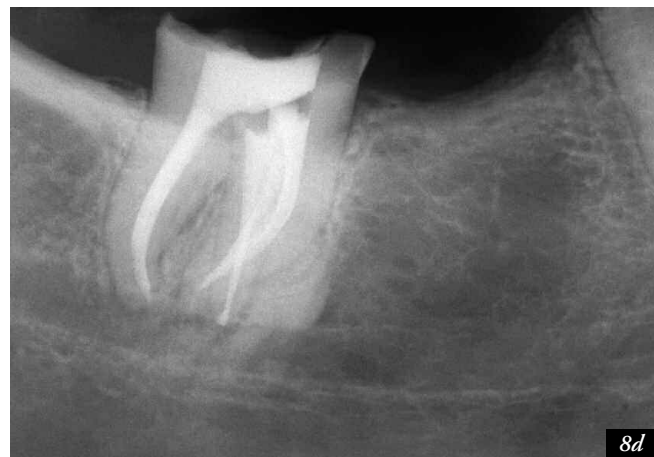
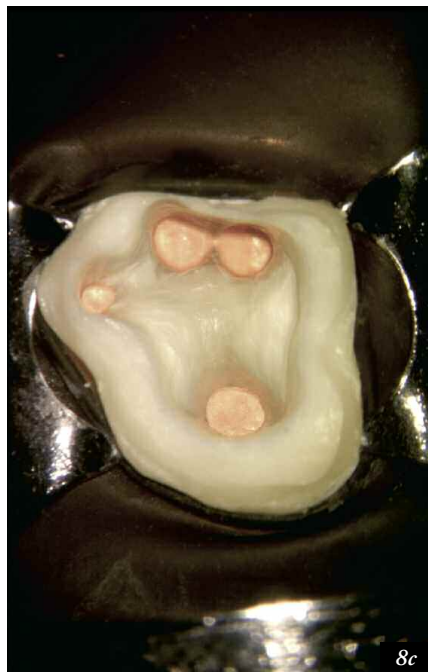

Figure 8c. The pulp floor is shown following three-dimensional cleaning, shaping, and obturation procedures. Note the displaced most lingual orifice.

Figure 8d. A mesially angulated post-operative radiograph confirms the disassembly efforts, demonstrates the pack and the displaced lingual system.

and intermittent air/water spray is directed on the post to reduce heat buildup and transfer during ultrasonic removal procedures. The majority of posts can be safely and successfully removed with ultrasonics in about 10 minutes.³²

PRS OPTION

The Post Removal System (PRS) is a reliable method to remove a post when ultrasonic efforts using the "10-Minute Rule" prove unsuccessful.¹⁸ In this removal method a trephine is used to machine down the most coronal aspect of the post 2-3 mm. The correspondingly sized tap is selected and an appropriately sized protective bumper is inserted onto this instrument. The tap is turned in a counterclockwise direction to form threads and securely engage the post head. Once the tap is firmly engaged on the post and the protective bumper seated, then the extracting pliers are used to safely and progressively elevate the post out of the canal.

SEPARATED INSTRUMENT REMOVAL

Technological advancements have significantly increased the predictability in removing separated instruments. These advancements include the dental operating microscope, ultrasonic instrumentation, and microtube delivery methods.¹⁸ The ability to access and remove a broken instrument will be influenced by the cross-sectional diameter, length and curvature of the canal, and further guided by root bulk and form including the depth of external concavities. In general, if one-third of the overall length of an obstruction can be exposed, it can usually be removed. Instruments that lie in the straightaway portions of the canal or partially around the curvature can usually be removed if safe access can be established to its most coronal extent.^{33,34} If the entire segment of the broken instrument is apical to the curvature of the canal and safe access cannot be accomplished, then removal is usually not possible.

The techniques required to remove a broken instrument begin with establishing straightline coronal access. To create radicular access, hand files may be used serially small to large, coronal to the obstruction, to create sufficient space to safely introduce gates glidden (GG) drills. GG's are used like "brushes" and at

a reduced speed of about 750 RPM. Importantly, in multi-rooted teeth, GG's may be used from small to big to cut and remove dentin on the outer wall of the canal and away from furcal danger. Each larger GG is stepped out of the canal to create a uniform tapered and smooth flowing funnel. The goal of radicular access is to optimally prepare a canal no larger than if there was no broken instrument.

ULTRASONIC OPTION

In combination, microscopes and ultrasonics have driven "microsonic" techniques that have improved the potential, predictability and safety when removing broken instruments.¹⁸ When access and visibility to the head of the broken instrument are achieved then contra-angled, parallel-walled and abrasively-coated ultrasonic instruments (ProUltra Endo Tips #3, 4, 5) may be employed. When energized, these instruments may be used to precisely sand away dentin and trephine circumferentially around the obstruction. During the ultrasonic procedure, the broken instrument will typically loosen, unwind and spin, then "jump out" of the canal (*Figure 9*).

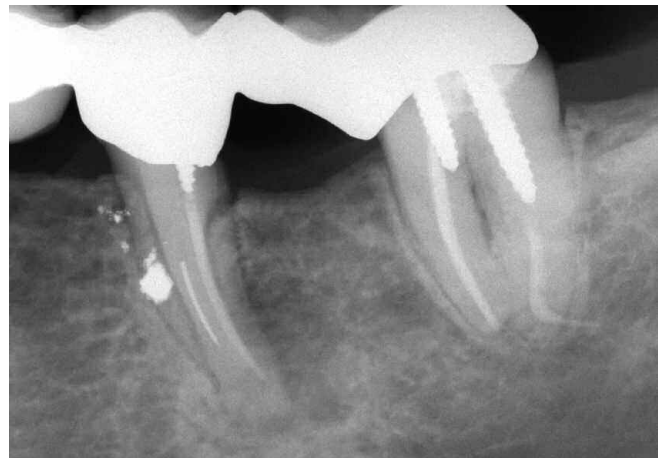

Figure 9a. A pre-operative radiograph shows a strategic and endodontically failing mesial root of a mandibular left first molar. Note a short screw post, a separated instrument and amalgam debris from the hemisection procedures.

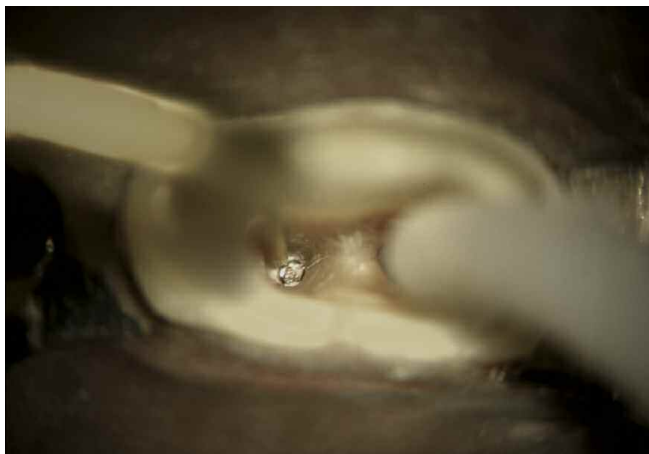

Figure 9b. A photograph shows the splint removed, the post out and an ultrasonic instrument trephining around the broken file.

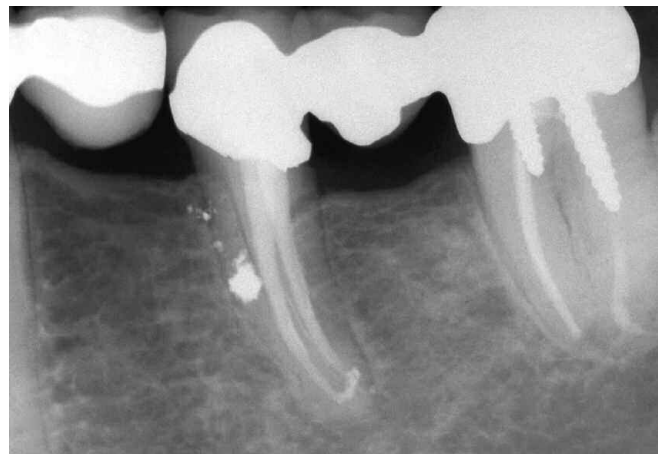


Figure 9c. An 8-year recall film demonstrates three-dimensional retreatment, a new bridge and excellent periradicular healing.

iRS OPTION

When ultrasonic techniques fail, the fall-back option is to use the Instrument Removal System (iRS) (*Dentsply Tulsa Dental*). The iRS is composed of variously sized microtubes and screw wedges. Each microtube has a small handle to enhance vision and its distal end is constructed with a 45° beveled end and side window. The appropriately sized microtube is inserted into the canal and, in the instance of canal curvature, the long part of its beveled end is oriented to the outer wall of the canal to “scoop-up” the head of the broken instrument and guide it into its lumen. The screw wedge is then placed through the open end of the microtube and passed down its internal lumen until it contacts the broken instrument. Rotating the screw wedge handle tightens, wedges, and oftentimes, displaces the head of the file through the microtube’s side window.¹⁸ With the broken instrument strongly engaged, it can generally be rotated counterclockwise and removed (*Figure 10*).

BLOCKS, LEDGES, TRANSPORTATIONS & PERFORATIONS

Failure to respect the biological and mechanical objectives for shaping canals and cleaning root canal systems predisposes to needless complications such as blocks, ledges, external transportations and perforations. These iatrogenic events can be attributable to working short, the sequence utilized for preparing the canal, and the instruments and their method of use.¹⁹

TECHNIQUES FOR MANAGING BLOCKS

Techniques for managing blocked canals begin by confirming straightline access and then pre-enlarging the canal coronal to the obstruction.¹⁸ A 10 file provides rigidity and is precurved to simulate the expected curvature of the canal

and the unidirectional rubber stop is oriented to match the file curvature. With the pulp chamber filled with a viscous chelator, efforts are directed towards gently sliding the 10 file to length. If unsuccessful, the file is used with an apically directed picking action while concomitantly re-orienting the unidirectional stop which serves to re-direct the apical aspect of the precurved file. *Short amplitude, light pecking strokes* are best utilized to ensure safety, carry reagent deeper, and increase the possibility of canal negotiation. If the apical extent of the file “sticks” or engages, then it may be useful to move to a smaller sized hand file. A working film should be taken and the file frequently removed to see if its curve is following the expected root canal morphology. Depending on the severity of the blockage, perseverance will oftentimes allow the clinician to safely reach the foramen and establish patency (*Figure 11*). If the blocked canal is not negotiable, then the case should be filled utilizing a hydraulic warm gutta percha technique. Regardless of the packing result, the patient needs to be advised of the importance of recall and that future treatment options include surgery, re-implantation, or extraction.

TECHNIQUES FOR MANAGING LEDGES

An *internal* transportation of the canal is termed a “ledge” and frequently results when clinicians work short of length and “get blocked”. Ledges are typically on the outer wall of the canal curvature and are oftentimes bypassed using the techniques described for blocks.^{13,18} Once the tip of the file is apical to the ledge, it is moved in and out of the canal utilizing ultra-short push-pull movements with emphasis on staying apical to the defect. When the file moves freely, it may be turned clockwise upon withdrawal to rasp, reduce, smooth or eliminate the ledge. During these procedures, try to keep the file coronal to the terminus of the canal so the apical foramen (foramina) is handled delicately and kept as small as practical. When the

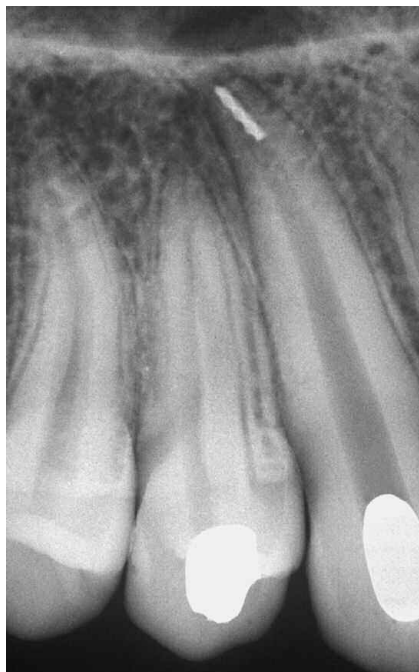

Figure 10a. A pre-operative radiograph of a maxillary canine demonstrates a temporized canal with an instrument broken deep in the apical one-third.

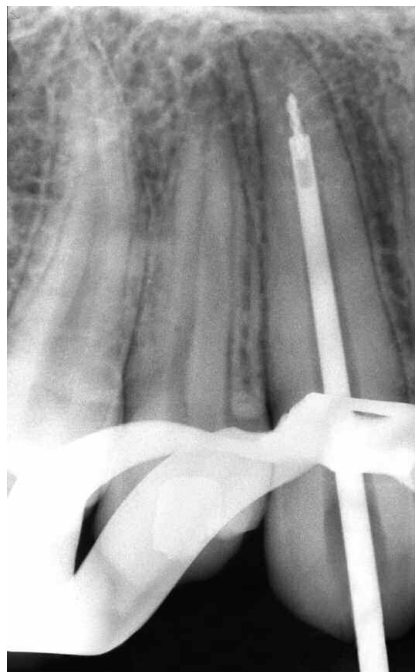


Figure 10b. A working film shows that the 21 gauge iRS has successfully engaged and partially elevated the deeply positioned file segment.

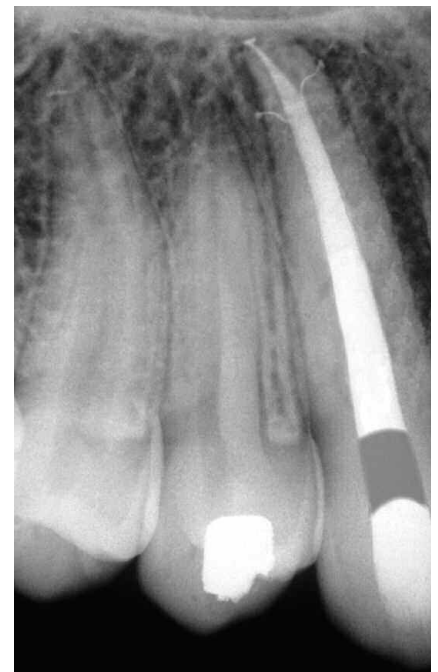

Figure 10c. A post-operative film demonstrates the retreatment steps and a densely packed system that exhibits three apical portals of exit.

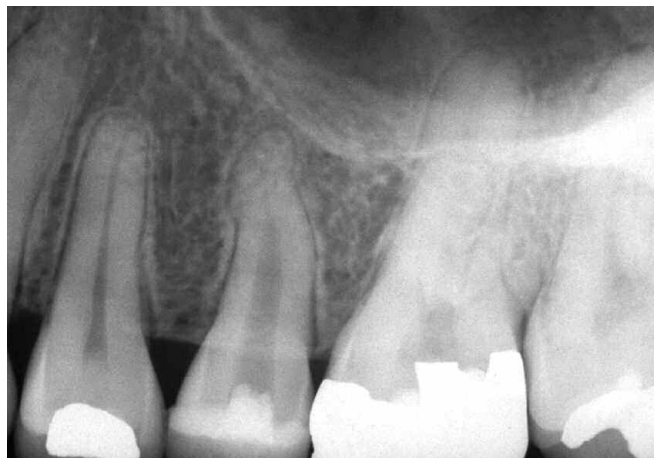

Figure 11a. A pre-operative radiograph of a maxillary left second bicuspid reveals previous access and pre-enlargement of the canal in its coronal two-thirds.

ledge can be predictably bypassed, then efforts are directed towards establishing patency with a 10 file. Gently passing a .02 tapered 10 file 1 mm through the foramen insures its diameter is at least 0.12 mm and paves the way for the 15 file.²²

A significant improvement in ledge management is the utilization of nickel-titanium (NiTi) hand files that exhibit tapers greater than ISO files.¹⁸ Certain NiTi instruments have multiple increasing tapers over the length of the cutting blades on the same instrument (*ProTaper, Dentsply Tulsa Dental*). Progressively tapered NiTi files can be introduced into the canal when the ledge has been bypassed, the canal negotiated and patency established. Bypassing the ledge and negotiating the canal up to a size 15, and if necessary a 20, file creates a pilot hole so the tip of the selected NiTi instrument can passively follow this glide path. To move the apical extent of a NiTi hand file past a ledge, the instrument must first be precurved with a device such as Bird Beak orthodontic pliers (*Hu-Friedy*). Ultimately, the clinician must make a decision based on pre-operative radiographs, root bulk and experience whether the ledge can be eliminated through instrumentation or if these procedures will weaken

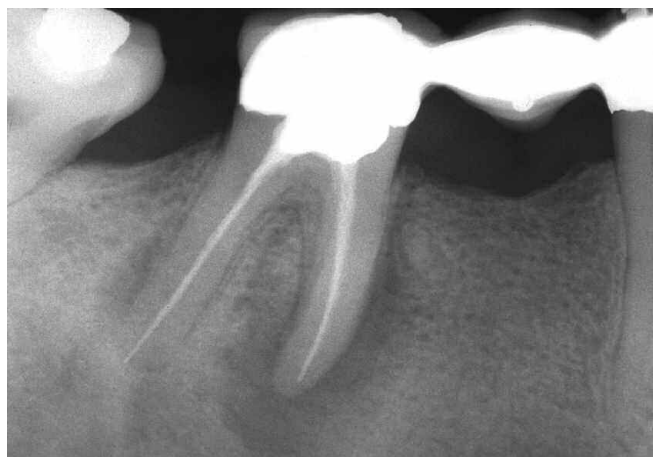

Figure 12a. A pre-operative radiograph shows an endodontically failing posterior bridge abutment. Note the amalgam in the pulp chamber and that the mesial root appears to have been ledged.

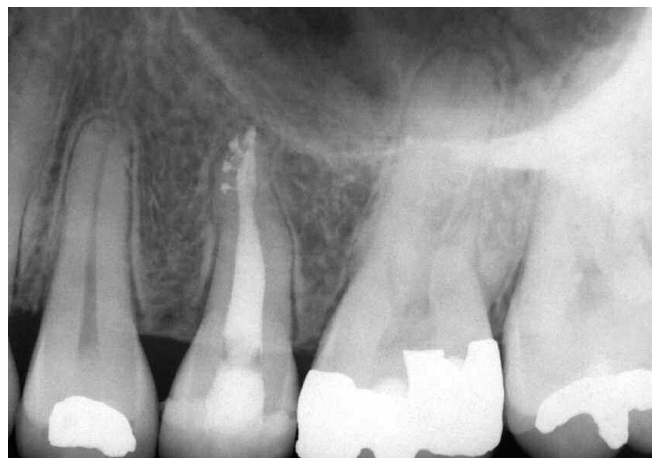

Figure 11b. The post-operative radiograph provides an explanation as to the etiology of the original block. Note the canal bifurcates apically and this system has four portals of exit.

or perforate the root. Not all ledges can or should be removed. Clinicians must weigh risk versus benefit and make every effort to maximize remaining dentin (**Figure 12**).

TECHNIQUES FOR MANAGING APICAL TRANSPORTATIONS

A canal that has been transported exhibits reverse apical architecture and predisposes to poorly packed canals that are oftentimes vertically overextended but internally underfilled.^{8,13} In these instances, a barrier/restorative can be selected to control bleeding and provide a backstop to pack against during subsequent obturation procedures. The barrier of choice for a transportation is generally mineral trioxide aggregate (MTA) (*Dentsply Tulsa Dental*), commercially known as ProRoot. MTA is an extraordinary material which can be used in canals which exhibit reverse apical architecture, such as in transportations or immature roots, nonsurgical perforation repairs, or in surgical repairs.^{18,35,36} Remarkably, cementum grows over this nonresorbable and radiopaque material, thus allowing for a normal periodontal attachment apparatus.³⁷⁻³⁹ Although a dry field facilitates visual control, MTA is apparently not compromised by moisture and typically sets brick-hard within 4-6 hours, creating a seal as good as or better than other materials.⁴⁰⁻⁴²

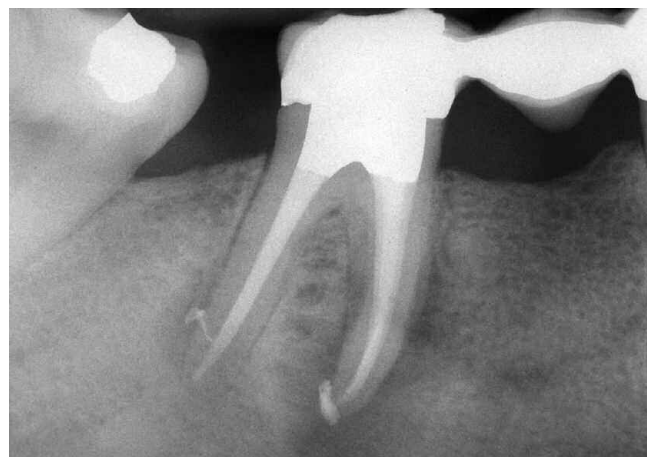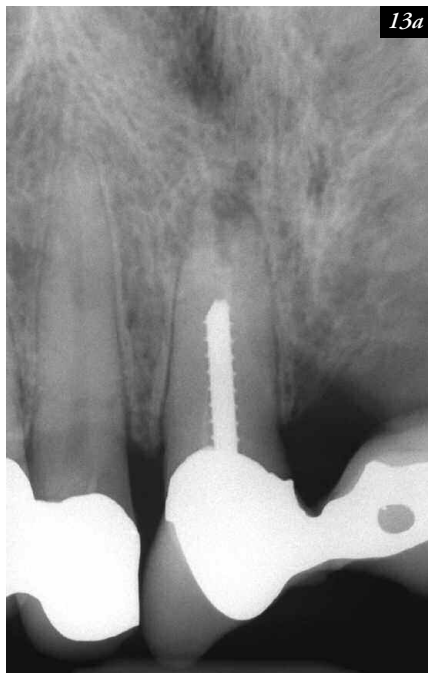


Figure 12b. A post-treatment film demonstrates ledge management with the obturation materials following the root curvature.

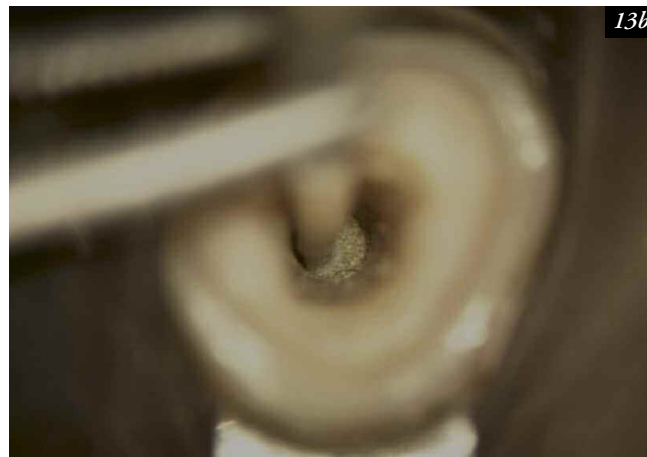
Techniques for managing apical transportations are facilitated when the coronal two-thirds of the canal is optimally prepared and radicular access is available for placing a barrier. ProRoot is easy to use and the powder is mixed with anesthetic solution or sterile water to a heavy cake-like consistency. MTA may be picked up and efficiently carried into more superficial regions of the tooth on the side of a West Perf Repair Instrument (*SybronEndo*). To more precisely introduce MTA deep into a prepared canal micro-tube carrying devices or the Lee carrier method (*G. Hartzell & Sons*) are appropriately sized to accomplish this task.^{18,35,43} ProRoot is then gently tamped down the canal to approximate length using a customized nonstandard gutta percha cone as a flexible plugger. In straighter canals, ProRoot can be gently vibrated, moved into the defect and adapted to the canal walls with ultrasonic instruments (*ProUltra Endo Tips, Dentsply Tulsa Dental*) Direct ultrasonic energy will vibrate and generate a wave-like motion which facilitates moving and adapting the cement into the apical extent of the canal. Prior to initiating subsequent procedures, a dense 4-5 mm zone of ProRoot in the apical one-third of the canal should be confirmed radiographically (*Figure 13*).

In the instance of repairing a defect apical to the canal curvature, ProRoot is incrementally placed deep into a canal then shepherded around the curvature with a flexible, trimmed gutta percha cone utilized as a plugger. A precurved 15 or 20 stainless steel file is then inserted into the ProRoot and to within 1-2 mm of the working length. Indirect ultrasonics involves placing the working end of an ultrasonic instrument, such as the ProUltra Endo Tip #1, on the shaft of the file. This vibratory energy will encourage ProRoot to move and conform to the configurations of the canal laterally as well as control its movement to and gently against the periapical tissues. Again, the clinician should radiographically confirm that there is a dense 4-5 mm zone of ProRoot in the apical extent of the canal.

MTA needs moisture to drive the cement to set and become hard. Fluids are present external to the canal and will fulfill the moisture requirement for the apical aspect of the positioned MTA. However, a cotton pellet or paper point will need to be sized, moistened with water, and placed against the coronal most aspect of the MTA that is within the canal. The tooth is then temporized and the patient dismissed. At a subsequent appointment, the temporary filling and wet cotton pellet are removed so the MTA can be



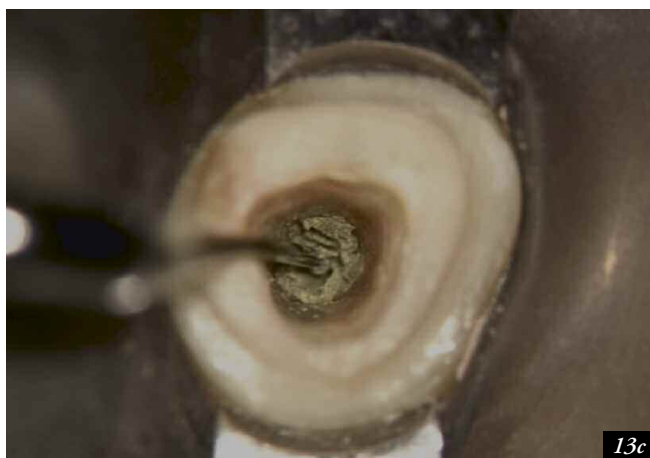
13a



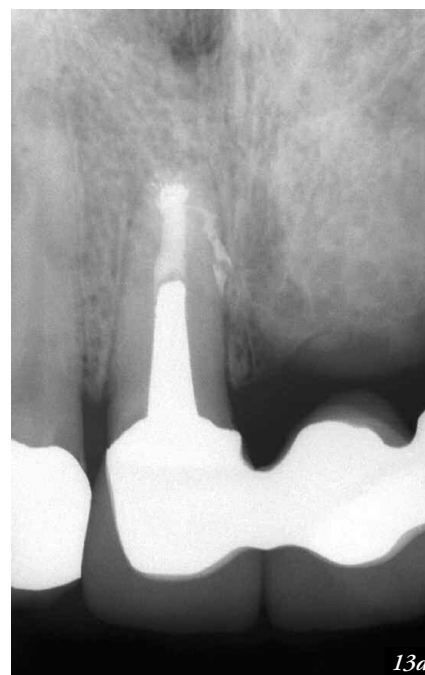13b

Figure 13a. A pre-operative film of the maxillary right central incisor bridge abutment depicts a post and an empty system that exhibits reverse apical architecture.

Figure 13b. A photograph shows tamping MTA into the apical one-third with a gutta percha cone used as a flexible plugger.



13c



13d

Figure 13c. A photograph shows the ProUltra ENDO-5 ultrasonic instrument vibrating MTA densely into the apical one-third.

Figure 13d. A 6-year recall demonstrates a new bridge, post, the nonsurgical efforts, and excellent osseous repair.

probed with an explorer to determine if it has set-up and is hard. Typically, the material is hard and the clinician can then obturate against this nonresorbable barrier. If the material is soft, it should be removed, the area flushed, dried, and a new mix of MTA placed. On a subsequent visit, when the inflammatory process has subsided, then a hard barrier should exist which will provide a backstop to pack against.

TECHNIQUES FOR MANAGING PERFORATIONS

A perforation represents a pathologic or iatrogenic communication between the root canal space and the attachment apparatus. The causes of perforations are resorptive defects, caries, or iatrogenic events that occur during and after endodontic treatment. Regardless of etiology, a perforation is an invasion into the supporting structures that initially incites inflammation and loss of attachment and ultimately may compromise the prognosis of the tooth. When managing these defects the prognosis will be impacted by the level,

location and size of the perforation, and further influenced by its timely repair.¹⁸

Techniques and materials for managing perforation defects have been previously described in *"Techniques for Managing Transportations"* within this article. However, on occasion, tooth-colored restoratives may be the material of choice for repairing certain perforations. Tooth-colored restoratives, such as a dual cured composite, require the placement of a barrier so the material is not contaminated during use. A barrier serves as a "hemostatic" and a "backstop" so a restorative material can be placed into a clean, dry preparation with control. Calcium sulfate is an excellent resorbable barrier material when using the principles of wet bonding because it is biocompatible, osteogenic, and following placement, sets brick-hard.^{44,46} When set, calcium sulfate is internally trimmed back to the cavo surface of the root. A dual cured, tooth-colored restorative can now be placed against the barrier and utilized to seal a root defect (*Figure 14*).

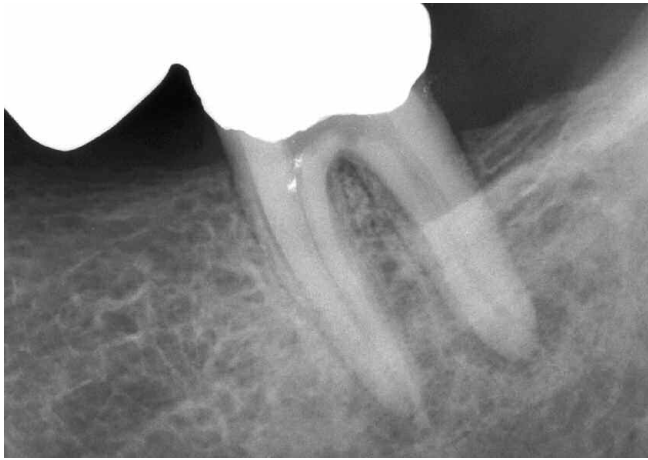


Figure 14a. A pre-operative radiograph of an endodontically involved mandibular left second molar bridge abutment. Note the previous access and possible floor perforation.

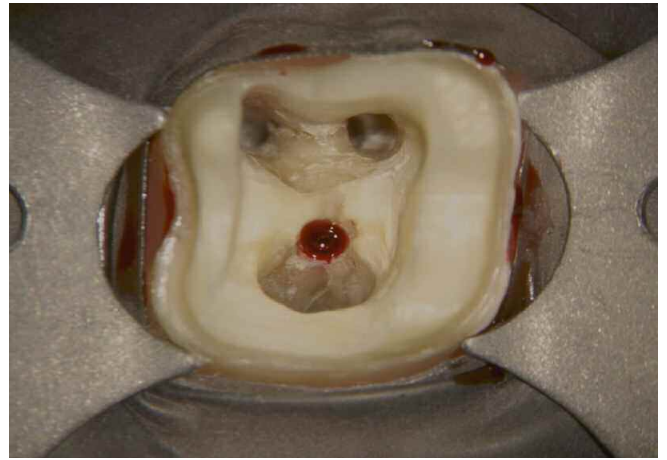

Figure 14b. A photograph demonstrates the identified orifices and a frank furcal floor perforation.

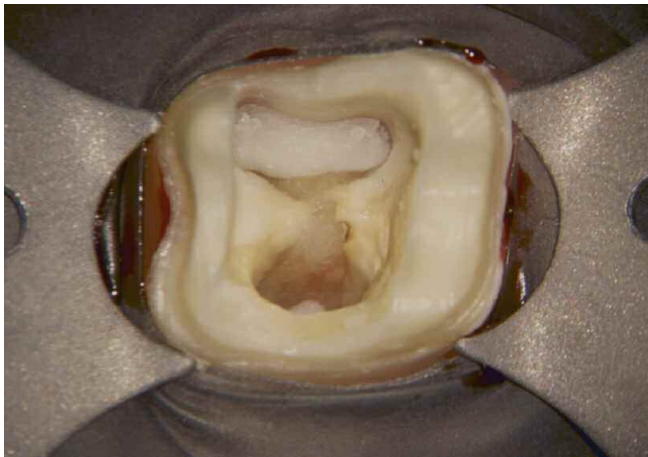


Figure 14c. This photograph shows the perforation repair utilizing a calcium sulfate resorbable barrier and a dual cured composite restorative.

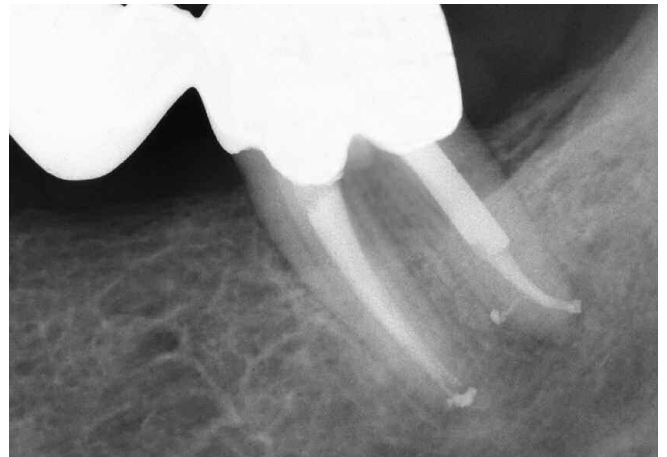

Figure 14d. A 5-year recall film shows a new bridge and osseous repair furcally and apically.

CONCLUSION

This article has identified a variety of techniques to successfully retreat endodontically failing teeth. It should be recognized certain endodontically failing teeth are not amenable to successful retreatment. In these instances, the various interdisciplinary treatment options can be thoughtfully considered to ensure each patient is best served. However, as the potential for health associated with endodontically treated teeth becomes fully appreciated, the naturally retained root will be recognized as the ultimate dental implant.

SUMMARY

In the United States alone, tens of millions of teeth receive endodontic treatment annually. Regardless of the enormous potential for endodontic success, certain teeth exhibit post-treatment disease. Many endodontically failing teeth are either surgerized or extracted. This article has emphasized the importance of case selection, interdisciplinary treatment planning and the role of nonsurgical endodontic retreatment in preserving strategic teeth. Properly performed, endodontic treatment is the cornerstone of restorative and reconstructive dentistry. ▲

REFERENCES

1. Endodontic trends reflect changes in care provided, *Dental Products Report*, 30:12, pp. 94-98, 1996.
2. Scianamblo MJ: Endodontic failures: the retreatment of previously endodontically treated teeth, *Revue D'Odonto Stomatologie* 17:5, pp. 409-423, 1988.
3. Hess W, Zürcher E: *The Anatomy of the Root Canals of the Teeth of the Permanent and Deciduous Dentitions*, William Wood & Co, New York, 1925.
4. Ruddle CJ: Endodontic failures: the rationale and application of surgical retreatment, *Revue D'Odonto Stomatologie* 17:6, pp. 511-569, 1988.
5. Schilder H: Cleaning and shaping the root canal system, *Dent Clin North Am*, 18:2, pp.269-296, 1974.
6. Barkhordar RA, Stewart GG: The potential of periodontal pocket formation associated with untreated accessory root canals, *Oral Surg Oral Med Oral Pathol* 70:6, 1990.
7. DeDeus QD: Frequency, location and direction of the accessory canals, *J Endod* 1:361-366, 1975.
8. Schilder H: Filling root canals in three dimensions, *Dent Clin North Am*, pp. 723-744, November 1967.
9. West JD: The relation between the three-dimensional endodontic seal and endodontic failure, *Master Thesis*, Boston University, 1975
10. Torabinejad M, Ung B, Kettering JD: In vitro bacterial penetration of coronally unsealed endodontically treated teeth. *J Endod* 16:12, pp. 566-569, 1990.
11. Alves J, Walton R, Drake D: Coronal leakage: endotoxin penetration from mixed bacterial communities through obturated, post-prepared root canals, *J Endod* 24:9, pp.587-591, 1998.
12. Southard DW: Immediate core buildup of endodontically treated teeth: the rest of the seal, *Pract Periodont Aesthet Dent* 11:4, pp. 519-526, 1999.
13. Ruddle CJ: Nonsurgical endodontic retreatment, *J Calif Dent Assoc* 25:11, pp. 765-800, 1997.
14. Ruddle CJ: Surgical endodontic retreatment, *J Calif Dent Assoc* 19:5, pp. 61-67, 1991.
15. Stabholz A, Friedman S: Endodontic retreatment- case selection and technique. Part 2: treatment planning for retreatment. *J Endod* 14:12, pp. 607-614, 1988.
16. Allen RK, Newton CW, Brown CE: A statistical analysis of surgical and non-surgical endodontic retreatment cases, *J Endod* 15:6, pp. 261-266, 1989.
17. Kvist T, Reit C: Results of endodontic retreatment: a randomized clinical study comparing surgical and nonsurgical procedures, *J Endod* 25:12, pp. 814-817, 1999.
18. Ruddle CJ: Ch. 25, Nonsurgical endodontic retreatment. In Cohen S, Burns RC, editors: *Pathways of the Pulp*, pp. 875-929, 8th ed., Mosby, St. Louis, 2002.

19. Ruddle CJ: Ch. 8, Cleaning and shaping root canal systems. In Cohen S, Burns RC, editors: *Pathways of the Pulp*, pp. 231-291, 8th ed., Mosby, St. Louis, 2002.
20. Ruddle CJ: Ch. 9, Three-dimensional obturation: the rationale and application of warm gutta percha with vertical condensation, *Pathways of the Pulp*, pp. 243-247, 6th ed., Mosby Co., St. Louis, 1994.
21. Blum JY, Machtou P, Ruddle CJ, Micallef JP: The analysis of mechanical preparations in extracted teeth using protaper rotary instruments: value of the safety quotient, *J Endod* 29:9, pp. 567-575, 2003.
22. Ruddle CJ: Nickel-titanium rotary instruments: current concepts for preparing the root canal system, *Australian Endodontic Journal* 29:2, pp. 87-98, 2003.
23. Ruddle CJ: Microendodontic nonsurgical retreatment, in *Microscopes in Endodontics*, *Dent Clin North Am* 41:3, pp. 429-454, W.B. Saunders, Philadelphia, July 1997.
24. Machtou P: Ch. 8, La cavité d'accès. In Machtou P, editor: *Endodontie - guide clinique*, pp. 125-137, Editions CdP, Paris, 1993.
25. Wilcox LR, Krell KV, Madison S, Rittman B: Endodontic retreatment: evaluation of gutta-percha and sealer removal and canal reinstrumentation, *J Endod* 13:9, pp. 453-457, 1987.
26. Goon WWY: Managing the obstructed root canal space: rationale and techniques, *J Calif Dent Assoc* 19:5, pp. 51-60, 1991.
27. Glick DH, Frank AL: Removal of silver points and fractured posts by ultrasonics, *J Prosth Dent* 55:212-215, 1986.
28. Bertrand MF, Pellegrino JC, Rocca JP, Klinghofer A, Bolla M: Removal of Thermafil root canal filling material, *J Endod* 23:1, pp. 54-57, 1997.
29. Cohen AG: The efficiency of solvents used in the retreatment of paste-filled root canals, *Masters Thesis*, Boston University, 1986.
30. Machtou P, Sarfati P, Cohen AG: Post removal prior to retreatment, *J Endod* 15:11, pp. 552-554, 1989.
31. Stamos DE, Gutmann JL: Survey of endodontic retreatment methods used to remove intraradicular posts, *J Endod* 19:7, pp. 366-369, 1993.
32. Altshul JH, Marshall G, Morgan LA, Baumgartner JC: Comparison of dentinal crack incidence and of post removal time resulting from post removal by ultrasonic or mechanical force. *J Endod* 23:11, pp. 683-686, 1997.
33. Ward JR, Parashos P, Messer HH: Evaluation of an ultrasonic technique to remove fractured rotary nickel-titanium endodontic instruments from root canals: an experimental study, *J Endod* 29:11, pp. 756-763, 2003.
34. Ward JR, Parashos P, Messer HH: Evaluation of an ultrasonic technique to remove fractured rotary nickel-titanium endodontic instruments from root canals: clinical cases, *J Endod* 29:11, pp. 764-767, 2003.
35. Castellucci A: L'uso del mineral trioxide aggregate in endodonzia clinica e chirurgica, *L'informatore Endodontico* 6:3, pp. 34-45, 2003.
36. Torabinejad M, Chivian N: Clinical applications of mineral trioxide aggregate, *J Endod* 25:197-205, 1999.
37. Torabinejad M, Pitt Ford TR, Abedi HR, Kariyawasam SP, Tang HM: Tissue reaction to implanted potential root-end filling materials in the tibia and mandible of guinea pigs, *J Endod* 24:468-71, 1998.
38. Torabinejad M, Hong CU, Lee SJ, Monsef M, Pitt Ford TR: Investigation of mineral trioxide aggregate for root end filling in dogs, *J Endod* 21:603-8, 1995.
39. Torabinejad M, Pitt Ford TR, McKendry DJ, Abedi HR, Miller DA, Kariyawasam SP: Histologic assessment of MTA as root end filling in monkeys, *J Endod* 23:225-8, 1997.
40. Torabinejad M, Watson TF, Pitt Ford TR: The sealing ability of a mineral trioxide aggregate as a retrograde root filling material, *J Endod* 19:591-5, 1993.
41. Torabinejad M, Higa RK, McKendry DJ, Pitt Ford TR: Dye leakage of four root-end filling materials: effects of blood contamination, *J Endod* 20:159-63, 1994.
42. Torabinejad M, Rastegar AF, Kettering JD, Pitt Ford TR: Bacterial leakage of mineral trioxide aggregate as a root end filling material, *J Endod* 21:109-21, 1995.
43. Lee SL: A new mineral trioxide aggregate root-end filling technique, *J Endod* 26:12, pp. 764-765, 2000.
44. Sottosanti J: Calcium sulfate: a biodegradable and bio-compatible barrier for guided tissue regeneration, *Compend Contin Educ Dent* 13:3, pp. 226-234, 1992.
45. Himel VT, Alhadainy HA: Effect of dentin preparation and acid etching on the sealing ability of glass ionomer and composite resin when used to repair furcation perforations over plaster of Paris barriers, *J Endod* 21:3, pp. 142-145, 1995.
46. Alhadainy HA, Abdalla AI: Artificial floor technique used for the repair of furcation perforations: a microleakage study, *J Endod* 24:1, pp. 33-35, 1998.